

INNOVATION

# First human use of a wireless coplanar energy transfer coupled with a continuous-flow left ventricular assist device



Yuryi Pya, MD,<sup>a</sup> Jiri Maly, MD, PhD,<sup>b</sup> Mahabbat Bekbossynova, MD,<sup>a</sup>  
Roman Salov, MBA,<sup>a</sup> Stephan Schueler, MD, PhD, FRCS,<sup>c</sup>  
Bart Meyns, MD, PhD,<sup>d</sup> Yigal Kassif, MD,<sup>e</sup> Massimo Massetti, MD, PhD,<sup>f</sup>  
Michael Zilbershlag, BSc,<sup>g</sup> and Ivan Netuka, MD, PhD<sup>b</sup>

From the <sup>a</sup>National Research Cardiac Surgery Center, Astana, Kazakhstan; <sup>b</sup>Department of Cardiovascular Surgery, Institute for Clinical and Experimental Medicine, Prague, Czech Republic; <sup>c</sup>Department of Cardiovascular Surgery, Freeman Hospital, The Newcastle upon Tyne Hospitals NHS Foundation Trust, Newcastle, UK; <sup>d</sup>Cardiac Surgery Department, The University Hospitals Leuven, Leuven, Belgium; <sup>e</sup>Cardiac Surgery Department, Sheba Medical Center, Tel Aviv, Israel; <sup>f</sup>Cardio Vascular Department, Catholic University of the Sacred Heart Rome, Policlinico A. Gemelli Foundation, Rome, Italy; and the <sup>g</sup>LeviticusCardio, Ltd., Petach Tikva, Israel.

## KEY WORDS:

ventricular assist device;  
drive-line, wireless;  
coplanar energy transfer;  
fully implantable

The drive-line to power contemporary ventricular assist devices exiting the skin is associated with infection, and requires a holstered performance of the cardiac pump, which reduces overall quality of life. Attempts to eliminate the drive-line using transcutaneous energy transfer systems have been explored but have not succeeded in viable widespread application. The unique engineering of the coplanar energy transfer system is characterized by 2 large rings utilizing a coil-within-the-coil topology, ensuring robust resonance energy transfer while allowing for a substantial (>6 hours) unholstered circulatory support powered by an implantable battery source. Herein we report the first known human experience with this novel technology, coupled with a continuous-flow assist left ventricular assist device, in 2 consecutive patients evaluated with the primary end-point of system performance at 30 days post-implantation.

J Heart Lung Transplant 2019;38:339–343

© 2019 The Author(s). Published by Elsevier Inc. on behalf of International Society for Heart and Lung Transplantation. This is an open access article under the CC BY-NC-ND license.

(<http://creativecommons.org/licenses/by-nc-nd/4.0/>)

Hemocompatibility-related adverse events with continuous-flow left ventricular assist devices (CF-LVADs) have been reduced with newly engineered pumps,<sup>1,2</sup> but rates of infection remain high. Global registry data (IMACS)

suggest freedom from infection in only half of the patients at 2 years.<sup>3</sup> Principally, a drive-line infection is reported in one fifth of patients by 2 years, representing substantial morbidity, mortality, readmissions, and cost of care.<sup>4–7</sup> The need for a permanent holstered mode of operation with the drive-line components connected to an external controller and batteries represents a substantial limitation to mobility and quality of life.

Attempts to eliminate the drive-line using transcutaneous energy transfer systems (TETS) have been explored in

Reprint requests: Ivan Netuka, MD, PhD, Department of Cardiovascular Surgery, Institute for Clinical and Experimental Medicine, Vídeňská 1958/9, Prague 4, Czech Republic. Telephone: +420261365015.

Fax: +420261365015.

E-mail address: [ivan.netuka@ikem.cz](mailto:ivan.netuka@ikem.cz)

pulsatile LVADs<sup>8</sup> and the total artificial heart.<sup>9</sup> The need for close alignment of coils in TETS led to a loss of efficiency with unholstered operation of the device capable for less than 30 minutes. Efforts to investigate alternative technological solutions to develop a wireless device operation are challenging. Several *in vitro* and animal studies have suggested possible solutions,<sup>10</sup> including use of a coplanar energy transfer (CET) system. Unlike TETS, the unique architecture of the CET system is characterized by 2 large rings utilizing coil-within-the-coil topology, ensuring high and robust resonance energy powering. Moreover, an integrated internal battery can provide >6 hours of full-freedom wireless LVAD operation.

To the best of our knowledge, our report is the first-in-human experience with a wireless energy transfer technology using a CET coupled with a CF-LVAD.

## Methods

Two patients (51 and 24 years old), with advanced-stage heart failure, refractory to medical therapy and dependent on inotropic support, were considered candidates for LVAD implantation with a bridge-to-transplant designation (Table 1). Neither patient was willing to accept implantation with a conventional LVAD due to mobility concerns. Because ambulatory freedom from refractory symptoms was important to the patients and waiting times for heart transplant were predicted to be long due to donor scarcity within national health-care program, the patients were offered the alternative of a wireless LVAD implantation based on an expanded access protocol regulation. All legal requirements were fulfilled and ethics review board approval as well as fully informed patient consent were obtained before the procedures. A primary end-point for success was defined as 30-day survival free of wireless energy transfer device malfunction necessitating a bail-out pump supply with an alternative power source.

## Investigational device

A proprietary CET system (LeviticusCardio, Ltd., Petach Tikva, Israel) designed for wireless control and powering of LVADs has

been validated in multiple long-term animal experiments (over 6 months). The CET system replaces the original LVAD controller, battery, and monitor and eliminates the need for a drive-line connection. The system consists of an internal integrated controller and battery coupled with an internal thoracic coil ring designed for energy harvesting. External equipment includes a power transmission belt coupled with an external controller, battery, and wristwatch monitor (Figure 1).

Although in unholstered mode, the patient, pump, and CET operation are monitored by the proprietary wristwatch, which provides alerts to any device malfunction. A second-line ancillary internal vibration alarm embedded within the controller is triggered during a major hazard, such as low internal battery power (Figure 2).

To maximize safety in this early clinical experience, the system was pragmatically integrated with the Jarvik 2000 LVAS (Jarvik Heart, Inc., New York, NY). This pump is implanted with a retroauricular pedestal that connects to an external power source, which would be used as a back-up in case of component failure of the CET system (Figure 1). Automated data collection, reporting, and configuration systems utilize the standard MedRadio 402–405-MHz communication protocol, which is also coupled with the wristwatch.

## Implantation procedure

After exposing the heart via a median sternotomy, the internal drive-line of the retroauricular pedestal power connector was tunneled and affixed to the skull.<sup>11</sup> After heparinization, and once the lung is deflated, an appropriate internal thoracic cavity coil size is ascertained by sizers and the coil is positioned horizontally around the circumference of the lower portion of a pleural cavity (Figure 1A). To ensure its stability, straps of the coil are attached to adjacent structures at anatomically amenable locations. Sequentially, a pocket for the integrated controller-battery is created between the musculus serratus and musculus latissimus dorsi along the lateral thoracic wall similar to the technique used in subcutaneous defibrillator placement. While on cardiopulmonary bypass (CPB), the pump is implanted in regular fashion and a parallel V-shaped drive-line from the pump as well as internal coil drive-line are tunneled through an intercostal space to the controller. Once both connectors are secured, the pump is started using a wireless operation and surgery completed after CPB wean.

## Results

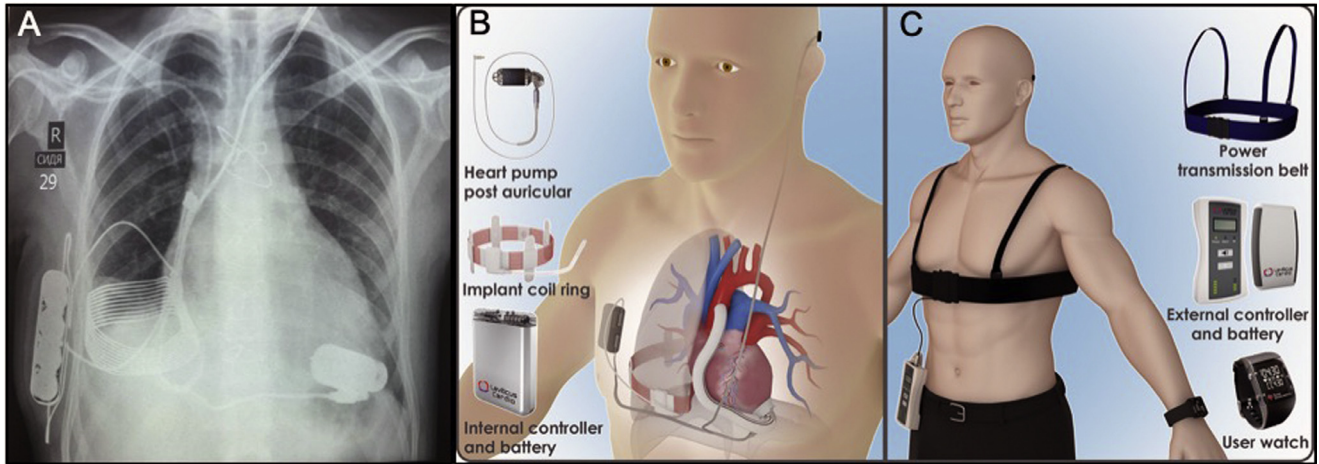
### Patient outcomes

Surgical implants were uneventful and a fully wireless LVAD operation was initiated successfully followed by primary chest closure. One patient (Patient A) had a peri-operative ischemic stroke (modified Rankin Scale [mRS] score >3) and a neurologic condition necessitated prolonged ventilatory support with tracheostomy. At 30 days, the patient was discharged to step-down to undergo intensive rehabilitation due to a residual left lower extremity motor compromise.

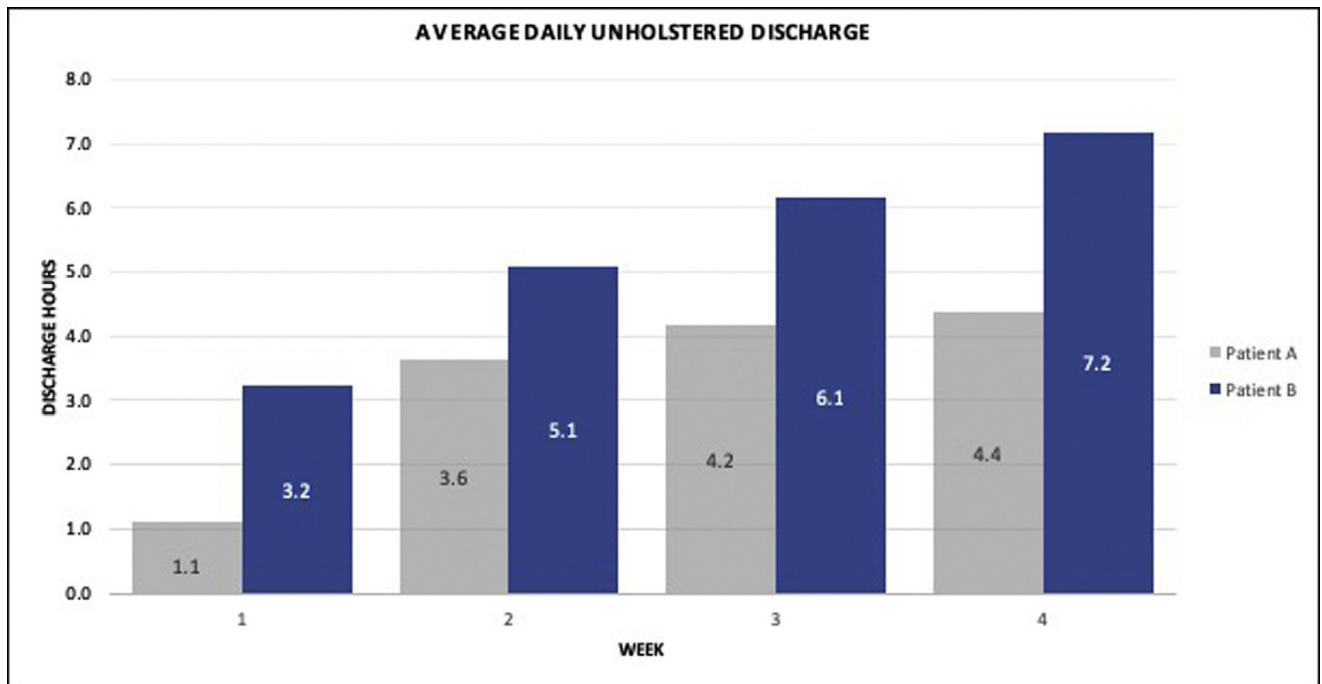
Further along the clinical course, contrast computerized tomography confirmed pump thrombosis with subtotal obstruction of the outflow graft, while the CET system data analysis corroborated consistent pump rotor speed and a wireless energy transfer ensured efficient supply despite

**Table 1** Baseline Characteristics

	Patient A	Patient B
Age (years)	51	24
Gender	Male	Male
Ethnicity	Caucasian	Kazakh
BSA (m <sup>2</sup> )	2.02	1.89
Etiology of cardiomyopathy	Ischemic	Non-ischemic
LV EF (%)	11	22
LVEDd (mm)	93	71
CI (l/min/m <sup>2</sup> )	1.9	2.2
PCWP (mmHg)	24	20
PAPs (mmHg)	33	40
PAPm (mmHg)	20	30
CVP (mm Hg)	6	5
GFR - MDRD (ml/min per 1.73 m <sup>2</sup> )	67	116
NYHA Class	IV	IV
INTERMACS Profile	3	3
Intended goal of support	BTT	BTT



**Figure 1** (A) Chest X-ray depicting implantable components topography. (B) Implantable components. (C) External components.



**Figure 2** Daily maximum continuous unholstered discharge intervals depicted as daily mean per week of support (individual bar graphs of both patients).

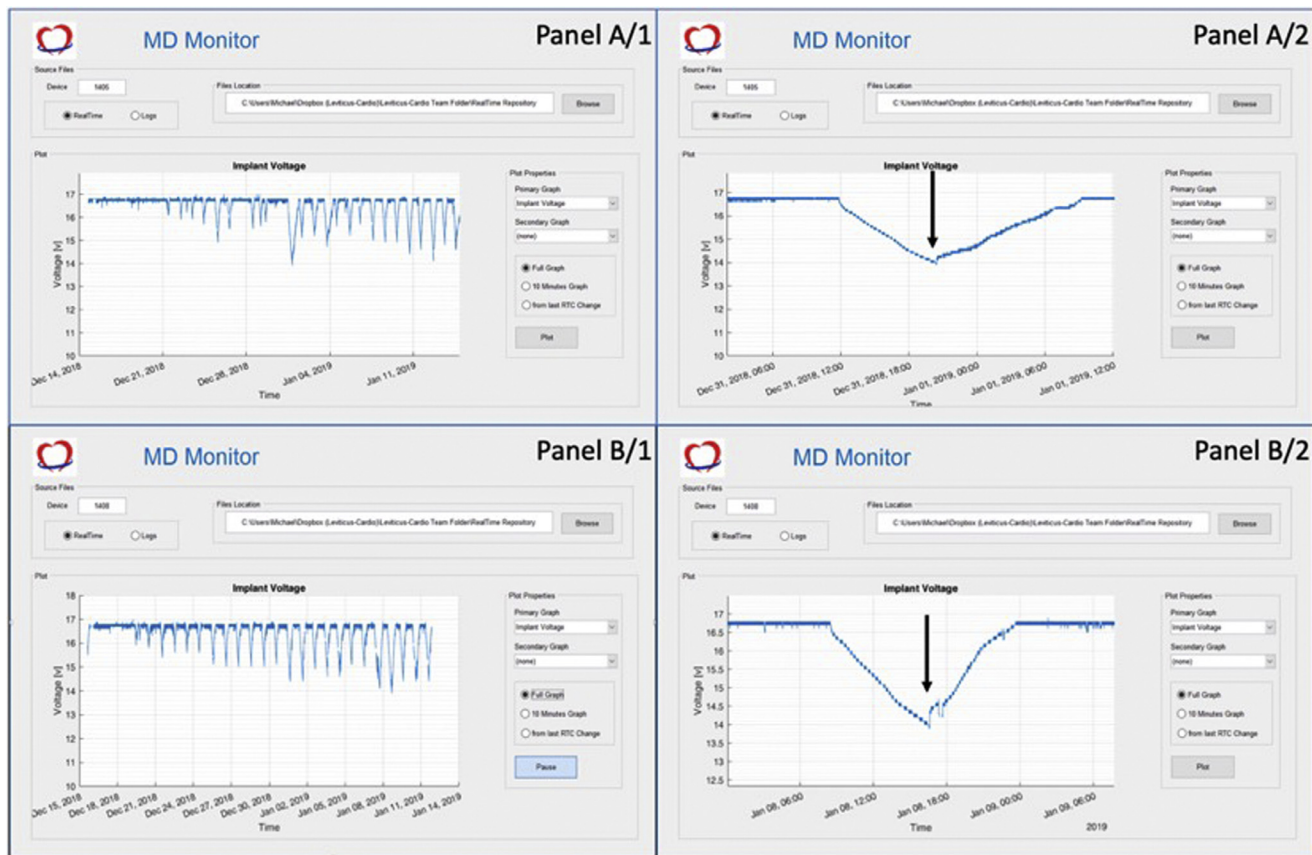increased power consumption requirements. On Day 35 post-operatively, given the complex clinical scenario, a multidisciplinary team decided to terminate pump operation, with consequent retirement of need for the CET system and inotropic support was resumed. At this writing, the patient is in a stable condition on inotropes with satisfactory end-organ function while listed for heart transplant in high-urgency status. (Patient A’s detailed narrative is presented in the Supplementary Material available online at [www.jhltonline.org/](http://www.jhltonline.org/)).

The second patient had an uneventful post-operative course and reached full ambulation within the first week of surgery. No major adverse events were encountered and the patient was discharged from the hospital at 30 days

post-implantation. (Exercise and lifestyle activities are presented in [Video S1](#) in the [Supplementary Material](#) online.)

### System performance

In the early post-operative phase, CET system operation was accomplished as expected in both patients. The system powered the pump and kept the battery charged to allow for medical and nursing procedures. CET energy transfer efficiency further improved after removing intensive care equipment and drains, enabling optimal sizing of the external belt and enhancing coil alignment (see [Figure S1](#) in the [Supplementary Material](#) online).



**Figure 3** Discharge unholstered performance: (A/1) Patient A and (B/1) Patient B showing daily discharge intervals as a decrease in voltage curve. Maximum discharge test: (A/2) Patient A and (B/2) Patient B showing 8.5 hours until the alarm triggered followed by full battery recharging requiring approximately 6.5 hours. Arrow indicates start of recharge.

Subsequently, a stepwise protocol-based extended daily “discharge-simulation” cycles were conducted (Figure 2 and (Figure 3 Panels A/1, B/1)). Maximum time on unholstered support (Figure 3A/2 and B/2) was attained for 8.5 hours until the first alarm triggered an internal controller vibration and watch buzzer. Such a battery level ensures at least 1 hour of pump operation before a low-capacity, high-alert alarm ensues. Both alarms were actionable as appropriately recognized by both patients and allowed for return to charging safely.

## Discussion

In this study we have described 2 cases of a CET technology that ameliorates infection risk by drive-line elimination while providing successful energy transmission and allowing for substantial (8.5 hours) unholstered support while on the LVAD. The unique system architecture meets maximum allowable temperature deviation of implanted components, as consistently validated in long-term animal studies. Using this power configuration, we project that the controller exchange would require replacement in 3 years, permitting an appropriate first-use cycle. The current dimensions of the internal battery and controller will require future modifications to reduce their size while retaining charge capacity. The right-sided internal coil placement appears to be optimal based on

our cadaver studies, suggesting a more circular pleural cavity geometry that allows for coil upsizing. In animal trials up to 6 months, we found favorable results of lung vs internal coil interaction, but this interface interaction will require further focused attention. Our early experience in these implants has indicated an absence of overt compromise of the lung (atelectasis, external compression, or chronic effusion) and this has been substantiated by serial chest X-rays and computerized tomography scans. Importantly, optimal management of the internal coil at a time of transplantation will need to be defined.

Ensuring patient safety remains central to these innovations and constitutes an ethical conundrum. A hybrid design utilizing the externalized retroauricular bailout connector provided a pragmatic solution to balance safety and efficacy validation in this early investigational experience. Furthermore, we selected patients with an intended goal of a bridge to transplant in case a rescue bailout for the entire system were to become necessary. Importantly, the CET system as configured is capable of successful integration with most commercially available LVADs, a factor that has been tested by our group in long-term animal trials. This promise allows the technology to be paired with the most optimal device available to patients and offers the potential for scalable widespread application. This important first-in-human clinical experience of the CET system will need to be further validated by longer term safety and efficacy demonstration in larger numbers of patients.

The durability and impact seen on patient outcomes calls for large-scale trials using this technology.

## Disclosure statement

Y.P. is a medical advisory board member of LeviticusCardio, Ltd.; J.M. is a medical advisory board member, board member, and stockholder of LeviticusCardio, Ltd.; S.S. is a medical advisory board member and stockholder of LeviticusCardio, Ltd.; B.M. has an institutional research contract with LeviticusCardio, Ltd.; Y.K. is a chief medical officer and stockholder of LeviticusCardio, Ltd.; M.Z. is a chief executive officer and stockholder of LeviticusCardio, Ltd.; I.N. is a medical advisory board member, board member, and stockholder of LeviticusCardio, Ltd. The remaining authors have no conflicts of interest to disclose.

CET system development, integration with prevalent commercially available LVADs, animal experiments, and the first human clinical trial were sponsored by LeviticusCardio, Ltd. This project was supported in part by the Office of the Chief Scientist of the Ministry of Industry, Israel (Grants 49639, 55065, 38675, 56638, and 63319).

## Supplementary data

Supplementary data associated with this article can be found in the online version at [www.jhltonline.org/](http://www.jhltonline.org/).

## Supplementary materials

Supplementary material associated with this article can be found in the online version at <https://doi.org/10.1016/j.healun.2019.01.1316>.

## References

1. Mehra MR, Goldstein DJ, Uriel N, et al. Two-year outcomes with a magnetically levitated cardiac pump in heart failure. *N Engl J Med* 2018;378:1386-95.
2. Schmitto JD, Pyra Y, Zimpfer D, et al. Long-term evaluation of a fully magnetically levitated circulatory support device for advanced heart failure—two-year results from the HeartMate 3 CE Mark Study. *Eur J Heart Fail* 2019;21:90-7.
3. Kirklin JK, Xie R, Cowger J, et al. Second annual report from the ISHLT Mechanically Assisted Circulatory Support Registry. *J Heart Lung Transplant* 2018;37:685-91.
4. Goldstein DJ, Naftel D, Holman W, et al. Continuous-flow devices and percutaneous site infections: clinical outcomes. *J Heart Lung Transplant* 2012;31:1151-7.
5. Hasin T, Marmor Y, Kremers W, et al. Readmissions after implantation of axial flow left ventricular assist device. *J Am Coll Cardiol* 2013;61:153-63.
6. Baras Shreibati J, Goldhaber-Fiebert JD, Banerjee D, Owens DK, Hlatky MA. Cost-effectiveness of left ventricular assist devices in ambulatory patients with advanced heart failure. *JACC Heart Fail* 2017;5:110-9.
7. Mehra MR, Salerno C, Cleveland JC, et al. Healthcare Resource use and cost implications in the MOMENTUM 3 long-term outcome study. *Circulation* 2018;138:1923-34.
8. Mehta SM, Pae Jr WE, Rosenberg G, et al. The LionHeart LVD-2000: a completely implanted left ventricular assist device for chronic circulatory support. *Ann Thorac Surg* 2001;71(suppl): S156-61.
9. Dowling RD, Gray Jr LA, Etoch SW, et al. Initial experience with the AbioCor implantable replacement heart system. *J Thorac Cardiovasc Surg* 2004;127:131-41.
10. Waters BH, Park J, Bouwmeester JC, et al. Electrical power to run ventricular assist devices using the free-range resonant electrical energy delivery system. *J Heart Lung Transplant* 2018;37: 1467-74.
11. Westaby S, Jarvik R, Freeland A, et al. Postauricular percutaneous power delivery for permanent mechanical circulatory support. *J Thorac Cardiovasc Surg* 2002;123:977-83.