

Letter to the Editor

Ethical considerations regarding head transplantation

Anto Čartolovni, Antonio G. Spagnolo

Università Cattolica del S. Cuore (Catholic University of the Sacred Heart), "A. Gemelli" School of Medicine, Institute of Bioethics, 1, Largo Francesco Vito, I-00168 Rome, Italy

E-mail: *Anto Čartolovni - anto_cartolovni@yahoo.com; Antonio G. Spagnolo - agspagnolo@rm.unicatt.it

*Corresponding author

Received: 25 March 15 Accepted: 05 May 15 Published: 15 June 15

This article may be cited as:Cartolovni A, Spagnolo AG. Ethical considerations regarding head transplantation. *Surg Neurol Int* 2015;6:103.Available FREE in open access from: <http://www.surgicalneurologyint.com/text.asp?2015/6/1/103/158785>

Copyright: © 2015 Čartolovni A. This is an open-access article distributed under the terms of the Creative Commons Attribution License, which permits unrestricted use, distribution, and reproduction in any medium, provided the original author and source are credited.

Dear Editor,

We read with interest and some perplexity the article by the Italian surgeon, Sergio Canavero, on the subject of head transplantation commonly known as HEAVEN surgery shorthand for its more full name, "head anastomosis venture" and GEMINI spinal cord fusion (SCF) procedure.^[2] We find it essential to address some crucial ethical questions that might even clarify the real need for the HEAVEN and GEMINI SCF procedures. Recently he drew much attention with his procedure. Well known bioethicist Arthur Caplan stated in *Forbes* that "it is both rotten scientifically and lousy ethically."^[3] In his previous article,^[1] Canavero emphasized that he didn't address the ethical aspects, but we find it essential to address some of the ethical issues in order to bring to light the real necessity for this procedure. Although the technical feasibility of the GEMINI SCF procedure is not entirely clear, even for neurologists, the question to ask is how can the axons in the spinal cord be properly connected or glued with each other, even with a most precise cut. Despite the uncertainty regarding the technical feasibility of this procedure, for the sake of argument, we will assume that the procedure is possible and feasible to perform. Before entering into the sphere of human head transplantation, the first ethical problem that the HEAVEN and GEMINI SCF procedures will encounter is its approval by the Animal Welfare and Ethics Research Committee to perform pre-clinical experimentation on animals. Previous experiments of Robert J. White and Vladimir Demikhov affirmed that these kinds of experiments were lethal for animals and even the final outcome of the experimentation was more for the sake of experimentation. The HEAVEN procedure, seen in its finality, is not a therapeutic

procedure but one for prolonging life, that could even play an essential role in the decision to accept it. Even if the procedure is accepted in years to come, the subject will be exposed to far greater and unknown risks than the benefits of the procedure. First of all, assuming that the spinal cord connection succeeds, the patient will need to take a large amount of immunosuppressive drugs and it is not even clear if the rejection problem will be solved by taking such drugs. Starting with a presupposition that transplanting the head with a brain would automatically transplant the whole person with its mind, personality and consciousness, Canavero brings forth a mechanistic framework of the human person. Despite his vision, modern cognitive science shows that our cognition is an embodied cognition, in which the body is a real part in the formation of human self. Therefore, the person will encounter huge difficulties to incorporate the new body in its already existing body schema and body image that would have strong implications on human identity. Even memories of the role the former body played in the creation of the subjects identity would encounter possible conflict with a new donor given body, because the identity would reflect itself in the corporeality that does not exist anymore. Similar issues were also seen in cases of face and hand transplants. This confusion to the person's psychological state could possibly lead

Access this article online**Quick Response Code:****Website:**www.surgicalneurologyint.com**DOI:**

10.4103/2152-7806.158785

to serious psychological problems, namely insanity and finally death. Another ethical issue that could emerge in this procedure, that Canavaro himself addresses, is the problem of the donor's gonads and the transmission of genetic inheritance to the offsprings. As a matter of fact, these organs are related to each other, because they are human identity organs, and therefore they are by some legislations forbidden for transplantation (e.g. the Italian law).^[4] Moreover, this procedure encounters some social and ethical problems facing organ donations: on one hand because of uncertainty of the procedure, the donor body with its organs would be wracking the organs that could be useful to someone else that needs a heart or liver that could save his/her life. Finally, the same idea of the head transplant and the donation procedure could provoke strong side-effects in the form of a "yuck

factor"^[5] toward organ donation, in general, among the people.

REFERENCES

1. Canavero S. HEAVEN: The head anastomosis venture Project outline for the first human head transplantation with spinal linkage (GEMINI). *Surg Neurol Int* 2013;4:S335-42.
2. Canavero S. The "Gemini" spinal cord fusion protocol: Reloaded. *Surg Neurol Int* 2015;6:18.
3. Caplan A. Doctor Seeking to Perform Head Transplant is Out of his Mind. *Forbes*; 2015. p. 1. Available from: <http://www.forbes.com/sites/arthurcaplan/2015/02/26/doctor-seeking-to-perform-head-transplant-is-out-of-his-mind/>. [Last cited on 2015 Mar 10].
4. Italian Parliament. Law n. 91/1999 Dispositions on organs and tissues retrieval. *Official Gazette*. 1999;87:art. 3, para 3. ("It is forbidden the retrieval of gonads and of encephalon").
5. Niemelä J. What puts the 'yuck' in the yuck factor? *Bioethics* 2011;25:267-79.

Commentary

"Upon a slight conjecture, I have ventured on a dangerous journey, and I already behold the foothills of new lands. Those who have the courage to continue the search will set foot upon them..."

–Immanuel Kant (1775)

The recent renewed effort toward achievement of the arguably most ambitious medical enterprise ever – reconnecting a head to a body – has sparked a global controversy of biblical proportion, reaching tones bordering on fanaticism – not to mention slander. This climaxed with the recent coverage of the topic by the highly influential British journal *New Scientist* in February 2015. At the time of this writing, the world of medicine is roughly split into two camps: On one side, highly vocal critics, often from the academe, on the other, a growing – but media-silent – army of enthusiastic supporters writing or calling to be part of this "historic" first surgery. To cap it all, the first volunteer, a dystrophic 30-year-old Russian, has been announced amid the clamor and a Chinese group led by Dr. Xiaoping Ren already swapped the heads in rats.

So I extend my heartfelt thanks to this Journal's editors for granting me the possibility of further rebutting reasonable criticisms and providing additional evidence for the feasibility of this medical "moon-shot."

SPINAL CORD RECONNECTION HAS ALREADY BEEN ACHIEVED

In 2005, a 24-year-old woman was reported who had sustained a high-speed skiing accident that resulted in a

complete anatomical transection of her spinal cord at the T6-7 level. Over the next years following her injury, the patient retained complete motor loss at the T6-7 level with an associated sensory loss at that level (ASIA A). Thirty-nine months after her SCI, the patient underwent reconstruction of her spinal cord. This was done by totally removing her extensive cord scar that measured 4 cm in length, inserting 4cc of collagen into the gap followed by placement of an omental pedicle directly on the underlying collagen. Three months following surgery, the patient began rehabilitation. At 6 months, she could actively move her legs on command. One year after surgery, she began to have trunk and abdominal wall strength. Magnetic resonance imaging (MRI) taken over the years demonstrated the progressive development of a longitudinal extension of the soft tissue mass seen in the earlier MRI in association with further improvement in her neurological condition. By 4 years after surgery, the patient had progressed to where she could walk for extensive distances but continued to require a walker since she lacked balance and was unstable without her walker.^[8]

In 2014, a Polish team reported on a 38-year-old man who had sustained traumatic transection of the thoracic spinal cord at T9. At 21 months after injury, the patient presented symptoms of a clinically complete spinal cord injury (ASIA A). One of the patient's olfactory bulbs was removed and used to derive a culture containing olfactory ensheathing cells and olfactory nerve fibroblasts. Following resection of the glial scar, the cultured cells were transplanted into the spinal cord stumps above and below the injury and the 8-mm gap bridged by four strips of autologous sural nerve. The patient underwent

an intense pre- and post-operative neurorehabilitation program. At 19 months postoperatively, the patient improved from ASIA A to ASIA C. There was improved trunk stability, partial recovery of the voluntary movements of the lower extremities, and an increase of the muscle mass in the left thigh, as well as partial recovery of superficial and deep sensation. There was also some indication of improved visceral sensation and improved vascular autoregulation in the left lower limb.^[14] In this latter case, sural nerve bridges were implanted in the former scar area. Attempts at circumventing the lesional area with similar grafts have been attempted several times. For instance, a French group operated on a paraplegic patient 3 years after spinal cord injury at the T9 level. Three segments from autologous sural nerves were implanted into the right and left antero-lateral quadrant of the cord at T7-8 levels, then connected to homolateral L2-4 lumbar ventral roots, respectively. Eight months after surgery, voluntary contractions of bilateral adductors and the left quadriceps were observed. Muscular activity was confirmed by motor unit potentials (MEPs) in response to attempted muscle contraction and MEPs were recorded.^[15]

These two contemporary cases prove that a transected spinal cord can be bridged with functional restoration – although not perfectly and over years if a long gap has to be covered (8-mm and 4 cm). But actually animal studies had already made the point decades earlier. US neurosurgeon Dr. L. Freeman had already made extensive observations of what happens when one sharply transects a spinal cord. In his own words, “occasionally, a paraplegic rat would walk several months after (sharp) cord transection...in the area of transection, numerous growing axons from such a walking rat are shown...the work that we have conducted up to this point was nothing more than an extension of Dr. Cajal’s...exposition of the ability of intact live spinal axons to re-grow severed axons. The principal difference...lies in the area of better health of the animals and survival in good health...Cajal’s...animals were in failing health...70–100 days of very good health was required...when we were able to maintain adult dogs in good health for long enough periods of time, they too showed functional return...they show liberal growth of axons from viable neurons in the spinal cord that have penetrated the area of transection and have established function. Furthermore, they show conduction of electrical impulses.” Monkeys were much harder to tend to, and they thus focused on hemisections: Here too axons regrew.^[7] “Realizing that the average clinical injury to the spinal cord is not a sharp surgical transection such as that which we used in the early experimental procedures, but instead that it is a broad, long lesion, we set out to devise surgical procedures to duplicate these circumstances. To bring fresh ends of the divided

spinal cord together, we resected enough vertebral body and thus shortened the spine. The damaged area could be removed and by suturing the dura mater, we could approximate the fresh ends of the spinal cord. Walking animals resulted from this procedure and axons grew through the area where the cord resection and anastomosis had been conducted” [Figure 1].

As I explained in the GEMINI paper, the key to the whole procedure is the long-neglected existence of a motor-sensory highway in the gray matter. This can support motricity without the pyramidal tract. The evidence is simply overwhelming.^[5] As further evidence, a rat has been engineered that has no pyramidal tract and walks thanks to the input of the reticulospinal tract onto the interneuronal motor pathway.^[9] Primates can perform arm and hand movements without a pyramidal tract, merely thanks to the propriospinal system alone.^[1,13] Even if no axon could be refused during GEMINI, the whole recovery would hinge on the regenerative sprouting of the minimally damaged (just a very thin layer) propriospinal highways from the two reapposed cord stumps. Polyethylene Glycol (PEG) and electricity would speed up and improve the fusion process (which however, will certainly also include axons in the white matter). Misalignment – which is inevitable - will be offset by rewiring in the cord upstream and in the brain (as occurs in spinal cord injury cases that recover function).^[5]

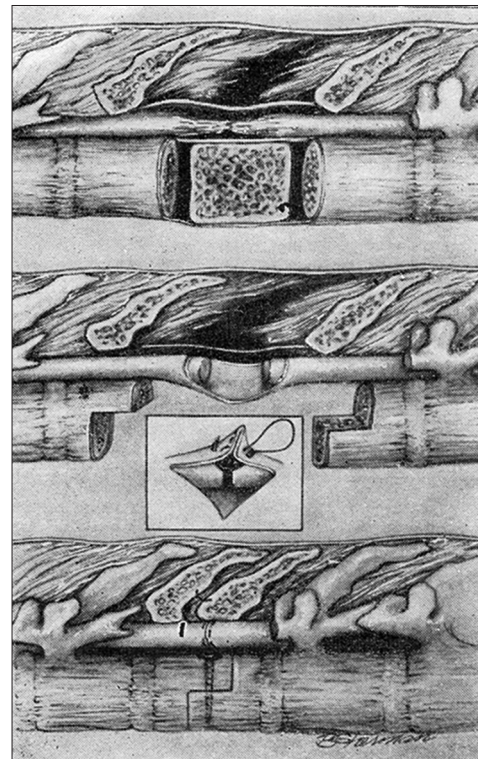


Figure 1: Spinal paralysis would be cured by removing the cord's damaged portion and bringing the two healthy stumps together after shortening the vertebral column (from Freeman 1963).

Finally, the scientist who introduced PEG to the field has recently caught on to the power of PEG - along with peripheral nerve bridges - in providing a long-sought cure for spinal paralysis.^[12]

POSSIBLE IMMUNE REJECTION IS NO CONTRAINDICATION

The major obstacle to HEAVEN is the possibility of immune rejection of the head by the new body. Unlike single organ transplants, a head transplant is a composite tissue allotransplantation (CTA) consisting of skin, muscle, tendons, bone, cartilage, fat, nerves, and blood vessels – and of course the brain. Each individual tissue possesses a different degree of antigenicity: The skin, being the most antigenic organ in the human body, elicits a strong immune response when recognized as foreign tissue. Thus, in order to assess whether HEAVEN is possible, we must turn our attention to other CTAs, and see what happens. The hand is a good case in point. In September 1998, the first human hand transplant was performed by a team of surgeons in Lyons, France (this patient later developed a psychological rejection to the hand and had it removed in 2001). About 30 face and almost 100 upper-extremity (including bilateral) allotransplantations have taken place to date.^[4] Although acute rejection episodes occurred in 85% of subjects within the 1st year, these were all successfully managed by altering the postoperative immunosuppressive regimen. In fact, current long-term graft survival is 94%, and graft failure is solely due to noncompliance with the immunosuppressive medication. The complications are on a par with solid organ grafting, with 5-year survival rates greater than in solid organ transplants. Chronic rejection has been observed for hand transplants, but not for facial transplantation. Novel immunosuppressive protocols have actually allowed a decrease in the number and dosages of traditional immunosuppressants. Therefore, despite the heterogeneity of foreign antigens associated with CTAs, current immunosuppressive protocols have proved to be effective in preventing rejection in patients with hand and facial transplants. Admittedly, opportunistic infections such as cytomegalovirus reactivation, clostridium, and herpetic infections occur in a majority of patients, along with metabolic complications such as hyperglycemia, hyperlipidemia, and impaired renal function. Of note, however, no life-threatening complications or malignancies have been reported.^[4] Ideally, head transplantees should not receive life-long immunosuppression. Attempts to achieve drug-free tolerance are in progress with some preliminary promising results. A recent trial showed that “rebooting” someone’s immune system can be achieved by a combination of intravenous alemtuzumab given during the transplant

surgery, belatacept given parenterally and oral sirolimus. A year after surgery, no one had symptoms of organ rejection or any need to take the standard posttransplant drugs (up to 20 drugs daily!). Three-and-a-half years after surgery, 7 need only a single monthly injection of belatacept, the other 13 the injection plus one daily pill of sirolimus. Other attempts involve low-dose interleukin two protocols.^[4] On the other hand, it has been known for decades that immunosuppression helps the central nervous system to regenerate, so, at least initially, the immune system should be held at bay to give time to the stumps to achieve maximum fusion.^[5]

In any event, it will be the donor body that rejects the head, not the other way around. The head makes up 8% of body weight, which is what one sees in combined chest or abdominal or multiple limb transplants.

THE SELF AND PSYCHOLOGICAL TOLERANCE

As mentioned, failure of the first-hand transplant followed poor integration of the transplanted hand into the patient’s own body image. This was a direct consequence of suboptimal patient preparation and inadequate expectations. Accepting a foreign hand as one’s own requires long-term psychological resilience. Transplant recipients are therefore carefully selected through clinical and psychiatric screening. Following the procedure, ongoing support is required, focusing on physical and psychological rehabilitation. Luckily, no other psychological rejection has been reported, due to better screening. The same reasoning applies to HEAVEN, where a full body is anastomosed. In order to make the process more reliable, HEAVEN will exploit immersive virtual reality (IVR) over the months following the actual surgery so that the subject can grow used to the new body. Hypnosis will also be brought to bear on the process.

That said. Modern cognitive science clearly proves one thing: The self is simply an illusion that can be manipulated at will.^[10] I myself created a supernumerary phantom arm in the course of motor cortex stimulation for chronic pain,^[2] by altering brain plasticity! In the field of IVR, the rubber hand illusion shows that a rubber arm can be incorporated into what feels as if it is part of the body, the shrinking waist illusion can give the strong sensation of the waist radically reducing (or expanding) in size, and the Pinocchio illusion that the nose has grown very long. An illusory transformation of the whole body is possible including the substitution of the real body by a virtual body (Slater M, <http://cbc.upf.edu/node/17729>).

This is why the AVATAR initiative is confident that they can transplant a brain inside a cyborg within 10 years:

It is called the plasticity principle that together with the relativistic brain hypothesis^[11] will allow humans to transcend biology within our lifetime.

One point that has not been raised by the critics is the microbiome. We now know that the gut intestinal flora (GIF) can shape human behavior and psychological health.^[6] In HEAVEN, the donor's GIF would influence the recipient's brain. Fortunately, the GIF can be manipulated.

ANIMAL STUDIES UNETHICAL?

Millions of animals are killed (euthanized?) every year to advance the academic standing of those who perform these experiments (pp 328-9).^[3] And committees approve anything. We and many others proved that the vast majority of these studies lead nowhere. Yet, they continue to feed thousands of medical journals including all the most prestigious. At the same time, a few of these studies have changed the way we do medicine, including Robert J. White and Vladimir Demikhov contributions, huge advances that were certainly not done merely for the sake of experimentation. The PEG studies are another exception.

OF LAWS AND MAN AND...YUCK

HEAVEN will certainly not happen in Italy, so we can confidently set that legalistic “stumbling block” aside.

The fact that the gonads belong to the body donor is actually a facilitator for the whole enterprise. Imagine the parents of the brain dead body donor – racked by sorrow and despair for their loss - who are told that, once the new being will start reproducing, his or her offspring will actually be their (the donor's parents) descendants! Life out of death.

Finally, even from the crippled recipient's body, some organs might be salvageable to help other lives. Advances in artificial organs (e.g., artificial heart) will also help allay similar misgivings.

As for the Yuck Factor, mankind has no qualms killing (including nuking), maiming, torturing, starving, oppressing other humans (Stalin, Mao, Pol Pot, Hitler,...) and did so for millions of years. I would say that it

is mankind (and its ethicists) that is “both rotten scientifically and lousy ethically.”

Notice: HEAVEN/GEMINI and its implications are described in detail in two TEDx talks (Limassol and Verona) and two AMAZON books (“immortal” and “head transplantation and the quest for immortality”).

Sergio Canavero

Turin Advanced Neuromodulation Group, Turin, Italy.
E-mail: Sercan@inwind.it

REFERENCES

1. Alstermark B, Pettersson LG, Nishimura Y, Yoshino-Saito K, Tsuboi F, Takahashi M, et al. Motor command for precision grip in the macaque monkey can be mediated by spinal interneurons. *J Neurophysiol* 2011;106:122-6.
2. Canavero S, Bonicalzi V, Castellano G, Perozzo P, Massa-Micon B. Painful supernumerary phantom arm following motor cortex stimulation for central poststroke pain. Case report. *J Neurosurg* 1999;91:121-3.
3. Canavero S, Bonicalzi V. *Central Pain Syndrome*. Cambridge: Cambridge University Press; 2011.
4. Canavero S. *Head Transplantation and the Quest for Immortality*. Amazon; 2014.
5. Canavero S. The “Gemini” spinal cord fusion protocol: Reloaded. *Surg Neurol Int* 2015;6:18.
6. Dinan TG, Stilling RM, Stanton C, Cryan JF. Collective unconscious: How gut microbes shape human behavior. *J Psychiatr Res* 2015;63:1-9.
7. Freeman LW. Observation on the Regeneration of Spinal Axons in Mammals. *Proceedings, X Congreso Latinoamericano de Neurocirugía*. Editorial Don Bosco; 1963. p. 135-44.
8. Goldsmith HS, Fonseca A Jr, Porter J. Spinal cord separation: MRI evidence of healing after omentum-collagen reconstruction. *Neurol Res* 2005;27:115-23.
9. Han Q, Cao C, Ding Y, So KF, Wu W, Qu Y, et al. Plasticity of motor network and function in the absence of corticospinal projection. *Exp Neurol* 2015;267:194-208.
10. Hood B. *The Self Illusion*. Oxford: Oxford University Press; 2012.
11. Nicoletis M. *Beyond Boundaries*. London: St Martin's Griffin; 2011.
12. Riley DC, Bittner GD, Mikesh M, Cardwell NL, Pollins AC, Ghergherehchi CL, et al. Polyethylene glycol-fused allografts produce rapid behavioral recovery after ablation of sciatic nerve segments. *J Neurosci Res* 2015;93:572-83.
13. Sasaki S, Isa T, Pettersson LG, Alstermark B, Naito K, Yoshimura K, et al. Dexterous finger movements in primate without monosynaptic corticomotoneuronal excitation. *J Neurophysiol* 2004;92:3142-7.
14. Tabakow P, Raisman G, Fortuna W, Czyz M, Huber J, Li D, et al. Functional regeneration of supraspinal connections in a patient with transected spinal cord following transplantation of bulbar olfactory ensheathing cells with peripheral nerve bridging. *Cell Transplant* 2014;23:1631-55.
15. Tadie M, Liu S, Robert R, Guiheneuc P, Pereaon Y, Perrouin-Verbe B, et al. Partial return of motor function in paralyzed legs after surgical bypass of the lesion site by nerve autografts three years after spinal cord injury. *J Neurotrauma* 2002;19:909-16.