

# TEVAR for traumatic thoracic injury with the first-generation stent graft

Giovanni Tinelli, MD, PhD,<sup>a</sup> Fabrizio Minelli, MD,<sup>a</sup> Simona Sica, MD,<sup>a</sup> Francesca De Nigris, MD,<sup>a</sup> Massimo Massetti, MD,<sup>b</sup> and Yamume Tshomba, MD,<sup>a</sup> Rome, Italy

## ABSTRACT

Thoracic endovascular aortic repair (TEVAR) is a life-saving treatment for blunt thoracic aortic injury. We report long-term outcomes of two young patients who underwent TEVAR for blunt thoracic aortic injury with first-generation thoracic stent grafts. The off-label use of the endograft affected the outcomes: one case of open surgery conversion due to an aortoesophageal fistula and one case of endovascular relining for a voluminous pseudoaneurysm associated with a type III endoleak. Long-term follow-up is crucial in TEVAR, especially in case of a first-generation device used in an urgent setting. (*J Vasc Surg Cases and Innovative Techniques* 2021;7:16-20.)

**Keywords:** Thoracic endovascular aortic repair; Thoracic aortic injury; Thoracic aorta; Personalized medicine

Blunt thoracic aortic injury (BTAI) is a life-threatening emergency, usually resulting from a relevant deceleration at the aortic isthmus level, and it is reported that up to 80% of patients die instantly.<sup>1,2</sup>

Open surgical repair has been the standard procedure for BTAI since it was introduced in 1959.<sup>3</sup> This surgery consists of thoracotomy, systemic anticoagulation, use of cardiopulmonary bypass, and aortic cross-clamping. It results in a high postoperative mortality rate and frequent major postoperative complications.<sup>4</sup>

In fact, several dilatative complications have been described after complex aortic surgery such as aneurysms and pseudoaneurysms and often a variety of procedures are needed, but the real fate of these complications is often only partially known.<sup>5,6</sup>

In 1997, Kato et al<sup>7</sup> were the first to report the use of stent grafts for BTAI. Over the last two decades, thoracic endovascular aortic repair (TEVAR) has become the gold standard treatment in these patients.<sup>8</sup>

Although TEVAR had been considered as a safe and a superior alternative to open repair,<sup>9</sup> severe complications may occur, including device-related complications, ischemic complications secondary to embolic events,

and graft infection with aortobronchial or aortopulmonary fistulation.<sup>10-12</sup>

However, TEVAR long-term results and efficacy remain unknown, mostly for young patients.

We describe long-term outcomes of two young patients treated with TEVAR for BTAI with the first-generation thoracic stent graft. The patients' consent for publication was obtained.

## CASE 1

A 34-year-old man underwent TEVAR with the EndoFit thoracic stent-graft system (LeMaitre Vascular, Inc, Burlington, Mass; Fig 1) due to a grade III (pseudoaneurysm) BTAI at the age of 19 years in 2002 after a car accident. The patient did not undergo a regular scheduled follow-up, and 15 years after the first treatment, he presented with an acute onset of severe back and chest pain, hemoptysis, and fever. The computed tomography angiography (CTA) and the esophagogastroduodenoscopy showed a fistula between the aortic stent graft and the esophagus (Fig 2). The gastric cavity was full of blood clots. Open late conversion was highly recommended. Surgery was performed by left thoracotomy, with extracorporeal circulation. The stent graft was explanted, the aorta was reconstructed with a 28-mm gelatin-sealed Dacron graft (Gelweave; Vascutek Terumo, Renfrewshire, Scotland; Fig 1, B), and the aortoesophageal fistula was repaired. The postoperative course was complicated by early reintervention for hemostasis revision due to a massive bleeding, caused by laceration of the ascending aorta. At early follow-up, we found dysphonia and paralysis of the left vocal cord caused by open repair that required speech therapy cycles and lipofilling surgery of the vocal cord with partial voice rehabilitation.

## CASE 2

The second case that we report is a young man who underwent TEVAR for grade III BTAI after a motor vehicle accident at the age of 26 years in 1997. A 100-mm-long stent graft constructed from modified Z-stents covered with expanded polytetrafluoroethylene graft material was deployed in proximal landing zone 3.<sup>13</sup> The patient did not perform the planned

---

From the Unit of Vascular Surgery,<sup>a</sup> and Unit of Cardiac Surgery,<sup>b</sup> Fondazione Policlinico Universitario Agostino Gemelli IRCCS, Università Cattolica del Sacro Cuore.

Author conflict of interest: none.

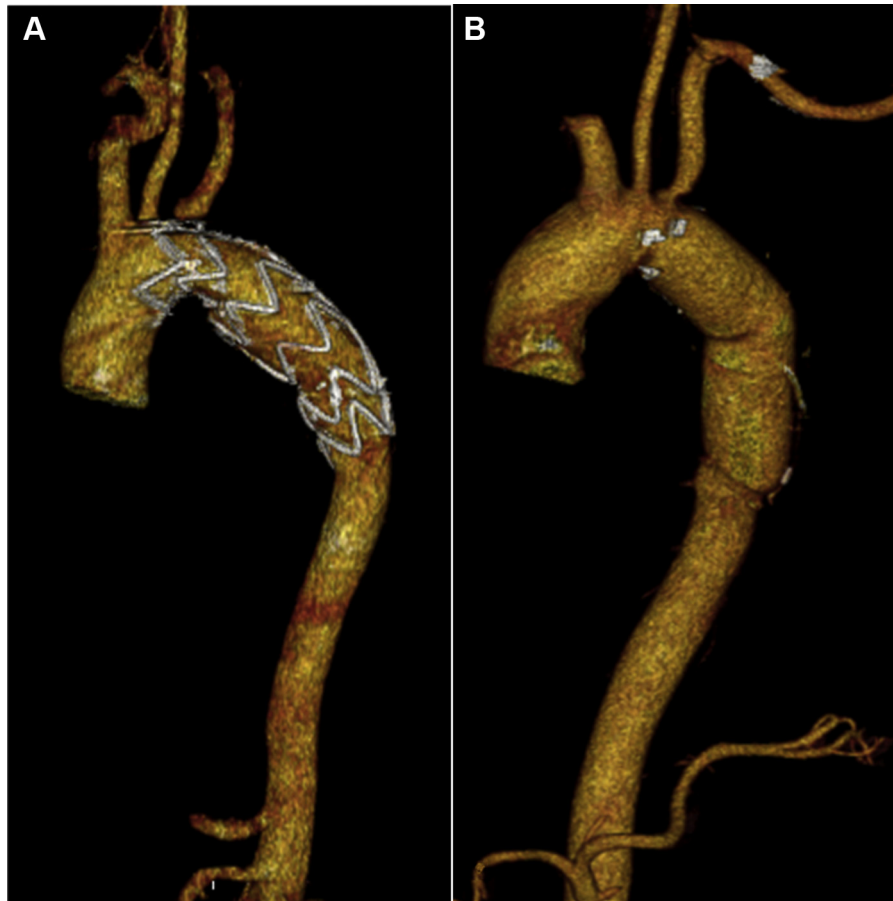Correspondence: Giovanni Tinelli, MD, PhD, Unit of Vascular Surgery, Fondazione Policlinico Universitario Agostino Gemelli IRCCS, Università Cattolica del Sacro Cuore, Largo Agostino Gemelli, 8, 00168 Rome, Italy (e-mail: [giovanni.tinelli@policlinicogemelli.it](mailto:giovanni.tinelli@policlinicogemelli.it)).

The editors and reviewers of this article have no relevant financial relationships to disclose per the Journal policy that requires reviewers to decline review of any manuscript for which they may have a conflict of interest.

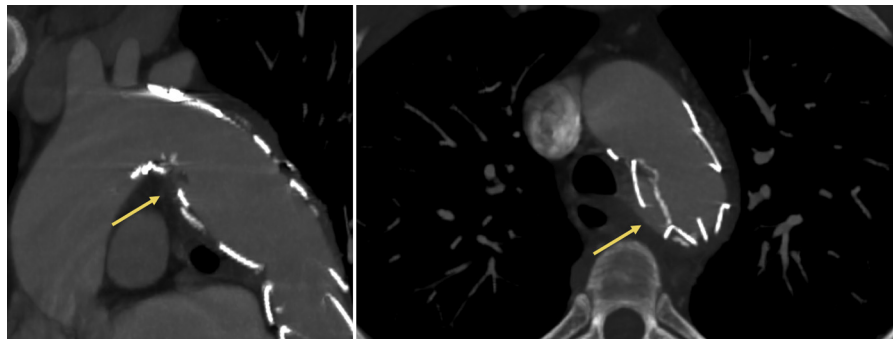
2468-4287

© 2020 The Author(s). Published by Elsevier Inc. on behalf of Society for Vascular Surgery. This is an open access article under the CC BY-NC-ND license (<http://creativecommons.org/licenses/by-nc-nd/4.0/>).

<https://doi.org/10.1016/j.jvscit.2020.08.035>



**Fig 1.** Volume rendering of thoracic endovascular aortic repair (TEVAR) with the EndoFit thoracic stent-graft system (A) and volume rendering of aortic reconstruction with a gelatin-sealed Dacron graft (B).



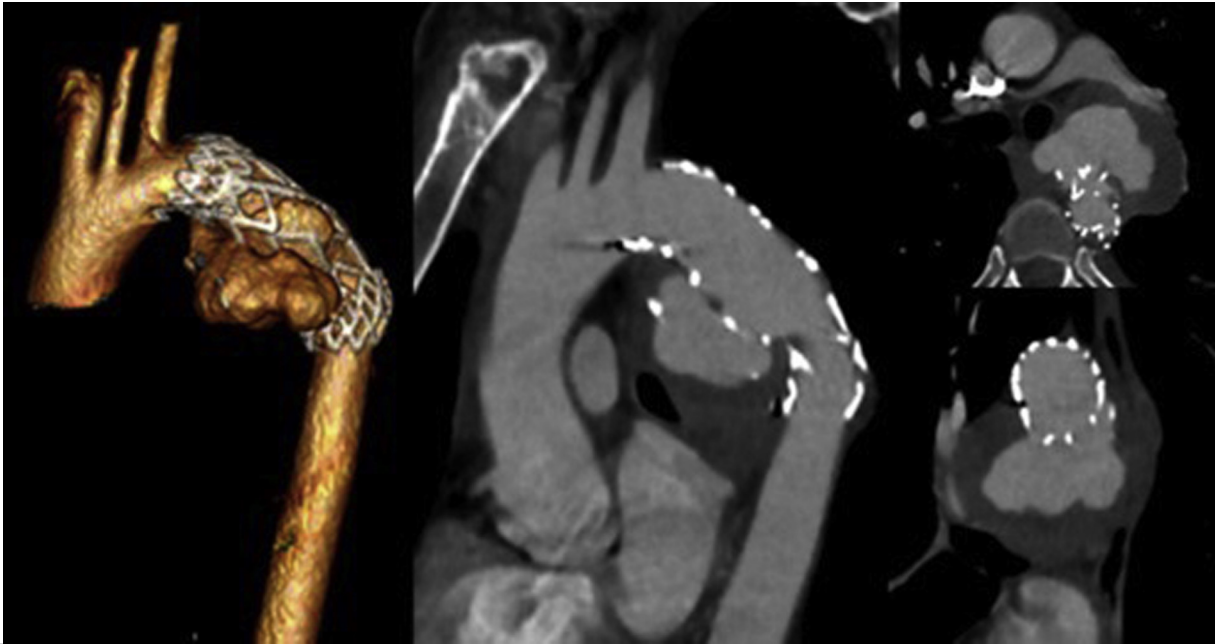
**Fig 2.** Multiplanar reconstruction showing the aorto-esophageal fistula after thoracic endovascular aortic repair (TEVAR).

regular follow-up over time, and after 21 years from the endovascular procedure, a CTA showed an asymptomatic voluminous pseudoaneurysm of the post-isthmic thoracic aorta with a maximum diameter of 60 mm with a type III endoleak (Fig 3).

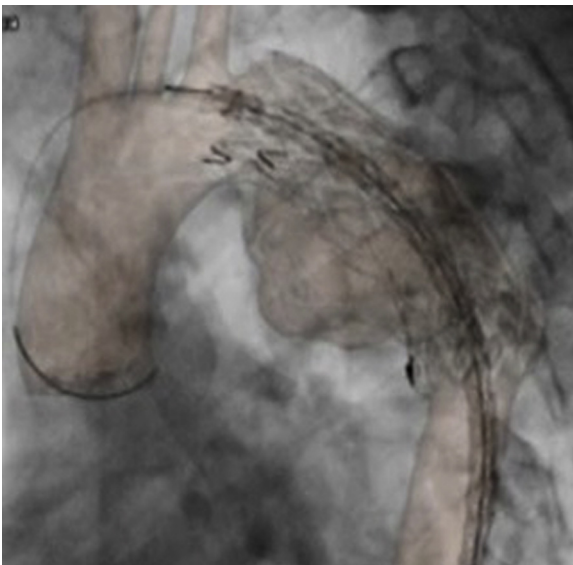
A proximal relining TEVAR in proximal landing zone 3<sup>13</sup> with Conformable Gore TAG Thoracic Endoprosthesis (W. L. Gore and Associates, Flagstaff, Ariz), using a bilateral femoral percutaneous approach, was performed. The procedure was carried out

under three-dimensional fusion imaging in our hybrid room (Fig 4), with lower costs in terms of X ray and contrast medium exposure.<sup>14</sup> The postoperative computed tomography (CT) scan showed the complete exclusion of the pseudoaneurysm dilatation (Fig 5).

The patient was discharged on the third postoperative day. After 1 year, the patient underwent a CT examination that showed no signs of endoleak or graft migration.



**Fig 3.** Volume rendering and multiplanar reconstruction of thoracic endovascular aortic repair (TEVAR) that shows a type III endoleak.



**Fig 4.** Relining thoracic endovascular aortic repair (TEVAR) under three-dimensional fusion imaging.

## DISCUSSION

Aortic injury is the second most frequent cause of death in cases of blunt traumatic injury.<sup>15</sup> TEVAR has an increasing role in the treatment of BTAI, with a lower rate of mortality, spinal cord ischemia, and renal failure with respect to the traditional open surgical repair. Current Society for Vascular Surgery clinical practice guidelines recommend the use of TEVAR for grade II-IV and nonoperative management for grade I BTAI.<sup>8</sup>

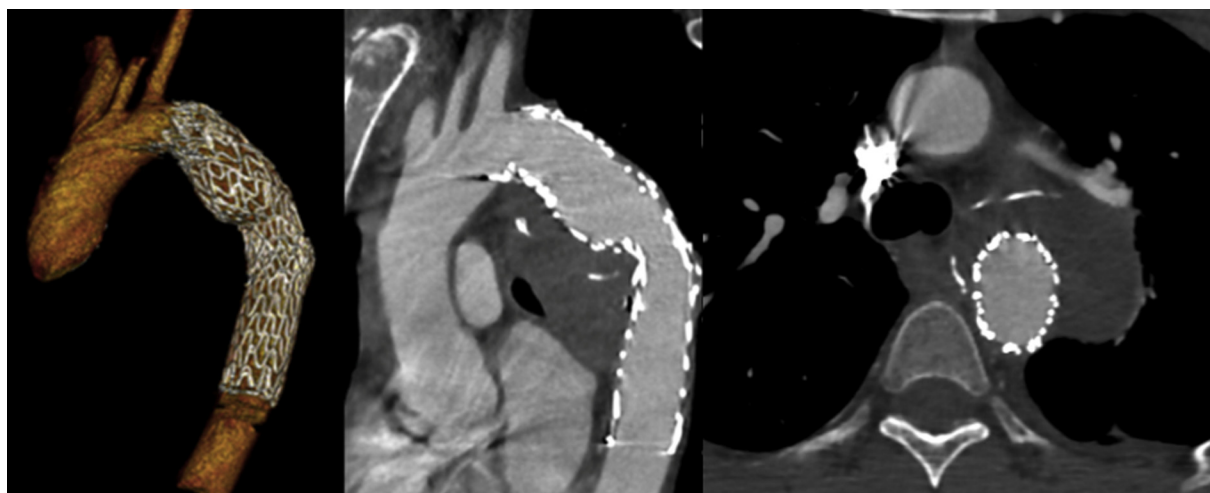
In consideration of the severity of the traumatic pathology and the reduced frequency in which it occurs, data comparing open repair and TEVAR are limited, and there are no randomized controlled studies comparing the two interventions. Harky et al<sup>9</sup> in their systematic review and meta-analysis demonstrate a significant survival rate at 30 days and 1 year with the use of TEVAR. Indeed, TEVAR quickly became a universally accepted alternative to conventional open surgery.<sup>16</sup>

TEVAR for BTAI is associated with a 7.3% in-hospital mortality in Vascular Quality Initiative, and independent risk factors for mortality include age, male gender, renal impairment, left subclavian artery involvement, and overall injury burden.<sup>8</sup>

In terms of reintervention, in Harsky's meta-analysis, there was no difference between TEVAR and open repair; the reintervention in the TEVAR group was related to endoleaks, whereas in the open repair cohort, the main cause of reintervention was bleeding. However, there are scarce data regarding the long-term follow-up.

A rare but extremely serious complication is represented by the aortobronchial or pulmonary fistula. The incidence of either fistulizations in the entire cohort after TEVAR is reported to be approximately 0.56% in the literature.<sup>11,12</sup>

In our cases, the patients were very young and, at the time of treatment, a few cases of TEVAR had been carried out, especially for aortic trauma, as a life-saving treatment.



**Fig 5.** Volume rendering and multiplanar reconstruction of postoperative computed tomography (CT).

It is important to analyze the limitations of TEVAR for BTAI that determined serious complications, especially in long-term follow-up. Although the devices used in these patients were off label and implanted at a time before commercially available, the complications associated with these repairs are certainly applicable to modern devices and highlight the importance of long-term follow-up. In the majority of cases, patients with BTAI are young, with a small aortic diameter, and with focal lesions requiring a very limited aortic coverage, without the oversizing generally used in the aneurysmal pathology. Life expectancy in these young patients is very long, and then the follow-up should be tighter and longer than other treatments. However, a specific surveillance program for patients with BTAI treated with TEVAR has not yet been established. To make the follow-up more effective and pursued, we suggest that one way to reduce the exposure of patients to X rays could be an alternation between the angio-CT examination and the transesophageal echocardiogram. We recommend performing the first CTA 1 month after the procedure and, in the absence of complications, at 12 and 24 months. Then, we propose to alternate a transesophageal echocardiogram to a CTA every 2 years lifelong. The patient must be adequately informed of his condition and of the surgical treatment to which he has undergone to make himself part of the complex follow-up process that will inevitably accompany him throughout his life. In light of these considerations, the follow-up must be conceived as an integral part of the treatment that finds its completion only in the long term.

## CONCLUSIONS

TEVAR is the first choice of treatment for traumatic isthmic rupture. Our reports highlight the need for continued and tight surveillance of patients after TEVAR, especially in the case of first-generation devices used in

an urgent setting, or in case of young people with a long-term follow-up expectancy.

## REFERENCES

1. Parmley LF, Mattingly TW, Manion WC, Jahnke EJ. Non-penetrating traumatic injury of the aorta. *Circulation* 1958;17:1086-101.
2. Buz S, Zipfel B, Mulahasanovic S, Pasic M, Weng Y, Hetzer R. Conventional surgical repair and endovascular treatment of acute traumatic aortic rupture. *Eur J Cardiothoracic Surg* 2008;33:143-9.
3. Passaro E, Pace WC. Traumatic rupture of the aorta. *Surgery* 1959;46:787-91.
4. Cowley RA, Turney SZ, Hankins JR, Rodriguez A, Attar S, Shankar BS. Rupture of thoracic aorta caused by blunt trauma: a fifteen year experience. *J Thorac Cardiovasc Surg* 1990;100:652-60.
5. Tshomba Y, Bertoglio L, Marone EM, Melissano G, Chiesa R. Visceral aortic patch aneurysm after thoracoabdominal aortic repair: conventional vs hybrid treatment. *J Vasc Surg* 2008;48:1083-91.
6. Tshomba Y, Melissano G, Civilini E, Setacci F, Chiesa R. Fate of the visceral aortic patch after thoracoabdominal aortic repair. *Eur J Vasc Endovasc Surg* 2005;29:383-9.
7. Kato N, Dake MD, Miller DC, Semba CP, Mitchell RS, Razavi MK, et al. Traumatic thoracic aortic aneurysm: treatment with endovascular stent-grafts. *Radiology* 1997;205:657-62.
8. Mohapatra A, Liang NL, Makaroun MS, Schermerhorn ML, Farber A, Eslami MH. Risk factors for mortality after endovascular repair for blunt thoracic aortic injury. *J Vasc Surg* 2020;71:768-73.
9. Harky A, Chan JS, Wong CH, Bashir M. Open versus endovascular repair of descending thoracic aortic aneurysm disease: a systematic review and meta-analysis. *Ann Vasc Surg* 2019;54:304-15.
10. Pang D, Hildebrand D, Bachoo P. Thoracic endovascular repair (TEVAR) versus open surgery for blunt traumatic thoracic aortic injury. *Cochrane Database Syst Rev* 2019;2:CD006642.
11. Czerny M, Reser D, Eggebrecht H, Janata K, Sodeck G, Etz C, et al. Aorto-bronchial and aorto-pulmonary fistulation after thoracic endovascular aortic repair: an analysis from the

- European Registry of Endovascular Aortic Repair Complications. *Eur J Cardiothorac Surg* 2015;482:252-7.
12. Marone EM, Baccari P, Brioschi C, Tshomba Y, Staudacher C, Chiesa R. Surgical and endovascular treatment of secondary aorto-esophageal fistula. *J Thorac Cardiovasc Surg* 2006;131:1409-10.
  13. Mitchell RS, Ishimaru S, Ehrlich MP, Iwase T, Lauterjung L, Shimono T, et al. First International summit on thoracic aortic endografting; roundtable on thoracic aortic dissection as an indication for endografting. *J Endovasc Ther* 2002;9:98-105.
  14. Tinelli G, De Nigris F, Minelli F, Flore R, Santoliquido A, Tshomba Y. Endoanchors under 3D image fusion for a type IA endoleak after EVAR. *Clin Case Rep* 2019;7:529-32.
  15. Patelis N, Katsargyris A, Klonaris C. Endovascular repair of traumatic isthmic ruptures: special concerns. *Front Surg* 2017;4:32.
  16. Iannelli G, Piscione F, Di Tommaso L, Monaco M, Chiariello M, Spampinato N. Thoracic aortic emergencies: impact of endovascular surgery. *Ann Thorac Surg* 2004;77:591-6.

Submitted Jun 1, 2020; accepted Aug 27, 2020.