

## Review Article

# Post-COVID lung fibrosis: The tsunami that will follow the earthquake

Zarir F Udawadia<sup>1</sup>, Parvaiz A Koul<sup>2</sup>, Luca Richeldi<sup>3</sup>

<sup>1</sup>Hinduja Hospital and Research Center, Breach Candy Hospital, Mumbai, Maharashtra, India, <sup>2</sup>Department of Pulmonary Medicine, SKIMS, Srinagar, Jammu and Kashmir, India, <sup>3</sup>Department of Pulmonary Medicine, Fondazione Policlinico Universitario A. Gemelli, Rome, Italy

## ABSTRACT

The SARS-CoV-2 pandemic has already infected in excess of 50 million people worldwide and resulted in 1.2 million deaths. While the majority of those infected will not have long-term pulmonary sequelae, 5%–10% will develop severe COVID-19 pneumonia and acute respiratory distress syndrome (ARDS). The natural history of these severely affected patients is unclear at present, but using our knowledge of closely related coronavirus outbreaks like severe acute respiratory distress syndrome (SARS) and middle east respiratory syndrome (MERS), we would hypothesize that the majority will stabilize or improve over time although some patients will progress to advanced lung fibrosis or post-COVID interstitial lung disease (PC-ILD). Unlike the SARS and MERS outbreaks which affected only a few thousands, the sheer scale of the present pandemic suggests that physicians are likely to encounter large numbers of patients (potentially hundreds of thousands) with PC-ILD. In this review, we discuss the pathogenesis, natural history, and radiology of such patients and touch on clinical, laboratory, and radiographic clues at presentation which might help predict the future development of lung fibrosis. Finally, we discuss the responsible use of antifibrotic drugs such as pirfenidone, nintedanib, and some newer antifibrotics, still in the pipeline. The biological rationale of these drugs and the patient groups where they may have a plausible role will be discussed. We conclude by stressing the importance of careful longitudinal follow-up of multiple cohorts of post-COVID survivors with serial lung function and imaging. This will eventually help to determine the natural history, course, and response to therapy of these patients.

**KEY WORDS:** Antifibrotics, fibrosis, post-COVID sequelae, post-COVID fibrosis, post COVID ILD

**Address for correspondence:** Dr. Zarir F Udawadia, Hinduja Hospital and Research Center, Breach Candy Hospital, Mumbai, Maharashtra, India.  
E-mail: [zfu@hindujahospital.com](mailto:zfu@hindujahospital.com)

**Submitted:** 07-Oct-2020

**Revised:** 18-Oct-2020

**Accepted:** 25-Oct-2020

**Published:** 13-Nov-2020

*“One woe doth tread upon another’s heel, so fast they’ll follow”. William Shakespeare, Hamlet. Act 4, Scene 7.*

## INTRODUCTION

In the space of 7 short months, the SARS-COV-2 virus has acutely infected more than 50 million people and killed over 1.2 million. It has left in its wake, in severely

affected survivors, a trail of devastating pulmonary fibrosis which physicians will need to urgently address and manage. While fibrosis is a physiologic response to any pulmonary infection, chest physicians across the globe are encountering vast number of patients who have recovered from their acute COVID-19 pneumonia only to be left with severe residual lung fibrosis and oxygen dependence.

This is an open access journal, and articles are distributed under the terms of the Creative Commons Attribution-NonCommercial-ShareAlike 4.0 License, which allows others to remix, tweak, and build upon the work non-commercially, as long as appropriate credit is given and the new creations are licensed under the identical terms.

**For reprints contact:** [WKHLRPMedknow\\_reprints@wolterskluwer.com](mailto:WKHLRPMedknow_reprints@wolterskluwer.com)

**How to cite this article:** Udawadia ZF, Koul PA, Richeldi L. Post-COVID lung fibrosis: The tsunami that will follow the earthquake. Lung India 2021;38:S41-7.

Access this article online	
<b>Quick Response Code:</b> 	<b>Website:</b> <a href="http://www.lungindia.com">www.lungindia.com</a>
	<b>DOI:</b> <a href="https://doi.org/10.4103/lungindia.lungindia_818_20">10.4103/lungindia.lungindia_818_20</a>

This review attempts to draw attention to the problem of post-COVID-19 interstitial lung disease (PC-ILD), a condition likely to be ever-more frequently encountered as this virus continues its relentless march across the globe.

### PATHOGENIC MECHANISMS

Any infection, bacterial or viral, has the potential to cause airway epithelial injury and apoptosis and both have the capacity to modulate the host response to injury. Extensive information supporting a clear correlation between respiratory viral infections and the development of pulmonary fibrosis exists.

The mechanism of postviral lung fibrosis has been extensively studied in other related viral epidemics like influenza and SARS, and a knowledge of the past might educate us as we head into an unknown future. Looking first at severe H1N1, a study from China of 16 patients hospitalized with pneumonia caused by the 2009 H1N1 influenza showed high levels of transforming growth factor-beta 1 (TGF-β1).<sup>[1]</sup> This cytokine is known to induce fibrosis by various mechanisms which include increased deposition of extracellular matrix proteins, stimulation of fibroblast chemotactic migration, and fibroblast to myofibroblast transition.

Animal studies by Jolly *et al.*<sup>[2]</sup> using a mouse model showed that the influenza virus stimulates toll-like receptor 3, which activates TGF-β1 in the lungs, resulting in augmented levels of collagen deposition. In their experiments, they were able to demonstrate large increases in collagen 1, 111, 1V, and V1, as early as 5 days postinfluenza infection.

In the earlier SARS-CoV-1 outbreak in 2002, high levels of TGF-β1 were also observed in serum, bronchial epithelial cells, and alveolar epithelial cells.<sup>[3]</sup>

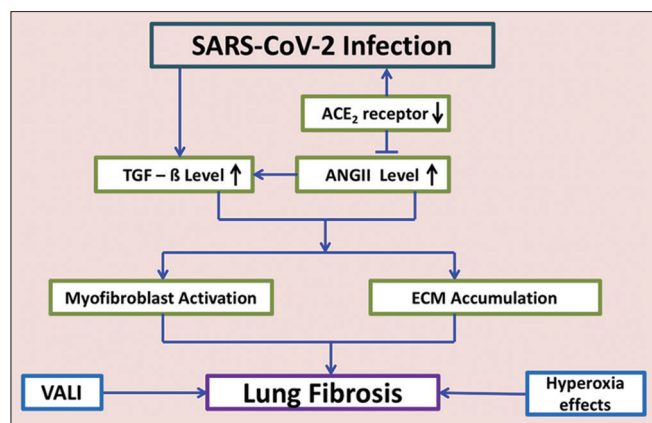
In the current SARS-CoV-2 pandemic, the molecular basis of progression to pulmonary fibrosis and PC-ILD is still unclear but is believed to be multifactorial [Figure 1].

Direct viral effects, the upregulating effect of the virus on cytokines like TGF-β1, and increased oxidative stress have all been postulated.<sup>[4]</sup> The role of the renin-angiotensin system has also been looked at with great interest as the high-affinity binding between the SARS-CoV-2 viral spike protein and the angiotensin-converting enzyme-2 (ACE-2) receptor has been shown to downregulate the level of the ACE2 receptor.<sup>[5]</sup> ACE-2 is believed to have a protective role in lung fibrosis. The decreased ACE-2 expression, in turn, leads to high angiotensin 2 (ANG II) levels. ANG II is a potent vasoconstrictive peptide directly involved in the development of inflammation and fibrosis. In addition to its role in regulating blood pressure, ANG II plays a pivotal role in the fibrotic process signaling cellular and molecular events that lead to the development of aberrant wound healing and pulmonary fibrosis. These include (i) production of pro-inflammatory cytokines such as interleukin-6 (IL-6) and IL-8, (ii) production of reactive oxygen species among infected alveolar cells, and (iii) activation of TGF-β 1 which, in turn, leads to proliferation, migration, and differentiation of fibroblasts to myofibroblasts with resultant deposition of collagen and fibronectin [Figure 1].

Two iatrogenic factors potentially contributing to the fibrosis encountered in survivors of severe COVID-19 pneumonia are oxygen toxicity and ventilator-induced lung injury (VILI). Patients who develop post-COVID fibrosis are invariably those who are more sick, have extensive, bilateral involvement initially, and hence are more likely to have required high concentrations of oxygen, often for prolonged periods of time during the acute stage of their illness. Extended exposure to high concentrations of oxygen is known to result in heightened production of oxygen-derived free radicals which can damage the pulmonary epithelium.<sup>[6]</sup> The sickest patients with acute respiratory distress syndrome (ARDS) from COVID-19 pneumonia are also more likely to have required prolonged mechanical ventilation, often with generation of high plateau pressures in attempts to ventilate their stiff, noncompliant lungs. The role of mechanical stress as an inciting factor for lung injury is also well recognized and it is likely that VILI may also be contributing to the pulmonary fibrosis encountered in these patients.<sup>[7]</sup>

### THE NATURAL HISTORY OF POST-COVID INTERSTITIAL LUNG DISEASE

More than 50 million people have already been infected by SARS CoV 2 globally. While the vast majority have mild or moderate infections, about 10% will develop severe COVID-19 pneumonia and 5% will develop ARDS, leaving a few million with significant pulmonary involvement. While the majority will resolve without residual lung damage, it is likely that a sizeable number will be left with residual fibrotic sequelae. It is known that a substantial proportion (about 25%) of patients who developed ARDS in the pre-COVID era, irrespective of etiology, experienced



**Figure 1:** Postulated mechanism of SARS-CoV-2 induced fibrosis stressing the pivotal role of Angiotensin 2

residual and long-term impairment of their pulmonary function, with radiographic evidence of pulmonary fibrosis on computed tomography (CT).<sup>[6]</sup> If we focus again, specifically on other influenza pneumonias, H1N1 is only occasionally complicated by fibrosis,<sup>[9]</sup> whereas as many as 22% of patients with H7N9 pneumonia<sup>[10]</sup> were left with fibrosis at 6 months. There is even more limited data from other coronavirus infections such as SARS and Middle East respiratory syndrome (MERS). In both disease outbreaks, fibrosis was relatively rare. A study by Chang *et al.*<sup>[11]</sup> in patients with SARS showed that when a second CT scan was repeated 4–6 months after the initial scan in patients with these two viral pneumonias, the parenchymal bands, traction bronchiectasis, and even honeycombing had regressed in significant numbers. Although progressive fibrosis was reported in some survivors, it was rare. The only long-term longitudinal data on MERS come from a study by Zhang *et al.* which followed up 81 health-care workers with MERS from Beijing Peoples Hospital for a period of 15 years.<sup>[12]</sup> They found that only 5% of patients had residual interstitial fibrosis at 15 years. At serial follow-up, changes regressed over the initial 2 years in most patients and then seemed to stabilize. However, COVID-19 is different from these other coronaviruses, mainly because of the scale of the pandemic and the huge numbers affected. Despite steroids now being the standard of care in most severely ill hospitalized COVID-19 patients, the usual doses most receive do not seem sufficient to prevent some of them being left with residual lung shadows. Follow-up data on survivors of SARS-CoV-2 infection are just beginning to emerge. A study of Italian COVID-19 pandemic survivors found that as many as 45% still complained of dyspnea at a follow-up visit conducted a mean of 60 days (SD, 13.6) after the initial onset of this symptom. A follow-up study by Zhao *et al.*<sup>[13]</sup> of pulmonary function and radiology in 55 COVID-19 survivors 3 months after recovery showed that 71% had residual CT abnormalities, including evidence of interstitial thickening in 27%. Abnormal lung function (i.e., reduced diffusion capacity, restrictive abnormalities, and small airways obstruction) has also been identified at the time of discharge from the hospital and 2 weeks after discharge.<sup>[14–17]</sup> In discharged survivors with COVID-19, impairment of diffusion capacity was seen in up to 47% cases, being the most common abnormality of lung function followed by restrictive ventilatory defects, seen in about 25% of cases, the pulmonary function abnormalities being worse in those with severe acute disease. Importantly TLco/alveolar volume (Kco) was found to be significantly lower in severe disease compared to those with mild-to-moderate disease, implying a degree of pulmonary vasculopathy.<sup>[15]</sup>

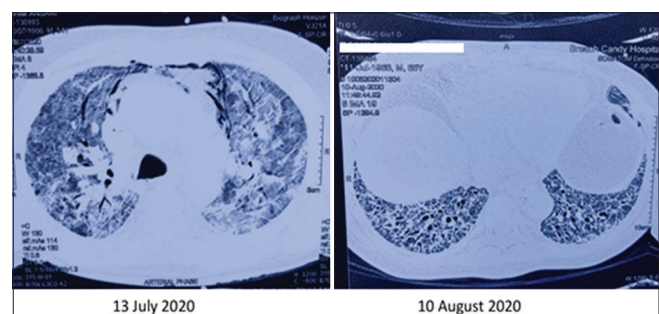
Mention must be made of a prospective, multicenter, observational study of 86 severe SARS-CoV-2 survivors already under careful follow-up in Austria to evaluate the extent of cardiopulmonary damage. The preliminary prepublication findings reported at the European Respiratory Society (ERS) meeting this year<sup>[16]</sup> found that the majority of patients were left with persisting

dyspnea (37%), reduction in diffusion capacity (28%), and CT abnormalities (88%) at 6-week postdischarge. While data from the 24-week follow-up is keenly awaited, at 12 weeks, the CT abnormalities had dropped to 56%, from 8 points on the 6-week CT scans to 4 points on the 12-week scans. Reassuringly, the authors report that progressive pulmonary fibrosis was not encountered in any of their patients. There was also an improvement in lung function from 6- to 12-week follow-up. By contrast, we have been struck with the speed of progression to PC-ILD in several of our patients. Figure 2 demonstrates a 45-year-old nonsmoker at one of our intensive care units (ICUs) with severe COVID-19 ARDS, who progressed within a period of 28 days to end-stage fibrotic lung disease, despite receiving remdesivir, tocilizumab, dexamethasone, and even 500 mg pulses of methylprednisolone [Figure 2].

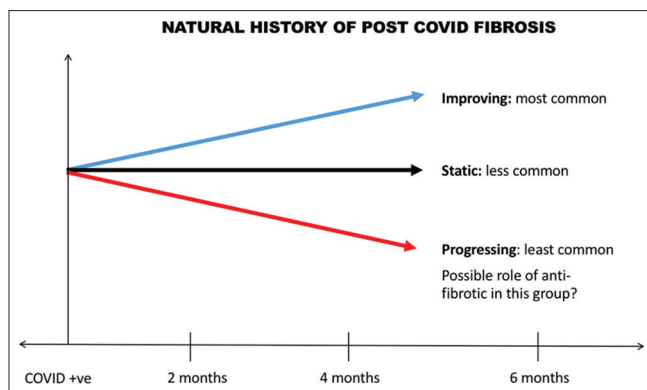
In keeping with our observations, a retrospective analysis with follow-up imaging after a median of 11.6 days in 42 COVID-19 survivors by Xiong *et al.*<sup>[19]</sup> showed evidence of progression in 83% with progressive opacifications, interstitial thickening, and fibrous strips being noted. The severity of opacifications assessed on initial CT was significantly related to progression on follow-up CT ( $P = 0.001$ ). A recent autopsy study by Schwensen *et al.*<sup>[20]</sup> was the first to document findings of widespread pulmonary fibrosis, including large areas of disrupted architecture with fibromuscular organization and collagenized fibrosis. Honeycombing and remodeling akin to that encountered in IPF were also seen.

It is too early in the course of the pandemic to be sure what the natural history of post-COVID fibrosis is likely to be. Follow-up of cohorts of post-COVID survivors are already underway at several centers and the pivotal question is: Are the changes so frequently seen on CT scan likely to (1) persist, (2) gradually improve, or (3) even worsen with the passage of time? This has implications not only for patient prognosis but also for treatment. Antifibrotics may have an important role in those who progress but less if any role in the first two scenarios, as we shall discuss [Figure 3].

Radiological manifestations such as fibrotic abnormalities of the lung have been detected as early as 3 weeks after the onset of symptoms regardless of the severity of the acute



**Figure 2:** Rapid progression of COVID-19 to end-stage post-COVID interstitial lung disease in <30 days



**Figure 3:** The natural history of post-COVID lung fibrosis is unclear with one of three possible courses. Antifibrotic may have a rationale in those who progress

illness.<sup>[21-23]</sup> In fatal cases of COVID-19, organizing diffuse alveolar damage (DAD) is the pathological hallmark with pulmonary fibrosis of varying severity.<sup>[24]</sup> Pertinently, many patients with COVID-19 develop ARDS and progressive pulmonary fibrosis may be contributing to mortality in a substantial proportion of these patients.<sup>[25]</sup>

Radiologic imaging findings in COVID-19 pneumonia include ground-glass opacities (GGOs) with or without consolidation, crazy-paving pattern, interstitial thickening, and parenchymal bands which are mainly bilateral with a predilection for the peripheries of the lower lobes.<sup>[17,21,22]</sup> Similar to other inflammatory pneumonitis, foci of edema, organizing pneumonia, and DAD are observed. In a recent study comparing CT imaging, interstitial thickening, air bronchogram, irregular interface, coarse reticular pattern, parenchymal bands, and pleural effusion were seen more commonly in the fibrosis group compared to those where the fibrosis did not persist.

It has therefore been speculated that interstitial thickening, irregular interface, coarse reticular pattern, and parenchymal bands manifesting in the course of the disease might be predictors of pulmonary fibrosis in these patients.<sup>[17,26]</sup> Rapid progression to honeycombing, though rare, has also been reported.<sup>[27,28]</sup> Long-term follow-up will be needed to determine whether the reticulation represents irreversible fibrosis.<sup>[20,29]</sup> The extent of reticulation on CT correlates with the quality of life (QOL), restrictive pattern on pulmonary function test (PFT) and a reduced diffusion capacity. However, even a relatively small degree of residual fibrosis could result in considerable morbidity and mortality in older patients who suffer from COVID-19, many of whom are elderly and may already have lung disorders.<sup>[21,30]</sup>

### PREDICTORS OF POST-COVID INTERSTITIAL LUNG DISEASE AND FIBROSIS

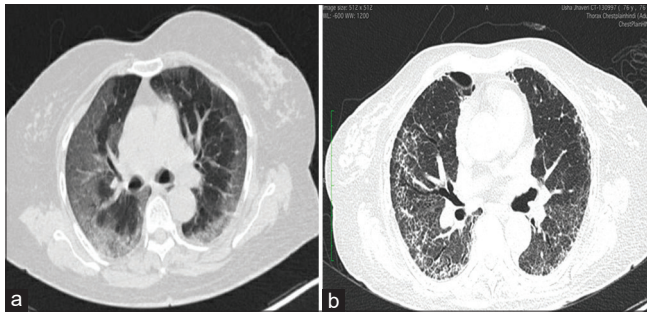
As data regarding post-COVID fibrosis emerge, a number of predictors have been putatively identified. These have

included advanced age, severe illness, prolonged ICU/hospital stay and mechanical ventilation, a history of smoking, and chronic alcoholism.<sup>[17,31]</sup> The severity of the lung injury and the inflammatory response are known to correlate with the extent of fibroblastic response required to repair the injury.<sup>[32]</sup> Higher levels of CRP and IL-6 during illness might lead to the formation of fibrosis during recovery.<sup>[17]</sup> High LDH levels during acute illness were also found to significantly correlate with the risk of pulmonary fibrosis following other coronavirus infections like MERS-CoV infection<sup>[33]</sup> and SARS.<sup>[34]</sup> Patients with COVID-19 who developed PC-ILD had also received pulsed steroid therapy and antivirals for more prolonged periods of time compared to the nonfibrosis group, suggesting that those who develop fibrosis after discharge generally have more serious disease during hospitalization.<sup>[17]</sup>

It is too soon to determine which patients with COVID-19 are at greatest risk for developing long-term pulmonary abnormalities and if such sequelae will resolve, improve, or become permanent, and how the pulmonary abnormalities might be affected by therapeutics. Those with a history of moderate or severe disease, with persisting symptoms or with radiological abnormalities, require clinical review and further investigation. An accurate biomarker that would predict which patients with COVID-19 infection are likely to progress to fibrosis would be invaluable.

### TREATMENT OF POST-COVID FIBROSIS

1. Steroids: Most patients who develop PC-ILD are hypoxic, and after the results of the RECOVERY trial<sup>[35]</sup> were announced on June 16, steroids became the standard of care in hypoxic patients in ICUs across the world. We would like to stress that the doses of steroids recommended in COVID-19, in the acute stage, were modest doses of 4–6 mg dexamethasone for no more than 10 days. Despite most patients currently receiving steroids in equivalent or higher doses, steroids alone do not seem to be sufficient to prevent the development of fibrosis. There are initial reports of patients with COVID-19 pneumonia going on to develop well-marked PC-ILD and fibrosis despite being on moderately high doses of steroids through their illness [Figure 4].<sup>[27]</sup> Steroids should, in our opinion, be continued on discharge if the CT scan prior to discharge continues to show significant GGOs and the patient remains hypoxic. At this stage again, we would caution against the use of large doses of oral steroids as they could worsen hyperglycemia and contribute to proximal myopathy which in turn would retard the patients' mobility and rehabilitation. We recommend using no more than 20–30 mg of prednisolone at discharge and tapering it on follow-up depending on the patient's response
2. Role of antifibrotic agents: The role of antifibrotic drugs in the prevention and treatment of post-COVID fibrosis is unclear at present. There is, however, a clear



**Figure 4:** (a) Initial computed tomography chest of a 60-year-old lady admitted in the intensive care unit showing bilateral ground-glass opacities. (b) Within 3 months of COVID-19 pneumonia, the patient developed fibrosis with traction bronchiectasis and honeycombing despite being on steroids through most of her hospital stay

rationale for their potential usefulness.<sup>[8]</sup> Both COVID and IPF share many common demographic factors, disproportionately affecting males, the elderly, and smokers. These drugs are also believed to be useful in patients with acute exacerbations of ILD (both IPF and other fibrotic ILDs). Finally, fibrosis with fibroblasts and honeycombing has clearly been demonstrated in autopsies and explanted lungs of patients with SARS-CoV-2. For all these reasons, it is reasonable to assume that antifibrotic drugs may have a potentially valuable role in this setting

The choice of which drug should be used is less clear. There is a sound biological rationale for the use of both perfenidone and nintedanib in COVID-ILD. These two agents, established to be useful in IPF and other progressive fibrotic ILDs, are known to inhibit experimental lung injury and inhibit IL-6, IL-1, and IL-1B. It is worth noting that both these antifibrotic drugs take at least 1–3 months to demonstrate an effect. This was the time period at which the FVC started to improve compared to placebo in the INBUILD, INPULSIS, and ASCEND trials.<sup>[36–38]</sup> Thus, adding them at a late stage in patients already needing ventilator support may not be ideal. We would recommend any antifibrotic drug be used responsibly, carefully monitored for toxicities in this critically ill patient population and ideally within the context of trials. We propose that they be reserved for certain groups of patients with COVID-19. Since it is patients with the most severe ARDS that are most likely to end up with fibrosis, this might be the group to consider their use in. Such patients will generally require prolonged ventilation with high oxygen requirements, and perhaps antifibrotics along with steroids (that have already become the standard of care) might have a role in preventing or retarding the fibrosis that many of these patients will develop.

A biomarker to identify which of these patients will proceed to develop fibrosis would indeed be invaluable, but till one emerges, CT scan evidence of fibrosis with traction bronchiectasis and/or honeycombing would be useful to identify which patients would potentially benefit

from antifibrotics. We would also argue that antifibrotics should be reserved for those post-COVID patients who demonstrate evidence of progression. Giving these drugs to those who are spontaneously improving over time or whose fibrosis is static is unlikely to be useful. Of course, progression is difficult to ascertain when the patient is first seen and is only apparent over time, making the correct identification of the subset of patients most likely to benefit from antifibrotic therapy a difficult task [Figure 3].

3. Combination therapy: We would suggest that there is a rationale for using antifibrotics in combination with anti-inflammatory drugs like steroids, so both inflammatory and fibrotic limbs of the cascade are addressed.
4. Novel agents: Considering the scale and impact of the pandemic, there is an urgent need to also evaluate newer, experimental drugs which have biological rationale and potentially inhibit viral replication. George *et al.*<sup>[8]</sup> propose some potential candidates known to have an impact on the TGF- $\beta$  pathway and virus-induced lung injury and are presently in the developmental stage. These include BG00011 (Biogen), PLN-74809 (Pliant Therapeutics), and TD-139 (Galacto biotech). Recent network analysis suggests that rapamycin could be a useful repurposed drug as mTOR is a potential anti-SARS-CoV-2 target. These drugs are all at early stages of development, and till their safety and efficacy is established, the available antifibrotic drugs are those that will continue to be most widely used. Thus, the role of antifibrotics in post-COVID ILD remains unclear, with more questions than answers being raised. There is an urgent need for the pulmonary community to set into motion-controlled trials with currently available or investigational antifibrotic drugs in an attempt to answer some of these questions.
5. Oxygen support at home is needed for many patients with PC-ILD and this should be provided via oxygen concentrator with patients being instructed to keep monitoring their saturations at rest and after exertion.
6. Pulmonary rehabilitation, in our opinion, is also of vital importance and must be commenced as soon as the patient is shifted out of the ICU and continued at home.<sup>[39]</sup>
7. Anticoagulation: Patients with PC-ILD continue to be at high risk for clotting complications after discharge. Even a minor pulmonary embolism at this stage in a hypoxic patient would be a major setback. They are not yet fully mobile because of muscle wasting and breathlessness and should be continued on anticoagulants for a few weeks or months post discharge until their mobility improves.
8. Vaccination: All patients should receive vaccinations against influenza and pneumonia prior to or soon after discharge. Seasonal influenza remains a major cause of morbidity and mortality and patients who have just recovered from SARS-CoV-2 are a weak and vulnerable population. Co-infections with both viruses are already being reported.<sup>[40]</sup>

9. Lung transplantation: There are already reports of lung transplantation being successfully offered to patients with severe PC-ILD though this is not practical, and at present can only be offered to very select numbers of patients with COVID-19-related ARDS.<sup>[41]</sup>

## FOLLOW-UP OF POST-COVID INTERSTITIAL LUNG DISEASE SURVIVORS

Accurate longitudinal studies with serial imaging and PFT are the only way to answer the pivotal question of the natural course of post-COVID ILD. Raghu *et al.*<sup>[42]</sup> have proposed a schema for the follow-up of these post-COVID survivors with which we concur. An initial baseline visit should be established once the patient is polymerase chain reaction negative with a baseline noncontrast high-resolution CT scan (HRCT), PFTs (spirometry, lung volumes, and diffusion capacity), 6-min walk test, and assessment of QOL with standard questionnaires recorded. Thereafter, to better understand the natural course of the disease, they suggest follow-up visits, either remotely or in person at frequent visits up to a total duration of 36 months, based on the degree and extent of lung involvement. While the kind of detailed follow-up they recommend is beyond the scope of many in resource-strapped countries, we would suggest that 6 monthly lung function, walk tests, QOL questionnaires, and annual HRCT should be done for all patients till clinical, physiological, and radiological stability has been documented. It is only through meticulous follow-up of multiple cohorts which include large number of patients that the natural history, course, and response to therapy of this disease will be elucidated.

### Declaration of patient consent

The authors certify that they have obtained all appropriate patient consent forms. In the form the patient(s) has/have given his/her/their consent for his/her/their images and other clinical information to be reported in the journal. The patients understand that their names and initials will not be published and due efforts will be made to conceal their identity, but anonymity cannot be guaranteed.

### Financial support and sponsorship

Nil.

### Conflicts of interest

There are no conflicts of interest.

## REFERENCES

1. Wen Y, Deng BC, Zhou Y, Wang Y, Cui W, Wang W, *et al.* Immunological features in patients with pneumonitis due to influenza A H1N1 infection. *J Invest Allergol Clin Immunol* 2011;21:44-50.
2. Jolly L, Stavrou A, Vanderstoken G, Meliopoulos VA, Habgood A, Tatler AL, *et al.* Influenza promotes collagen deposition via  $\alpha v \beta 6$  integrin-mediated transforming growth factor  $\beta$  activation. *Biol Chem* 2014;289:35246-63.
3. Baas T, Taubenberger JK, Chong PY, Chui P, Katze MG. SARS-CoV virus-host interactions and comparative etiologies of acute respiratory distress syndrome as determined by transcriptional and cytokine profiling of formalin-fixed paraffin-embedded tissues. *J Interf Cytokine Res* 2006;26:309-17.
4. Xu J, Xu X, Jiang L, Dua K, Hansbro PM, Liu G. SARS-CoV-2 induces transcriptional signatures in human lung epithelial cells that promote lung fibrosis. *Respir Res* 2020;21:182.
5. Delpino MV, Quarleri J. SARS-CoV-2 Pathogenesis: Imbalance in the renin-angiotensin system favors lung fibrosis. *Front Cell Infect Microbiol* 2020;10:340.
6. Mach WJ, Thimmesch AR, Pierce JT, Pierce JD. Consequences of hyperoxia and the toxicity of oxygen in the lung. *Nurs Res Pract* 2011;2011:1-7.
7. Albert RK, Smith B, Perlman CE, Schwartz DA. Is progression of pulmonary fibrosis due to ventilation-induced lung injury? *Am J Resp Critical Care Med Am Thoracic Soc* 2019;200:140-51.
8. George PM, Wells AU, Jenkins RG. Pulmonary fibrosis and COVID-19: The potential role for antifibrotic therapy. *Lancet Resp Med* 2020;8:807-15.
9. Singh N, Singh S, Sharma B, Singh V. Swine flu fibrosis: Regressive or progressive? *Lung India* 2016;33:219.
10. Wang Q, Jiang H, Xie Y, Zhang T, Liu S, Wu S, *et al.* Long-term clinical prognosis of human infections with avian influenza A (H7N9) viruses in China after hospitalization. *EClinicalMedicine* 2020;20:100282.
11. Chang YC, Yu CJ, Chang SC, Galvin JR, Liu HM, Hsiao CH, *et al.* Pulmonary sequelae in convalescent patients after severe acute respiratory syndrome: Evaluation with thin-section CT. *Radiology* 2005;236:1067-75.
12. Zhang P, Li J, Liu H, Han N, Ju J, Kou Y, *et al.* Long-term bone and lung consequences associated with hospital-acquired severe acute respiratory syndrome: A 15-year follow-up from a prospective cohort study. *Bone Res* 2020;8:8.
13. Zhao YM, Shang YM, Song WB, Li QQ, Xie H, Xu QF, *et al.* Follow-up study of the pulmonary function and related physiological characteristics of COVID-19 survivors three months after recovery. *EClinicalMedicine* 2020;25:100463.
14. Arnold DT, Hamilton FW, Milne A, Morley A, Viner J, Attwood M, *et al.* Patient outcomes after hospitalisation with COVID-19 and implications for follow-up; results from a prospective UK cohort. *medRxiv*. 2020 <https://doi.org/10.1101/2020.08.12.20173526>.
15. Mo X, Jian W, Su Z, Chen M, Peng H, Peng P, *et al.* Abnormal pulmonary function in COVID-19 patients at time of hospital discharge Vol. 55, *European Respiratory Journal*. European Respiratory Society; 2020.
16. Lv D, Chen X, Wang X, Mao L, Sun J, Wu G, *et al.* Pulmonary function of patients with 2019 novel coronavirus induced-pneumonia: a retrospective cohort study. *Ann Palliat Med* 2020;9:3447-52.
17. Yu M, Liu Y, Xu D, Zhang R, Lan L, Xu H. Prediction of the development of pulmonary fibrosis using serial thin-section CT and clinical features in patients discharged after treatment for COVID-19 pneumonia. *Korean J Radiol* 2020;21:746-55.
18. Persistent Lung Damage Improves Gradually After COVID-19. Available from: <https://www.medscape.com/viewarticle/937263>. [Last accessed on 2020 Oct 20].
19. Xiong Y, Sun D, Liu Y, Fan Y, Zhao L, Li X, *et al.* Clinical and high-resolution CT features of the COVID-19 infection. *Invest Radiol* 2020;55:332-9.
20. Schwensen HF, Borreschmidt LK, Storgaard M, Redsted S, Christensen S, Madsen LB. Fatal pulmonary fibrosis: A post-COVID-19 autopsy case. *J Clin Pathol* . 2020 Jul 28 ;0:1-3.
21. Wei J, Yang H, Lei P, Fan B, Qiu Y, Zeng B, *et al.* Analysis of thin-section CT in patients with coronavirus disease (COVID-19) after hospital discharge. *J Xray Sci Technol* 2020;28:383-9.
22. Li X, Zeng W, Li X, Chen H, Shi L, Li X, *et al.* CT imaging changes of corona virus disease 2019 (COVID-19): A multi-center study in Southwest China. *Transl Med* 2020;18:154.
23. Ahmed H, Patel K, Greenwood D, Halpin S, Lewthwaite P, Salawu A, *et al.* Long-term clinical outcomes in survivors of coronavirus outbreaks after hospitalisation or icu admission: A systematic review and meta-analysis of follow-up studies. *medRxiv* . 2020 Apr 22 ;2020.04.16.20067975. Available from: <https://doi.org/10.1101/2020.04.16.20067975>.
24. British Thoracic Society. British Thoracic Society Guidance on Respiratory Follow Up of Patients with a Clinico-Radiological Diagnosis of COVID-19 Pneumonia. *Br Thorac Soc*. 2020;(May). Available from: <https://www.brit-thoracic.org.uk/document-library/quality-improvement/covid-19/resp-follow-up-guidance-post-covid-pneumonia/>.

Udwadia, *et al.*: Post COVID-ILD

25. Schaller T, Hirschtbühl K, Burkhardt K, Braun G, Trepel M, Märkl B, *et al.* Postmortem examination of patients with COVID-19. *JAMA* 2020;323:2518.
26. Ward PA, Hunninghake GW. Lung inflammation and fibrosis. *Am J Respir Crit Care Med* 1998;157:S123-9.
27. Udwadia ZF, Pokhariyal PK, Tripathi AK, Kohli A. Fibrotic interstitial lung disease occurring as sequelae of COVID-19 pneumonia despite concomitant steroids. *Lung India* 2021;38:S61-3.
28. Kayhan S, Kocakoç E. Pulmonary fibrosis due to COVID-19 pneumonia. *Korean J Radiol* 2020;21:1273.
29. Hu Q, Guan H, Sun Z, Huang L, Chen C, Ai T, *et al.* Early CT features and temporal lung changes in COVID-19 pneumonia in Wuhan, China. *Eur J Radiol* 2020;128:109017.
30. Spagnolo P, Balestro E, Aliberti S, Cocconcelli E, Biondini D, Casa G Della, *et al.* Pulmonary fibrosis secondary to COVID-19: A call to arms? *Lancet Resp Med*; 2020;8:750-2.
31. Ojo AS, Balogun SA, Williams OT, Ojo OS. Pulmonary fibrosis in COVID-19 survivors: Predictive factors and risk reduction strategies. *Pulm Med* 2020;2020:6175964.
32. Wallace WA, Fitch PM, Simpson AJ, Howie SE. Inflammation-associated remodelling and fibrosis in the lung A process and an end point. *Int J Exp Pathol* 2007;88:103-10.
33. Das K, Lee E, Singh R, Enani M, Al Dossari K, van Gorkom K, *et al.* Follow-up chest radiographic findings in patients with MERS-CoV after recovery. *Indian J Radiol Imag* 2017;27:342.
34. Wong KT, Antonio GE, Hui DS, Ho C, Chan PN, Ng WH, *et al.* Severe acute respiratory syndrome: Thin-section computed tomography features, temporal changes, and clinoradiologic correlation during the convalescent period. *Comput Assist Tomogr* 2004;28:790-5.
35. Low-cost Dexamethasone Reduces Death by up to one Third in Hospitalised Patients with Severe Respiratory Complications of COVID-19 — RECOVERY Trial. Available from: <https://www.recoverytrial.net/news/low-cost-dexamethasone-reduces-death-by-up-to-one-third-in-hospitalised-patients-with-severe-respiratory-complications-of-covid-19>. [Last accessed on 2020 Oct 20].
36. Flaherty KR, Wells AU, Cottin V, Devaraj A, Walsh SLF, Inoue Y, *et al.* Nintedanib in progressive fibrosing interstitial lung diseases. *N Engl J Med* 2019;381:1718-27.
37. Richeldi L, du Bois RM, Raghu G, Azuma A, Brown KK, Costabel U, *et al.* Efficacy and safety of nintedanib in idiopathic pulmonary fibrosis. *N Engl J Med* 2014;370:2071-82.
38. King TE, Bradford WZ, Castro-Bernardini S, Fagan EA, Glaspole J, Glassberg MK, *et al.* A phase 3 trial of pirfenidone in patients with idiopathic pulmonary fibrosis. *N Engl J Med* 2014;370:2083-92.
39. Polastri M, Nava S, Clini E, Vitacca M, Gosselink R. COVID-19 and pulmonary rehabilitation: Preparing for phase three. *Eur Respir J* 2020;55.
40. Ma S, Lai X, Chen Z, Tu S, Qin K. Clinical characteristics of critically ill patients co-infected with SARS-CoV-2 and the influenza virus in Wuhan, China. *Int J Infect Dis* 2020;96:683-7.
41. Lang C, Jaksch P, Hoda MA, Lang G, Staudinger T, Tschernko E, *et al.* Lung transplantation for COVID-19-associated acute respiratory distress syndrome in a PCR-positive patient. *Lancet Respir Med* 2020;8:1057-60.
42. Raghu G, Wilson KC. COVID-19 interstitial pneumonia: monitoring the clinical course in survivors. *Lancet Respir Med* 2020;8:839-42.