

Extension block pinning vs single Kirshner wiring to treat bony mallet finger. A retrospective study.

Lorenzo Rocchi¹, Camillo Fulchignoni¹, Rocco De Vitis¹, Iakov Molayem², Daniele Caviglia¹

¹Hand Surgery and Orthopedics Unit, Department of Orthopaedics and Traumatology, Fondazione Policlinico Universitario A. Gemelli IRCCS, Rome Italy; ²Hand Surgery, Microsurgery and Upper Limb Unit – “Israelitico” Hospital of Rome, Italy.

Abstract. *Background and aim:* Bony Mallet Finger or Mallet Fracture is a common injury of the hand, which follows a forced flexion of the extended distal interphalangeal joint, that leads to a bony avulsion of the distal phalanx. Depending on fracture extension and dislocation, those lesions can either be treated conservatively or surgically. Several surgical options have been described in the literature. The aim of this study is to compare retrospectively two percutaneous pinning techniques: the extension block technique according to Ishiguro vs an original single Kirshner wiring (Umbrella technique). *Methods:* Between January 1998 and December 2019, among all patients treated surgically for a Mallet Fracture with either the Ishiguro' and the Umbrella technique, 98 have been included in this study. All patients have been assessed one year after surgery using the Crawford method. *Results:* With both techniques better results have been achieved in younger patients and for those treated early. The umbrella technique seems to have better results in patients with fracture classified as 2b or 2c (Wehbe and Schneider classification), whereas the Ishiguro technique seems more appropriate for patients with a 1b fracture. Complication rate and typology vary depending on the used technique. *Conclusions:* The Ishiguro' and the Umbrella technique both lead to good results for the treatment of surgical Mallet Fractures. The choice of the best type of pinning should mainly depend on fracture extension and time elapsed from trauma.

Key words: Bony mallet finger, Mallet Fracture, Ishiguro, Umbrella technique, pinning, distal interphalangeal joint.

Introduction

Bony Mallet Finger, otherwise known as Mallet Fracture (MF) is a very common injury of the hand, especially in those who practice hand sports (1-3), with a prevalence of 5.6% of all tendinous lesions in hand and wrist injuries⁴. The injury is the result of a forced flexion of the extended distal interphalangeal (DIP) joint (1,4,5) that leads to a bony avulsion of the distal phalanx with a consequent loss of the terminal extensor tendon kinematics (2). Most commonly involved fingers are the ulnar side's ones (middle, ring

and little finger) of the dominant hand, usually in young and middle-aged men (6).

The Wehbe and Schneider classification (WS) divides MF into 3 types and subdivides each type into 3 subtypes. In type 1 there is no subluxation, in type 2 subluxation is present and in type 3 the fracture includes the whole of the distal phalanx. Subtypes express the dimensions of the fracture fragment: A – the fragment size is less than one-third of the articular surface of the distal phalanx, B – the fragment size is between one-third and two-third of the articular surface, and C – the fragment size is greater than two-third (7). Up

to now one algorithm for treatment decision has been published in the literature suggesting conservative treatment in most of cases and reserving surgery for those patients in which subluxation cannot be reduced by splinting (8). The authors agree that a conservative treatment with extension splinting is usually resolute in case of small fragment and no subluxation of the DIP joint (5,9). In other cases, presenting volar DIP subluxation (10,11) and/or dorsal bony fragment bigger than 1/3 of the articular surface, a surgical management must be considered (5, 12-14).

Goal of surgical treatment is the joint's surface anatomical reduction to prevent joint step-off, poor interphalangeal motion and post-traumatic osteoarthritis, which can follow the splinting (12). Many surgical options have been developed over the time such as Kirschner (K-) wire fixation, tension band wiring (15), micro screws (16), pull-out wire fixation (17), hook plate (18), small external fixator (19), or extension-block fixation (20,21). The extension-block pinning (EBP) technique reported by Ishiguro is among the most popular treatment methods for MF. This is a simple and reproducible pinning technique, but it involves transfixion of the DIP joint for many weeks, associated to a dorsal oblique pinning (20). However, this treatment, usually considered trustworthy, may cause stiffness, chondral damage, osteoarthritis, bone fragment rotation, skin decubitus, and nail bed injury (12). On the other hand, a single K-wire fixation of the fracture could prevent almost all these complications, but is more challenging, and carries the risk of bone fragmentation (22).

Two of the main percutaneous treatments for MF, the EBP and the one k-wire "Umbrella Handle" (UH) technique, have been widely used in the last two decades in the Orthopedics & Hand Surgery Unit, Department of Orthopedics, Policlinico Universitario A. Gemelli, Rome, Italy. Authors considered useful to retrospectively compare two samples of patients treated with these percutaneous surgical techniques, to understand when and in which cases it is more useful to use one or the other method.

Materials and methods

This is a retrospective study approved by the local ethical committee, including patients operated

between January 1998 and December 2019. To be included in the study, cases had to meet the following inclusion criteria: a MF classified as Wehbe and Schneider 1b, 1c, 2b or 2c ; age ranging between 15 and 65 years old; time elapsed since trauma included between 1 day and 6 weeks; absence of systemic diseases such as rheumatoid arthritis, advanced arthrosis or diabetes. Cases presenting associated injuries were not included in the study. Patients with MF classified as types 1A and 2A were not included being the fragment too small for surgical fixation, as well as patients with MF type 3 for whom those percutaneous surgical treatments are not indicated (12).

Over two hundred patients were treated in this lapse of time, and ninety-eight patients who met the inclusion criteria were finally assessed over those twenty-two years.

All procedures were performed following written informed patient consent and in accordance with the ethical standards of the institutional and/or national research committee and the 1964 Declaration of Helsinki and its subsequent amendments or comparable ethical standards.

Operative techniques

Experienced senior hand surgeons performed all surgeries, choosing independently what they believed to be the more appropriate approach. Both techniques were performed under digital block anesthesia, and under fluoroscopy.

In the UH technique (22), the avulsed dorsal fragment is transfixed with an obliquely directed K-wire from proximal to distal into the fragment. In this technique authors usually use small (1 or 1.2mm) diameter K-wire in order to avoid the risk of bone fragmentation. The fracture is then reduced using the K-wire as a joystick. The distal phalanx is thus transfixed with the same K-wire, whose dorsal end is bent. This bent extremity of the K-wire, that looks like an "umbrella handle", is drawn down subcutaneously through a small dorsal skin incision to reduce the fracture by pulling on the K-wire with heavy pliers from the palmar aspect of the finger (Figs. 1 and 2). The K-wire is passed through a custom-made thermoplastic splint, made before surgery to distribute the pressure of pin fixation across the whole of the finger pulp,

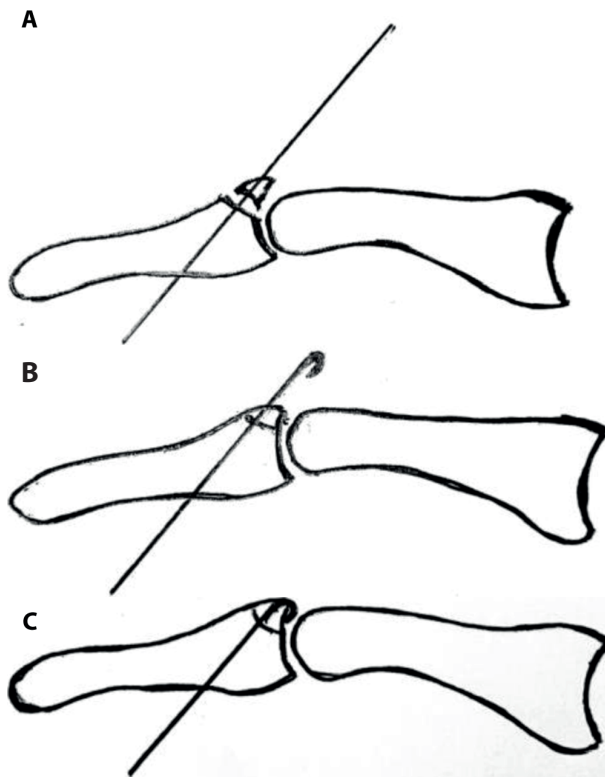


Figure 1. The Umbrella technique. K-wire is inserted dorsally (a) and pulled to reduce the fracture (b,c).

then pushed through a small piece of plastic cannula as an anchor, to prevent dorsal displacement (Fig. 2).

In the EPB technique (20), the surgeon flexes the distal phalanx and insert a small k-wire just on top of the bony fragment entering with a 30° angle on the dorsal margin, along the midline, of the articular surface of the middle phalanx head. The DIP joint is then brought back in full extension to obtain a reduction of the bony fragment (the K-wire acts like a roof that exerts a back pressure). The joint is then immobilized in extension with a second K-wire pinning from the fingertip, throughout the DIP joint, reaching the middle phalanx (Figs. 3 and 4).

Post-operatively, in both techniques, patients were asked to move immediately the involved finger. In the UH technique, the DIP, the proximal interphalangeal (PIP) joints and the metacarpophalangeal (MP) joint were allowed to move. In the EPB technique, only the PIP and the MP joints were free to articulate. The K-wires were removed between 4 and 6 weeks as x-rays showed signs of consolidation.

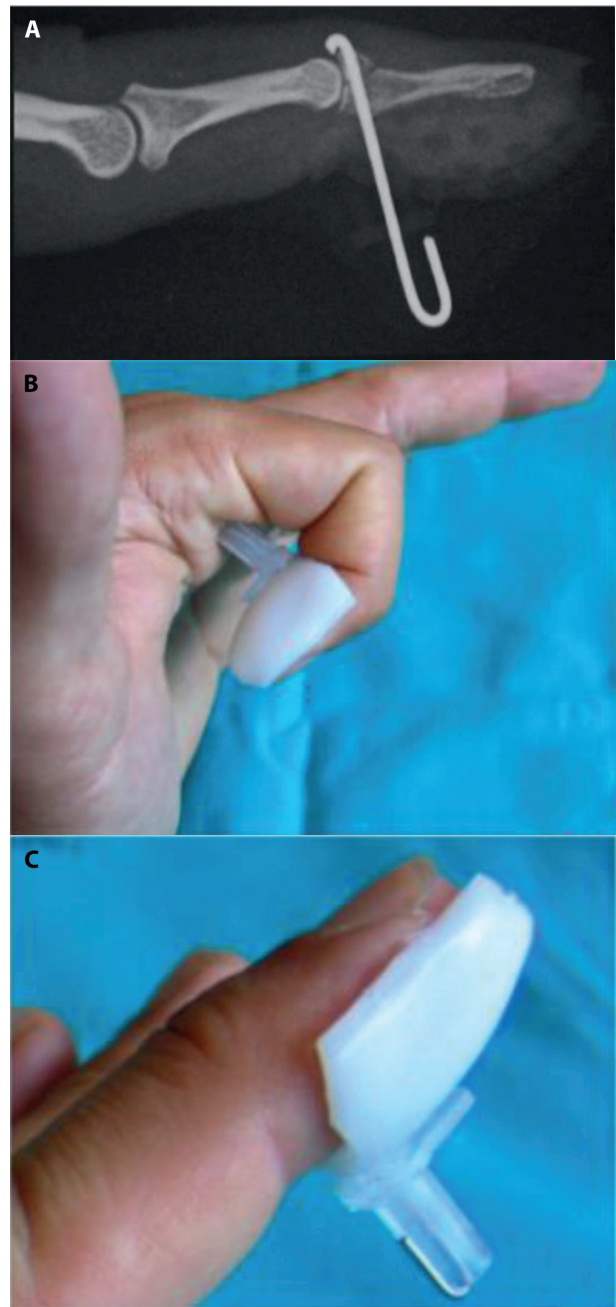


Figure 2. Post-operative radiography (a) and clinical picture (b) of a MF treated by the mean of the Umbrella technique, with the custom-made thermoplastic splint in place.

The patients

Overall, 98 patients were included in this study with a mean age of 41.6 years old (range 17-65). Twenty-five were female, and seventy-three were male. Mean time between trauma and surgery was

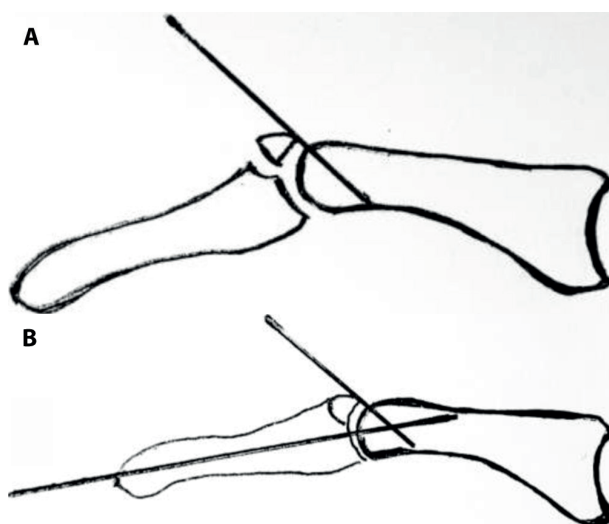


Figure 3. The EPB technique. The first K-wire inserted just on top of the bony fragment entering with a 30° angle on the dorsal margin (a), the DIP joint is then immobilized in extension with a second K-wire pinning from the fingertip (b).

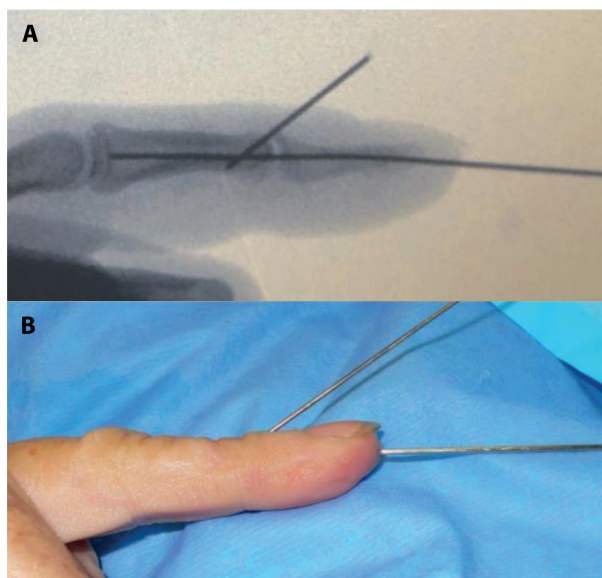


Figure 4. Post-operative radiography (a) and clinical picture (b) of a MF treated by the mean of the EPB technique.

Table 1. The patients

	Overall	Group A (UH)	Group B (EPB)
Number of patients	98	48	50
Female	25	17	8
Male	73	31	42
Mean age, in years (range)	41.6 (17-65)	42.0 (17-61)	41.0 (20-65)
Mean time between surgery and trauma, in days (range)	11.2 (2-37)	10.3 (2-26)	12.3 (2-37)
Type of MF - 1b	12	5	7
- 1c	6	2	4
- 2b	46	23	23
- 2c	34	18	16

11.2 days (range 2-37). Twelve patients were classified as Wehbe and Schneider 1b, six as 1c, forty-six as 2b and thirty-four as 2c. All patients treated with UH technique were selected as group A, whereas all patients treated with EPB technique were selected as group B (Table 1).

Follow-up

Patients were checked for follow-up at 1, 2, 4, 6 and 8 weeks. X-rays were taken immediately after surgery and at 4/6 weeks. Eight weeks after surgery,

Table 2. Crawford's criteria

Excellent	Full DIP joint extension, full flexion, no pain
Good	0° to 10° of extension deficit, full flexion, no pain
Fair	10° to 25° of extension deficit, any flexion loss, no pain
Poor	>25° of extension deficit or persistent pain

Crawford's method (23) (Table 2) was used to assess the results of the treatment by measuring the ranges of motion of the involved joints. At 6 and 12 months, the results were confirmed by a clinical check.

Statistical analysis

Continuous variables (age and time between trauma and surgery) are presented as means. The significance of differences between two means is assessed using the t-statistic calculated as part of the two-tailed *t*-student test with a confidence level $\alpha = 0,05$. Significance of evolution of bounded scores (Crawford's method) is assessed comparing their distributions (UH vs EPB) using a two-sided *chi-square* test with a confidence level $\alpha = 0,05$.

Results

Clinical and radiographic outcomes

At 8 weeks follow-up, among the 48 patients of group A, 11 had an excellent result considering Crawford criteria, 35 had a good result and 2 a fair result. Out of the 50 patients of group B, 11 had an excellent result, 30 had a good result, 6 had a fair result, and 3 had a poor result (Table 3).

Although not statically significant, better results seem to be obtained in WS 2b and 2c using UH technique, whereas better results were achieved in WS 1b for EPB technique (Table 3).

For both techniques the results improved, in a not statistically significant way ($p > 0,05$), as patients were younger; and improved in a statistically significant manner ($p < 0,05$) as patients were treated earlier (Table 4). Results were stable at 1 year follow-up.

Table 3. Results using Crawford's criteria

	Group A (UH)	Group B (EPB)
WS 1b	5 good	4 excellent, 3 good
WS 1c	1 excellent, 1 good	3 good, 1 fair
WS 2b	2 excellent, 19 good, 2 fair	4 excellent, 15 good, 2 fair, 2 poor
WS 2c	8 excellent, 10 good	3 excellent, 9 good, 3 fair, 1 poor
Total	11 excellent, 35 good, 2 fair	11 excellent, 30 good, 6 fair, 3 poor

Complications

Among patients of group A, four complications out of 48 cases (8%) were observed. A patient had a low-grade infection that led to early removal of the K-wire. This patient was then treated with a digital splint and achieved a "fair" result. In another case a fracture of the bone fragment was observed post-operatively and led to a "fair" clinical result. In two other cases a moderate dislocation of the bone fragment was observed after the hardware removal, however in those cases a "good" clinical result was achieved. No poor results, no case of nail deformity, of skin necrosis nor of osteomyelitis were recorded in this group.

Among patients of group B, nine complications out of 50 cases (18%) were observed. Four patients had a nail bed injury. Among those, two ended up having a "good" result, one had an associated dislocation leading to a "fair" result, and one had a concomitant skin infection with a "poor" result. In one case a moderate dislocation of the bone fragment was observed after the hardware removal achieving a "fair" result. Four other patients treated with EPB had a stiff digit, achieving in two cases a "fair" result and in one case a "poor" result. Both patients with "poor" results were treated more than one month after their trauma. No skin necrosis nor osteomyelitis were recorded.

Table 4. Results considering age and time between trauma and surgery

	Group A (UH)	Group B (EPB)
Mean age, in years		
Excellent	33.8	36.0
Good	40.6	41.7
Fair	42.0	42.5
Poor	none	42.0
Mean time between surgery and trauma, in days		
Excellent	6.6	7.4
Good	10.9	9.7
Fair	19.5	25.5
Poor	none	35.0

Discussion

The Bony Mallet Finger is a very common injury of the hand, frequently observed in clinical practice. Its treatment can be conservative, but in case of displaced fracture and/or with a dorsal bony fragment bigger than 1/3 of the articular surface the surgical management should be always considered. Many surgical options have been developed over the time, ranging from various Kirshner wire methods of fixation, to open reduction and internal fixation with screws or mini plate (15-20). Among them the percutaneous techniques are, in our opinion, preferable considering the small size of the skeletal fragment and the reduced thickness of the skin in this finger's dorsal district. Between the percutaneous techniques, the extension-block pinning, originally reported by Ishiguro et al.²⁰, is certainly the most diffused method of treatment. For this reason, in our Hand Surgery Unit, it has been used for many years. Concomitantly, we have developed over the years the UH technique with the goal of another easy-to-reproduce percutaneous technique for the treatment of MF. This study was therefore carried out to highlight the possible strengths and weaknesses of both techniques.

In our personal experience the EPB technique is easier to perform, even if it carries the risk of greater iatrogenic damages, since it involves transfixion of the DIP joint for many weeks, which may cause stiffness and potential chondral damage, especially if several pinning maneuvers are made, to center the pin in the body of the distal phalanx. Furthermore, the joint transfixion could lead to osteoarthritis in case of pinning infection. Moreover, the dorsal oblique pinning could be responsible of skin decubitus, and nail bed injury. Otherwise, a single K-wire fixation of the fracture, as in the UH technique, may prevent these complications, but it is more challenging, needing to modify intraoperatively the K-wire shape. Furthermore, it carries the risk of bone fragmentation, in the smallest MF. Moreover, a custom-made thermoplastic splint has to be used to distribute the pressure of pin fixation across the whole of the finger pulp.

In the light of the experience gained and of the results obtained from this retrospective study, we believe the EPB technique may lead more frequently to DIP joint stiffness, even in absence of clear clinical and

radiological complications such as malreduction, dislocation and nail or skin injury. In the sample of this study, nine out of fifty cases ended up with a stiff digit ("fair" or "poor" results) among which in four cases no other clinical evident complication was present. This is probably caused by the chondral damage due to repeated pinning maneuvers in the attempt to find the ideal position, especially in small fingers, and to the six weeks of joint fixation in the extended position. Another pitfall of this technique is certainly the potential nail damage due to the presence of the oblique dorsal pinning that may cause a prolonged compression on the dorsal skin above the nail matrix. In this study four cases of nail bed injury were reported. On the other side, in our casuistry no cases of osteomyelitis or of osteoarthritis has been found, and only one case of fragment dislocation was observed, making EPB a safe and valid technique. Moreover, our results and complication rate are similar to those present in the literature for the EPB technique. Darder-Prats et al. (21) present 11 excellent results on 22 patients with two complications: 1 skin necrosis and 1 tendon rupture. In 2003, among the 65 patients of Pegoli et al. (24) 51 had a good or excellent result, and 13 had a fair result explained by the authors by a poor reduction during surgery. Among their patients they describe 1 pin tract infection and 2 nail deformities. Hofmeister et al.¹ describe in their article 2 pin site infections and 2 displacements of reduction out of 24 patients treated with Ishiguro technique. In Acar comparative study (25) between hook plate reduction and Ishiguro technique to treat MF, among the 13 patients treated with EPB 5 had complications: 1 nail deformity, 2 dorsal prominences, 1 degeneration of joint and 1 displacement.

Concerning the UH technique, despite a more challenging execution, complications seem to be less frequent. In this study, two patients had a fragment dislocations post hardware removal that however ended up having "good" results. In those cases, the absence of pain and the good joint motion is probably consequent to the production of a fibrotic scar which maintains the fragment in continuity with the distal phalanx. Two patients had a "fair" result. In one case a skin infection developed. In another a bone fragmentation was observed at follow-up. This patient was classified as 2b, and the small size of the bone fragment was probably the cause of this complication. In

addition to a low complication rate, this technique led, in our experience, to “excellent” or “good” results in 46 out of 48 cases (96%).

Overall, we believe that UH technique should be used in fracture with fragments of big dimension such as 2C fractures because of the necessity to reduce the fragment and the greater ease to pin it; whereas EBS technique seems to achieve better results in MF with non-dislocated, and small fragments such as 1B fractures, for which the UH technique has higher risk of bone fragmentation. Those affirmations are supported, although in a non-statistically significant manner, by our results.

Results of this study also seem to confirm the importance of the promptness of treatment in both techniques: most of complications and bad results were found in patients treated several weeks after trauma. This is probably due to the formation of fibrotic tissue in the displaced fracture line, discouraging for these cases a percutaneous management. Finally, age of patients seems to affect results in both techniques: results are better in younger patients, as they have surely a higher bone healing capacity.

This study surely presents some limitations: it's retrospective aspect, the fact that different surgeons performed the surgeries choosing autonomously - without a clearly defined reason - which technique they would use, and the heterogeneity of patients treated.

In conclusion, we consider both techniques valid to treat Mallet Fractures with fragment size bigger than one-third of the articular surface. While waiting for a prospective blinded study with more defined results, we believe that the choice of one technique among the other should depend on an accurate analysis of the MF characteristic case by case.

Conflict of interest: Each author declares that he has no commercial associations that might pose a conflict of interest in connection with the submitted article. Institutional Review Board approval was not required for this retrospective observational study as all data was processed and presented as aggregated data, making not possible to identify any individual patient.

References

- Hofmeister EP, Mazurek MT, Shin AY, Bishop AT. Extension block pinning for large mallet fractures. *J Hand Surg Am* 2003 May;28(3):453-9.
- Han HH, Cho HJ, Kim SY, Oh DY. Extension block and direct pinning methods for mallet fracture: A comparative study. *Arch Plast Surg* 2018 Jul;45(4):351-356.
- Usami S, Kawahara S, Kuno H, Takamura H, Inami K. A retrospective study of closed extension block pinning for mallet fractures: Analysis of predictors of postoperative range of motion. *J Plast Reconstr Aesthet Surg* 2018 Jun;71(6):876-882.
- Huang Y, Wu K, Shi H, Shen Y, Zhang Z, Rui Y. Kirschner wire fixation versus suture anchor technique for mallet finger: A meta-analysis. *Medicine (Baltimore)* 2021;100(11):e24996.
- Çapkin S, Buyuk AF, Sürücü S, Bakan OM, Atlıhan D. Extension-block pinning to treat bony mallet finger: Is a transfixation pin necessary? *Ulus Travma Acil Cerrahi Derg* 2019 May;25(3):281-286.
- Stark Hh, Boyes Jh, Wilson Jn. Mallet finger. *J Bone Joint Surg Am.* 1962 Sep;44-A:1061-8.
- Wehbé MA, Schneider LH. Mallet fractures. *J Bone Joint Surg Am* 1984;66:658-69.
- Salazar Botero S, Hidalgo Diaz JJ, Benaïda A, Collon S, Facca S, Liverneaux PA. Review of Acute Traumatic Closed Mallet Finger Injuries in Adults. *Arch Plast Surg* 2016 Mar;43(2):134-44.
- Trickett RW, Brock J, Shewring DJ. The non-operative management of bony mallet injuries. *J Hand Surg Eur* 2021 Jun;46(5):460-465.
- McCue FC, Abbott JL. The treatment of mallet finger and boutonniere deformities. *Va Med Mon* (1918). 1967;94(10):623e628.
- Takami H, Takahashi S, Ando M. Operative treatment of mallet finger due to intra-articular fracture of the distal phalanx. *Arch Orthop Trauma Surg* 2000;120(1-2):9e13.
- Lin JS, Samora JB. Surgical and Nonsurgical Management of Mallet Finger: A Systematic Review. *J Hand Surg Am* 2018 Feb;43(2):146-163.e2.
- Hamas RS, Horrell ED, Pierret GP. Treatment of mallet finger due to intra-articular fracture of the distal phalanx. *J Hand Surg Am* 1978;3(4):361e363.
- Houpt P, Dijkstra R, Storm van Leeuwen JB. Fowler's tenotomy for mallet deformity. *J Hand Surg Br* 1993;18(4):499e500.
- Jupiter JB, Sheppard JE. Tension wire fixation of avulsion fractures in the hand. *Clin Orthop Relat Res* 1987 Jan;(214):113-20.
- Kronlage SC, Faust D. Open reduction and screw fixation of mallet fractures. *J Hand Surg Br* 2004;29:135-8.
- Damron TA, Engber WD. Surgical treatment of mallet finger fractures by tension band technique. *Clin Orthop Relat Res* 1994;133-40.
- Teoh LC, Lee JY. Mallet fractures: a novel approach to internal fixation using a hook plate. *J Hand Surg Eur Vol* 2007;32:24-30.
- Miura T. Extension block pinning using a small external fixator for mallet finger fractures. *J Hand Surg Am* 2013;38:2348-52.

20. Ishiguro T, Itoh Y, Yabe Y, Hashizume N (1997). Extension block with Kirschner wire for fracture dislocation of the distal interphalangeal joint. *Tech Hand Up Extrem Surg* 1997; 1: 95–102.
21. Darder-Prats A, Fernandez-Garcia E, Fernandez-Gabarda R, Darder-Garcia A (1998). Treatment of mallet finger fractures by the extension-block K-wire technique. *J Hand Surg* 1998; 23(6): 802–5.
22. Rocchi L, Genitiempo M, Fanfani F. Percutaneous fixation of mallet fractures by the “umbrella handle” technique. *J Hand Surg Br* 2006;31(4):407-12.
23. Crawford GP (1984). The molded polythene splint for mallet finger deformities. *J Hand Surg* 1984; 9: 231–7.
24. Pegoli L, Toh S, Arai K, Fukuda A, Nishikawa S, Vallejo IG. The Ishiguro extension block technique for the treatment of mallet finger fracture: indications and clinical results. *J Hand Surg Br* 2003;28(1):15e17.
25. Acar MA, Guzel Y, Gulec A, Uzer G, Elmadag M. Clinical comparison of hook plate fixation versus extension block pinning for bony mallet finger: a retrospective comparison study. *J Hand Surg Eur* 2015;40(8):832e839.

Correspondence:

Received: 1 November 2021

Accepted: 23 November 2021

Camillo Fulchignoni, MD

Hand Surgery and Orthopedics Unit,

Department of Orthopaedics and Traumatology, Fondazione

Policlinico Universitario A. Gemelli IRCCS, Rome Italy

Largo A. Gemelli, 8. 00168 Rome, Italy.

Phone: +39 3317880630

E-mail: camillo.fulchignoni@gmail.com