



BRIEF REPORT

# Two elective invasive procedures after a single avatrombopag treatment in a patient with liver cirrhosis and severe thrombocytopenia

Marco Biolato <sup>1,2,\*</sup>, Federica Vitale <sup>2</sup>, Giuseppe Marrone <sup>1,2</sup>,  
Luca Miele <sup>1,2</sup> and Antonio Grieco <sup>1,2</sup>

<sup>1</sup>Internal and Liver Transplant Medicine Unit, CEMAD, Department of Medical and Surgical Sciences, Fondazione Policlinico Universitario Agostino Gemelli IRCCS, Rome, Italy; <sup>2</sup>Institute of Internal Medicine, Catholic University of the Sacred Heart, Rome, Italy

\*Corresponding author. Transplant Hepatologist, Internal and Liver Transplant Medicine Unit, CEMAD, Department of Medical and Surgical Sciences, Fondazione Policlinico Universitario Agostino Gemelli IRCCS, Largo A Gemelli 8, 00168 Rome, Italy. Tel: +39630154469; Email: marco.biolato@policlinicogemelli.it

## Introduction

Severe thrombocytopenia (platelet count  $<50 \times 10^9/L$ ) occurs in 1%–2% of patients with liver cirrhosis and is associated with an increased risk of bleeding [1]. In this clinical setting, there is no definite agreement on the platelet cut-off below which bleeding risk increases. However, *in vitro* evidence indicates that thrombin generation is preserved in patients with cirrhosis and platelet counts of  $>56 \times 10^9/L$  [2]. Observational studies found that severe thrombocytopenia may be predictive of post-procedure bleeding after liver biopsy, dental extractions, percutaneous ablation of liver tumors, and endoscopic polypectomy [3]. These data have been used to promote a platelet count of  $>50 \times 10^9/L$  as a target for prophylaxis. Guidelines from the European Association for the Study of Liver (EASL) suggest that correction by platelet transfusion or thrombopoietin receptor agonists may be considered before high-risk invasive procedures on a case-by-case basis in patients with severe thrombocytopenia [4].

Platelet transfusion does have some limitations such as short lifespan (median, 72 hours), limited availability, and high costs [5]. The possibility of related adverse events, such as transfusion reactions (1/100), infections, volume overload, and transfusion-related acute lung injury, must be taken into account too [6]. Moreover, after repeated administration of

platelets, refractoriness due to human leukocyte antigen alloimmunization may occur [7].

In 2018, avatrombopag, a second-generation, orally bioavailable, small-molecule thrombopoietin receptor agonist, received its first approval for use in the USA in the treatment of thrombocytopenia in adult patients with chronic liver disease who were scheduled to undergo an invasive procedure [8]. In the ADAPT-1 and ADAPT-2 trials, avatrombopag was tolerated well and demonstrated to be effective in reducing the need for platelet transfusion in 88% of patients with baseline platelet count of  $40 \times 10^9$  to  $50 \times 10^9/L$  (compared with 33%–38% in the placebo group) and in 66%–69% of those patients with basal platelet count of  $<40 \times 10^9/L$  (compared with 23%–35% in the placebo group) [9].

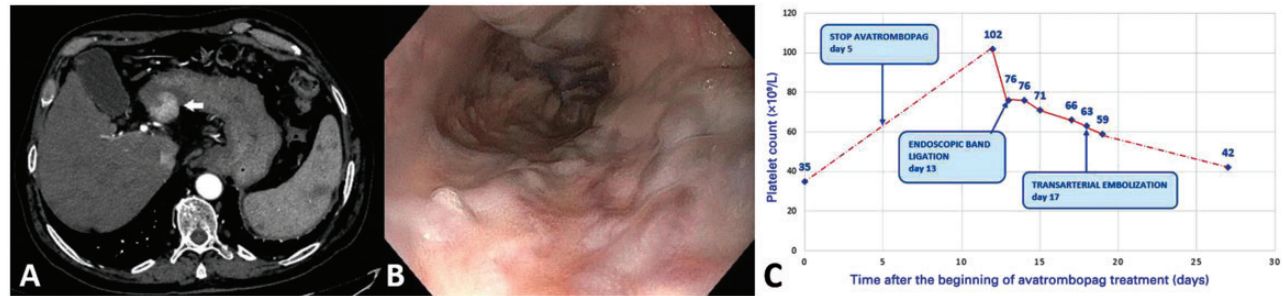
According to the approved treatment schedule, avatrombopag is administered orally for 5 days, followed by a time window of 4 days (Days 10–13 from the beginning of treatment) during which the elective invasive procedure can be performed. In some cases, the duration of response to avatrombopag is longer, which allows multiple elective procedures to be performed after a single treatment course. In this report, we described a case of a cirrhotic patient with severe thrombocytopenia who underwent two elective invasive procedures after a single course of avatrombopag.

Submitted: 7 June 2022; Revised: 5 August 2022; Accepted: 10 October 2022

© The Author(s) 2022. Published by Oxford University Press and Sixth Affiliated Hospital of Sun Yat-sen University

This is an Open Access article distributed under the terms of the Creative Commons Attribution-NonCommercial License (<https://creativecommons.org/licenses/by-nc/4.0/>), which permits non-commercial re-use, distribution, and reproduction in any medium, provided the original work is properly cited.

For commercial re-use, please contact [journals.permissions@oup.com](mailto:journals.permissions@oup.com)



**Figure 1.** A cirrhotic patient with severe thrombocytopenia who underwent two elective invasive procedures after a single course of avatrombopag. (A) Hepatocellular carcinoma in the III hepatic segment (computed tomography scan, arterial phase). (B) Large esophageal varices with red wale markings (upper endoscopy). (C) Platelet count during avatrombopag treatment.

## Case report

A 70-year-old man with a history of liver cirrhosis related to hepatitis C virus infection was referred to our liver unit. He had been treated with direct-acting antivirals with sustained virological response 5 years before this visiting. He showed compensated liver cirrhosis, Child–Pugh A6 stage, Model for End-Stage Liver Disease score 7. His platelet count was  $33 \times 10^9/L$ . A computed tomography scan showed a single 2.2-cm nodule of hepatocellular carcinoma in the third hepatic segment (Figure 1A). The portal vein was patent and of increased caliber (18 mm in diameter). He presented also with large esophageal varices with red wale marks at endoscopy (Figure 1B). The case was discussed by our tumor board; the hypothesis of hepatic resection was excluded due to the extent of portal hypertension, while a percutaneous ablation was not considered safe in view of the subcapsular location of the nodule. The preferred option was transarterial embolization after prophylactic ligation of esophageal varices. The patient was then considered for thrombopoietin agonist treatment. His co-morbidities included type-2 diabetes mellitus, benign prostatic hyperplasia, and chronic obstructive pulmonary disease. His drug therapy included empagliflozin/metformin, carvedilol, tamsulosin, and esomeprazole.

In April 2022, the patient started the treatment of avatrombopag 60 mg daily for 5 days, with good tolerance and without adverse effects. At the beginning of treatment, his platelet count was  $35 \times 10^9/L$ ; this rose to a peak of  $102 \times 10^9/L$  on Day 12 from the beginning of treatment (Figure 1C). He underwent endoscopic band ligation on Day 13. On Day 17, his platelet count was still  $63 \times 10^9/L$  and he underwent transarterial embolization of hepatocellular carcinoma. No platelet transfusions were required before or after the procedures and no thrombotic or hemorrhagic complications occurred. Duplex ultrasound performed on Day 18 and computed tomography scan performed on Day 45 excluded portal vein thrombosis.

## Discussion

The salient points from this case report include the marked increase in platelet count, the duration of this increase, and the ability to plan two invasive procedures after a single course of avatrombopag treatment. In our patient, the effect on platelet count was particularly pronounced (up to three times baseline values) and allowed to exceed the procedural window (Days 10–13) tested in pivotal trials [9]. In our case, the platelet count remained  $>50 \times 10^9/L$  up to 19 days after the beginning of avatrombopag treatment.

Cirrhotic patients, especially liver transplant candidates, may require multiple invasive procedures. Decisions on timing

for multiple treatments in the same patient require careful evaluation of the clinical priorities and potential residual effects. In 2019, Saab et al. [10] investigated in four patients the efficacy and safety of avatrombopag in increasing platelet count with recurrent courses, showing no evidence of tachyphylaxis with the second administration of the treatment or reduction in its efficacy. However, as demonstrated in our case, avatrombopag can achieve an increase in platelet count sufficient to allow the patient to undergo more than one elective procedure within the same cycle of therapy. Saab et al. [10] reported a patient who underwent two elective procedures (endoscopic argon plasma coagulation and dental extraction) after a single treatment course. Almalki et al. [11] described the off-label use of avatrombopag in a patient candidate for combined coronary artery bypass grafting and liver transplantation who had a platelet count of  $18 \times 10^9/L$  at the beginning of avatrombopag treatment and  $63 \times 10^9/L$  on the day of surgery.

While there is general agreement about defining an invasive procedure as “high-risk” when its estimated bleeding risk is  $>1.5\%$ , there is ongoing debate on which procedures should fall into the “high-risk” or “low-risk” categories [4, 12]. Taking the two procedures performed in our patient as an example, endoscopic band ligation is considered at high risk in the EASL guidelines but low risk in the American Association for the Study of Liver (AASLD) guidelines; conversely, transarterial embolization is considered at high risk in the AASLD guidelines, while it is not mentioned in the EASL guidelines because of lack of data. Further studies are needed to more accurately stratify the risk of bleeding for the various invasive procedures in the cirrhotic patient, but it is difficult in the clinical setting to obtain an untreated control arm.

In conclusion, this case report supports the safety and effectiveness of the use of avatrombopag in patients with cirrhosis and severe thrombocytopenia who undergo a second invasive elective procedure after a single course of avatrombopag treatment. However, further evidence will be needed to confirm this finding.

## Authors' Contributions

M.B. wrote the paper; F.V. collected data and prepared the figure; G.M., L.M., and A.G. revised the paper for important intellectual content. All authors read and approved the final manuscript.

## Funding

Swedish Orphan Biovitrum S.R.L., Milano, Italy unconditionally supported the payment of the open access fees.

## Acknowledgements

We thank Stefano Bartoletti, MD, for proof-editing the text.

## Conflict of Interest

M.B. and A.G. received personal fees from SOBI s.r.l. and Shionogi B.V. Other authors declare no conflict of interests relevant to this study.

## References

1. Peck-Radosavljevic M. Thrombocytopenia in chronic liver disease. *Liver Int* 2017;**37**:778–93.
2. Tripodi A, Primignani M, Chantarangkul V et al. Thrombin generation in patients with cirrhosis: the role of platelets. *Hepatology* 2006;**44**:440–5.
3. Alvaro D, Caporaso N, Giannini EG et al.; PReBRiC (Procedure-Related Bleeding Risk in Cirrhosis) Group. Procedure-related bleeding risk in patients with cirrhosis and severe thrombocytopenia. *Eur J Clin Invest* 2021;**51**:e13508.
4. European Association for the Study of the Liver. EASL Clinical Practice Guidelines on prevention and management of bleeding and thrombosis in patients with cirrhosis. *J Hepatol* 2022; **76**:1151–84.
5. Cesar JM, Vecino AM. Survival and function of transfused platelets: studies in two patients with congenital deficiencies of platelet membrane glycoproteins. *Platelets* 2009;**20**: 158–62.
6. Slichter SJ, Kaufman RM, Assmann SF et al. Dose of prophylactic platelet transfusions and prevention of hemorrhage. *N Engl J Med* 2010;**362**:600–13.
7. Valsami S, Dimitroulis D, Gialeraki A et al. Current trends in platelet transfusions practice: the role of ABO-RhD and human leukocyte antigen incompatibility. *Asian J Transfus Sci* 2015;**9**:117–23.
8. US FDA. Doptelet® (avatrombopag) tablets: US prescribing information. 2018. [https://www.accessdata.fda.gov/drugsatfda\\_docs/label/2018/210238s000lbl.pdf](https://www.accessdata.fda.gov/drugsatfda_docs/label/2018/210238s000lbl.pdf) (28 October 2022, date last accessed).
9. Terrault N, Chen YC, Izumi N et al. Avatrombopag before procedures reduces need for platelet transfusion in patients with chronic liver disease and thrombocytopenia. *Gastroenterology* 2018;**155**:705–18.
10. Saab S, McDaniel TK, Bau SN et al. Efficacy of repeat doses of avatrombopag: a case series. *Dig Med Res* 2019;**2**:9.
11. Almalki B, Shroff H, Maddur H et al. Avatrombopag use in patient with thromboembolic risks listed for combined coronary artery bypass grafting and liver transplant: a case report. *Transplant Proc* 2021;**53**:2567–9.
12. Northup PG, Garcia-Pagan JC, Garcia-Tsao G et al. Vascular liver disorders, portal vein thrombosis, and procedural bleeding in patients with liver disease: 2020 practice guidance by the American association for the study of liver diseases. *Hepatology* 2021;**73**:366–413.