



New onset of Susac syndrome after mRNA COVID-19 vaccine: a case report

Assunta Bianco^{1,2} · Francesca Colò² · Silvia Falso² · Rosellina Russo^{3,4} · Matteo Maria Carlà⁵ · Angelo Minucci⁶ · Gabriella Cadoni^{7,8} · Matteo Lucchini^{1,2} · Alessandra Cicia² · Paolo Calabresi^{1,2} · Massimiliano Mirabella^{1,2}

Received: 30 August 2022 / Revised: 26 September 2022 / Accepted: 27 September 2022
© The Author(s), under exclusive licence to Springer-Verlag GmbH Germany 2022

Introduction

Susac syndrome (SuS) is a rare immune-mediated disorder, affecting microvessels in the brain, retina and inner ear, leading to central nervous system dysfunction, visual disturbances and sensorineural hearing loss. These events may occur simultaneously or in succession. Since its first description in 1979 by John Susac, about 400 cases have been described; however, SuS is probably underdiagnosed. SuS usually affects young adults between 20 and 40 years (female-to-male ratio of 3.5/1) [1, 2].

Occlusive microvascular endotheliopathy/basement membranopathy represents a disease hallmark, but the pathogenesis is still debated. Infections, diet or medications have been described as possible triggers of autoimmunity

[1]. In 2006, a case of SuS after smallpox vaccination was reported. The COVID-19 pandemic has affected over 260 million people and different neurological disorders have been related to both Severe Acute Respiratory Syndrome Coronavirus 2 (SARS-CoV-2) infection and vaccination [3]. Six cases of SuS related to SARS-CoV-2 infection or vaccination have been described: two following SARS-CoV2 infection, one related to ChAdOx1 vaccine, and three after Coronavac vaccine [4]. Here we report the first case of SuS after BNT162b2 mRNA COVID-19 vaccine (Comirnaty®).

✉ Assunta Bianco
assunta.bianco@unicatt.it

Francesca Colò
francesca.colo02@unicatt.it

Silvia Falso
silvia.falso@hotmail.it

Rosellina Russo
rosellina.russo@policlinicogemelli.it

Matteo Maria Carlà
mmcarla94@gmail.com

Angelo Minucci
angelo.minucci@policlinicogemelli.it

Gabriella Cadoni
gabriella.cadoni@policlinicogemelli.it

Matteo Lucchini
matteo.lucchini@policlinicogemelli.it

Alessandra Cicia
cicia.alessandra@gmail.com

Paolo Calabresi
paolo.calabresi@unicatt.it

Massimiliano Mirabella
massimiliano.mirabella@unicatt.it

- 1 Multiple Sclerosis Center, Fondazione Policlinico Universitario Agostino Gemelli IRCCS, 00168 Rome, Italy
- 2 Department of Neurosciences, Catholic University of Sacred Heart, 00168 Rome, Italy
- 3 Neuroradiology Unit, Fondazione Policlinico Universitario Agostino Gemelli IRCCS, 00168 Rome, Italy
- 4 Institute of Radiology, Catholic University of Sacred Heart, 00168 Rome, Italy
- 5 Institute of Ophthalmology, Catholic University of Sacred Heart, 00168 Rome, Italy
- 6 Departmental Unit of Molecular and Genomic Diagnostics, Fondazione Policlinico Universitario Agostino Gemelli IRCCS, 00168 Rome, Italy
- 7 Otorhinolaryngology Unit, Fondazione Policlinico Universitario Agostino Gemelli IRCCS, 00168 Rome, Italy
- 8 Department of Otorhinolaryngology, Catholic University of Sacred Heart, 00168 Rome, Italy

Case report

In July 2021, a 24-year-old healthy woman presented with hearing loss in her left ear, confusion, behavioral changes, and headache, 4 days after her first dose of Comirnaty®. Tonal audiometry showed a moderate left sensorineural

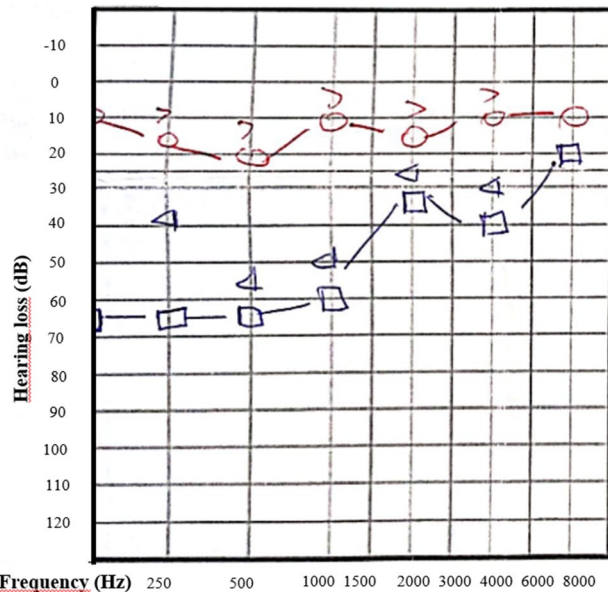


Fig. 1 Pure tone audiometry: left low-to-mid frequency sensorineural hearing loss. Circle: right ear; Square: left ear

hearing loss (Fig. 1). Cerebral MRI showed multifocal ovoid callosal (*snowball*) lesions, white matter hyperintensities and restricted diffusion (Fig. 2). She received prednisone 37.5 mg for 2 weeks and intratympanic steroid injections with poor response. In February 2022, a second dose of COVID-19 vaccine was administered. In March 2022, the patient was admitted to our unit because of persisting left sensorineural hearing loss and headache. Neurological examination was normal and she denied visual symptoms. Workup tests on serum and CSF were unremarkable, except for moderate protein increase on CSF (96 mg/dl, normal values 20–40). MRI review suggested a SuS diagnosis. Ultra-wide fluorescein angiography (UWFA) showed peripheral areas of hypofluorescence, as a result of retinal ischemia from recurrent branch retinal artery occlusion. Moreover, areas of arteriolar occlusion were detected showing a fluid void (Fig. 3A, B). Optical Coherence Tomography of the right eye evidenced a parcel retinal ischemia above the fovea (Fig. 3C). According to European Susac Consortium Diagnostic Criteria², a definite SuS diagnosis was made. HLA-C genotyping was tested and HLA-C*04-C*16 was detected. Since symptoms were limited to hearing loss, a close follow-up to better define the disease activity was started. In May 2022, UWFA showed a new area of hyperfluorescence and mild leakage suggestive for acute inflammatory vessel damage. A new MRI showed marked decrease of known hyperintense lesions but a new lesion appeared in the subcortical white matter (Fig. 11). Because of new cerebral and retinal lesions and lack of improvement of hearing loss, therapy

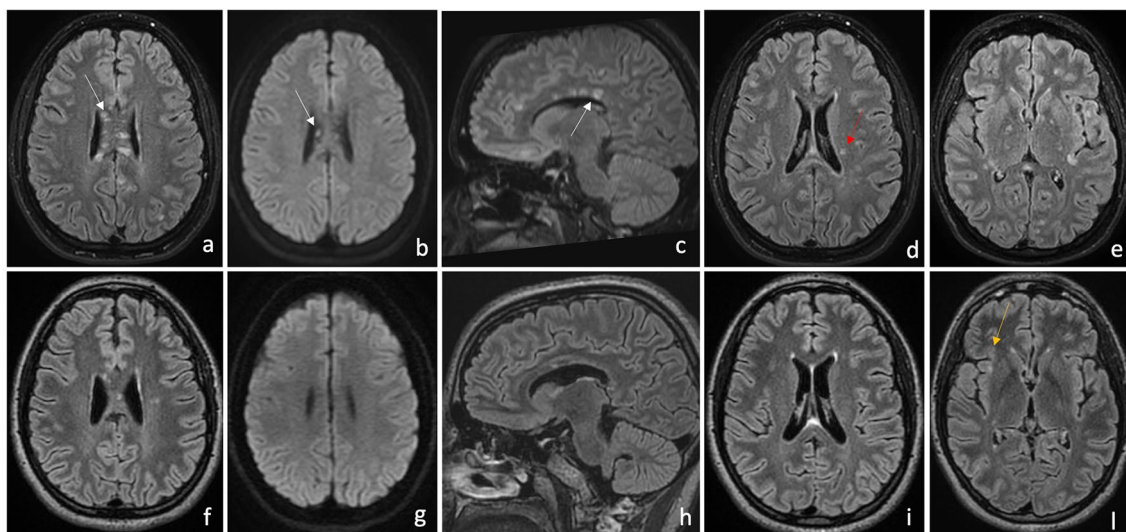
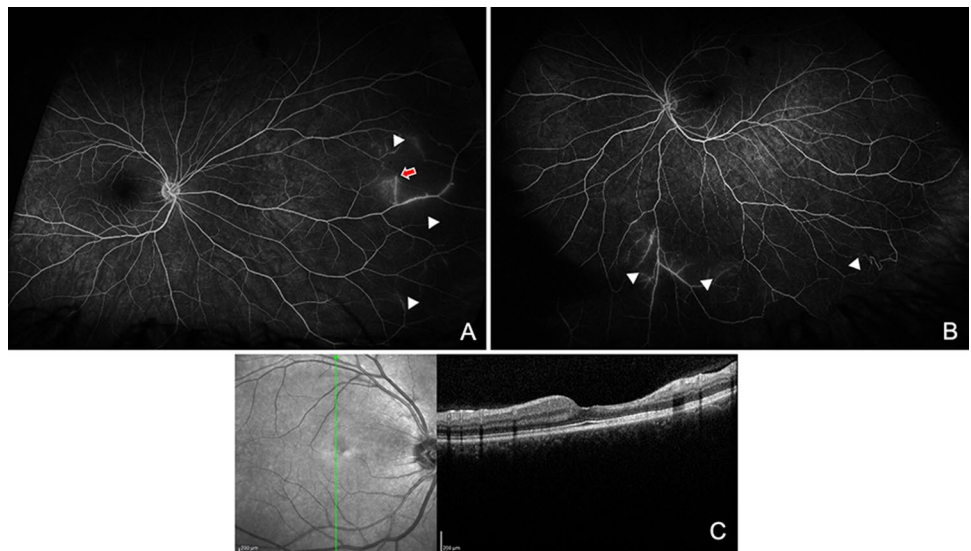


Fig. 2 Cerebral Magnetic Resonance Imaging (MRI) at disease onset (a–e) and at follow-up (f–l). MRI scan by fluid attenuated inversion recovery (FLAIR) demonstrated multifocal ovoid callosal (white arrow) and white matter (red arrow) hyperintensities (a, c, d, e), while diffusion-weighted imaging (DWI) showed diffusion restric-

tion of callosal lesions (b); these findings were typical for Susac syndrome. Twelve months later, a new MRI showed marked decrease of known hyperintense lesions on FLAIR sequences (f, h, i) and of diffusion restriction on DWI (g); however, a new subcortical white matter lesion (yellow arrow) appeared (l)

Fig. 3 Ultra-Wide Fluorescein Angiography (UWFA) of the right (A) and left (B) eye showed peripheral areas of hypofluorescence, as a result of retinal ischemia from recurrent branch retinal artery occlusions (white arrowheads). In A, area of arteriolar occlusion showed a fluid void due to fluorescein not passing beyond the blockage (red arrow). Optical Coherence Tomography (OCT) imaging of the right eye C showed the result of a parcel retinal ischemia above the fovea, with significant retinal thinning and inner retinal layer disruption. Green arrow indicates the direction of the scan



with IV high-dose methylprednisolone (1 g for 5 days) and rituximab (1000 mg) was started.

Discussion

Our case and similar reports [4] suggest a possible interaction between genetic background and environmental triggers leading to microvessel damage [3]

Proposed mechanisms for vaccine-induced autoimmunity include molecular mimicry and bystander activation: either the antigen produced from the mRNA vaccine may be recognized by the immune system as similar to a self-antigen resulting in T cell activation against host tissue, or previously existing self-antigens are released upon stimulation of innate immune system as part of the vaccine response inducing activation of autoreactive T cells [5].

As recently demonstrated, most SuS patients exhibit HLA-C*06 and/or HLA-C*07 although some cases homozygous for HLA-C*04 were reported. Even private clones, only found in individual SuS patients, have been reported, but we may support the hypothesis that public clones recognize similar unknown antigens shared in different subjects [6].

Onset of symptoms in our patient correlates with vaccine administration, but causality cannot be proven. Reports of other immune-mediated diseases developing as early as 2 days after the first dose of a COVID-19 vaccine [4] support the likelihood of SuS provoked by vaccination. In our case, the time interval between vaccination and symptoms onset was 4 days.

Treatment choice of SuS depends on degree of brain, retina and inner ear involvement [7]. Due to new cerebral and retinal lesions, a treatment regimen was started. Management of SuS is challenging because of great variability,

lack of biomarkers of disease activity and no controlled trials or prospective treatment studies. However, complete disease suppression is required to prevent from irreversible damages. Rituximab is suggested as an effective and well-tolerated option for moderate–severe disease [7].

In conclusion, vaccine-induced SuS is a rare event that can occur also after mRNA COVID-19 vaccine and this possibility should be kept in mind in the presence of central nervous system dysfunction, visual disturbances and sensorineural hearing loss.

Declarations

Conflict of interest FC, SF, RR, MMC, AM, GC, AC, and VC have nothing to declare. AB has served on advisory boards and/or has received travel grants and/or speaker honoraria from Merck, Biogen, Almirall, Novartis, and Sanofi-Genzyme. ML has served on advisory boards and/or has received travel grants and/or speaker honoraria from Merck, Biogen, Almirall, Novartis, and Sanofi-Genzyme. MM: scientific advisory board membership of Bayer Schering, Biogen, Sanofi-Genzyme, Merck, Novartis, Teva; consulting and/or speaking fees, research support or travel grants from Almirall, Bayer Schering, Biogen, CSL Behring, Sanofi-Genzyme, Merck, Novartis, Teva, Roche, Ultragenix; principal investigator in clinical trials for Biogen, Merck, Novartis, Roche, Sanofi Genzyme, Teva, Ultragenix, and CSL Behring. PC has no conflict of interest regarding this article.

Ethical standard This article does not contain any experimental studies with human participants or animals.

Informed consent Written informed consent has been collected from the patient for an anonymized publication of this report.

References

1. Marrodan M, Fiol MP, Correale J (2022) Susac syndrome: challenges in the diagnosis and treatment. *Brain* 145(3):858–871. <https://doi.org/10.1093/brain/awab476>
2. Kleffner I, Dörr J, Ringelstein M, Gross CC, European Susac Consortium (EuSaC) et al (2016) Diagnostic criteria for Susac syndrome. *J Neurol Neurosurg Psychiatry* 87(12):1287–1295. <https://doi.org/10.1136/jnnp-2016-314295>
3. Finsterer J (2022) Neurological side effects of SARS-CoV-2 vaccinations. *Acta Neurol Scand* 145(1):5–9. <https://doi.org/10.1111/ane.13550>
4. Chen PJ, Chang YS, Lim CC, Lee YK (2022) Susac syndrome following COVID-19 vaccination: a case report. *Vaccines (Basel)*. 10(3):363. <https://doi.org/10.3390/vaccines10030363>
5. Wraith DC, Goldman M, Lambert PH (2003) Vaccination and autoimmune disease: what is the evidence? *Lancet* 362(9396):1659–1666. [https://doi.org/10.1016/S0140-6736\(03\)14802-7](https://doi.org/10.1016/S0140-6736(03)14802-7)
6. Gross CC, Meyer C, Bhatia U et al (2019) CD8+ T cell-mediated endotheliopathy is a targetable mechanism of neuro-inflammation in Susac syndrome. *Nat Commun* 10(1):5779. <https://doi.org/10.1038/s41467-019-13593-5>
7. Rennebohm RM, Asdaghi N, Srivastava S, Gertner E (2020) Guidelines for treatment of Susac syndrome—an update. *Int J Stroke* 15(5):484–494. <https://doi.org/10.1177/1747493017751737>