

Combined gastric mucosal ablation of the fundus using a new hybrid device with endoscopic sleeve gastroplasty for obesity



Endoscopic bariatric therapies provide a minimally invasive alternative for patients with obesity who are either ineligible for or unwilling to undergo surgery [1, 2].

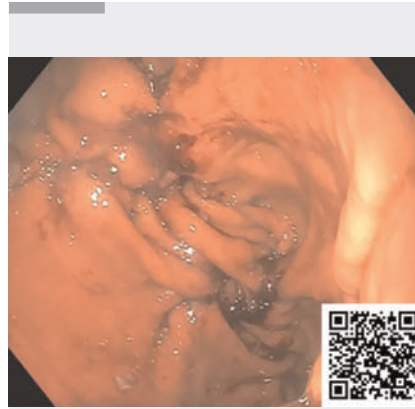
We describe a novel combined endoscopic approach that integrates endoscopic sleeve gastroplasty (ESG) with gastric mucosal ablation (GMA) of the fundus using a MOVIVA probe (ERBE, Tübingen, Germany).

The MOVIVA probe integrates two essential functions. First, it enables the injection of a submucosal fluid cushion to lift the mucosa and shield the deeper tissue layers from potential thermal damage. Second, it allows controlled superficial ablation of the mucosa through argon plasma coagulation. The goal is to reduce ghrelin-producing cells, thereby attenuating hunger signaling. Obese patients show increased ghrelin activity, which is correlated with the body mass index (BMI [3]). Targeting fundic ghrelin secretion has been associated with approximately 10% of the total body weight loss at 12 months [4, 5].

A 54-year-old male patient, with a BMI of 44 kg/m², type 2 diabetes mellitus, arterial hypertension, and obstructive sleep apnea syndrome, was selected after multidisciplinary evaluation.

The procedure was performed under general anesthesia in a supine position using a single-channel gastroscope. The MOVIVA probe was first introduced to achieve targeted mucosal ablation of the gastric fundus, providing uniform surface coverage. Subsequently, ESG was performed with an OverStitch NXT suturing system (Boston Scientific, Massachusetts, USA). Full-thickness U-shaped sutures were placed along the greater curvature to reduce gastric lumen (► **Video 1**).

The procedure was uneventful. Oral intake was resumed the following day. At the 1-month follow-up, the patient re-



► **Video 1** The video illustrates the complete case report, detailing the endoscopic technique and the specific hybrid devices used during the procedure, highlighting its feasibility and clinical applicability.

ported marked early satiety and achieved 16.5% of total body weight loss. No adverse events were reported.

This novel approach combines mechanical restriction with hormonal modulation. ESG remodels the gastric lumen, while MOVIVA-assisted GMA augments the metabolic effect by targeting ghrelin secretion. Future studies are needed to validate long-term safety and efficacy of this combined therapy.

Endoscopy_UCTN_Code_TTT_1AO_2AN

Contributors' Statement

Ivo Boškosi: Conceptualization, Investigation, Methodology, Resources, Software, Supervision, Validation. Loredana Gualtieri: Data curation, Formal analysis, Investigation, Methodology, Writing – original draft, Writing – review & editing. Martina De Siena: Data curation, Formal analysis, Investigation, Supervision, Visualization. Maria Valeria Matteo: Data curation, Supervision, Visualization. Valerio Pontecorvi: Data curation, Validation, Visualization. Cristiano Spada: Project administration, Resources, Software, Super-

vision. Vincenzo Bove: Data curation, Funding acquisition, Investigation, Methodology, Project administration, Supervision, Validation, Writing – review & editing.





Acknowledgement

We are grateful to Fondazione Roma for their invaluable support for scientific research (FR-CEMAD21-25).

Conflict of Interest

V. Bove is a consultant for Boston Scientific and Endo Tools Therapeutics S.A. C. Spada is a consultant for Medtronic and AnX Robotics, and has received speaker's fees from Olympus and Pentax. I. Boškosi is a consultant for Boston Scientific, Nitinotes, Pentax, Cook Medical, Microtech, ERBE, Siemens, Myka labs, and Endo Tools Therapeutics S.A., gives sponsored lectures for Boston Scientific, Cook Medical, and Microtech, is the recipient of research grants from Apollo Endosurgery, Endo Tool Therapeutics, and ERBE, and is on the scientific advisory boards of Nitinotes and Myka labs. L. Gualtieri, M. V. Matteo, M. De Siena and V. Pontecorvi declare that they have no conflict of interest.

The authors

Ivo Boškosi¹ , Loredana Gualtieri¹ , Martina De Siena¹ , Maria Valeria Matteo¹ , Valerio Pontecorvi¹, Cristiano Spada¹, Vincenzo Bove¹

¹ Digestive Endoscopy Unit, Fondazione Policlinico Universitario Agostino Gemelli IRCCS, Rome, Italy

Corresponding author

Loredana Gualtieri, MD

Digestive Endoscopy Unit, Fondazione Policlinico Universitario Agostino Gemelli IRCCS, Largo Agostino Gemelli, 8, 00136, Rome, Italy
loredana.gualtieri.15@gmail.com

References

- [1] Boškosi I, Pontecorvi V, Gallo C et al. Redo endoscopic sleeve gastroplasty: technical aspects and short-term outcomes. *Ther Adv Gastroenterol* 2020; 13: 1756284819896179. doi:10.1177/1756284819896179
- [2] Singh S, Hourneaux de Moura DT, Khan A et al. Safety and efficacy of endoscopic sleeve gastroplasty worldwide for treatment of obesity: a systematic review and meta-analysis. *Surg Obes Relat Dis Off J Am Soc Bariatr Surg* 2020; 16: 340–351
- [3] Castorina S, Barresi V, Luca T et al. Gastric Ghrelin Cells in Obese Patients Are Hyperactive. *Int J Obes* 2021; 45: 184–194. doi:10.1038/s41366-020-00711-3
- [4] Reddy VY, Neužil P, Musikantow D et al. Transcatheter Bariatric Embolotherapy for Weight Reduction in Obesity. *J Am Coll Cardiol* 2020; 76: 2305–2317. doi:10.1016/j.jacc.2020.09.550
- [5] Itani MI, Farha J, Sartoretto A et al. Endoscopic sleeve gastroplasty with argon plasma coagulation: a novel technique. *J Dig Dis* 2020; 21: 664–667

Bibliography

Endoscopy 2026; 58: E141–E142

DOI 10.1055/a-2767-0830

ISSN 0013-726X

© 2026. The Author(s).

This is an open access article published by Thieme under the terms of the Creative Commons Attribution License, permitting unrestricted use, distribution, and reproduction so long as the original work is properly cited.

(<https://creativecommons.org/licenses/by/4.0/>)

Georg Thieme Verlag KG, Oswald-Hesse-Str. 50, 70469 Stuttgart, Germany

