

5 NEURAL CORRELATES OF MENTAL IMAGERY

Perception and imagery share the same mechanisms also at a neural level. The proposed neural substrate for visual buffer consists of some cortical visual areas retinotopically organised (striate and extra-striate occipital areas). Studies on patients with brain damage (Farah 1988, 2000) showed that perceptive damage is often associated to limits in the ability to create images. Patients who have lost the ability to recognize certain classes of objects often have difficulty in generating mental images of the same objects. Instead, subjects who suffered damage at the right temporo-parietal lobe and suffered of unilateral spatial neglect cannot see objects on the left side of their visual field or cannot see the left side of the objects. Asking them to visually remind a familiar environment, they describe only objects located on the right (Bisiach and Luzzatti, 1978). If you ask them to imagine the environment looking from the opposite side, at this time they describe only objects that were previously excluded. Again, a neural limitation involves both visual perception and the construction of mental images. In fact, in recent literature we can find cases of double dissociation, in which perceptual functions are preserved and imaginative ones are damaged or, vice versa, there are damaged perceptive functions but intact imagery abilities. These cases of double dissociation between perceptual and imagery skills have frequently been traced back to Kosslyn's model (1994). Farah (1984), for example, has interpreted an isolated deficiency of imagination as originating from damage in the generating process, while Kosslyn attempted to explain isolated perception impairment as caused by damage to sensory coding system of the visual buffer.

The emergence of cognitive neuroscience has opened a new chapter in the study of imagery. An enormous amount has been learned about the neural underpinnings of visual perception, memory, emotion and motor control. New neuroimaging

technologies, especially positron emission tomography (PET) and functional magnetic resonance imaging (fMRI), allow theories of imagery to be tested objectively in humans.

5.1 Imagery and perception domains

According to Goldenberg (1993), there are at least five kinds of visual entities whose imagery can be independently affected by brain damages: shapes of objects, colours of objects, faces, letters and spatial relationships. Farah and coll. (Farah, 1988; Levine et al., 1985) have collected evidence suggesting that visual mental imagery – imagery for object shape and colour, faces and letters – mainly involves the ventral, or occipito-temporal, stream of visual processing, while spatial imagery (or movement-related imagery: Sirigu et al., 1996) rather requires the integrity of the dorsal, or occipito-parietal, stream of processing (see Mishkin et al., 1983; Milner and Goodale, 1995).

5.1.1 Shape domain

Visual recognition of an object is a process that takes place naturally and automatically because this ability is due to the formation of brightness or darkness zones on our retina. Object is an ability that can cover both the sensory discrimination of objects and the attribution of meaning to the object previously processed. Sensory discrimination is based on being able to identify differences between stimuli changing along a series of sensory dimensions. Furthermore, it is useful to emphasize that this ability is not linked to the structure or to familiarity with the stimuli to analyze, since it's also possible to recognize new objects, surfaces and shapes. Thanks to the fine ability to discriminate shapes, subjects construct a structured percept corresponding to the stimulus that must be recognized on the basis of its size, the angle of view and the volume. This level of processing or representation goes beyond what is highlighted by simple visual sensory analysis, because information obtained must be supplemented with information stored in the course of past experiences concerning the object. Therefore, objects are more than

percepts consistently structured, because they have a meaning based on the knowledge the observer is provided with. Subjects with intact visual processing skills might fail in giving a meaning to imagined objects or even might fail to mentally represent them. Conversely, may happen that patients with intact imagery abilities present perceptual deficits, as in the case of patient HJA studied by Riddoch and Humphreys (1987) who, for example, could draw, recalling from memory, objects that was no longer able to visually detect, presenting therefore a double dissociation with compromised perceptive abilities but intact imagery abilities. It seems obvious, therefore, that three distinct stages of processing are necessary for the recognition of objects: the first concerns the sensory visual properties, the second implies a structural object description and the third is to assign a meaning to percept.

5.1.2 Color domain

Damage in the perception of colours (achromatopsia) may occur as selective deficit in patients with specific brain lesions: in this case the subject will describe the world as poor of colour or as a black-and-white film. Colour blindness may or may not be associated with the recognition of objects and can occur in patients with a normal visual acuity. A colour perceptual deficit is colour agnosia, a deficit in knowledge of colour graduations, with the preservation of the skill to distinguish the different paints and adequate language skills.

Colour recognition is a fundamental domain not only for perception mechanisms but also for the study of the relationship between perception and imagery. Farah (1988), on the basis of numerous researches conducted on patients suffering of achromatopsia, concluded that neural processes underlying the recognition of colours are the same to those involved in mental representation of colours: she found, in his patients, that those who couldn't see certain colours, couldn't even imagine them. There are also experimental results obtained by Shelton (1994) to support this hypothesis. He studied the case of a patient who presented an agnosia for objects shapes and no-recognition of colour and simultaneously maintained a preserved imagination of objects with an associated deficit in colour imagery. Thanks to studies with the PET on patients with this type of associations it was later discovered that,

from an anatomical point of view, extended temporal lesions involve this kind of deficit in colours recognition and imagination.

5.1.3 Faces domain

Recognition of faces is the ability to process visual information about people's faces. At the beginning of research some authors described cases of patients who seemed to have lost face recognition ability: the deficit was, however, in presence of preserved object recognition ability. The term "prosopagnosia" was coined to describe, as argued by Bodamer (1947), the "incapacity to appreciate the visual deepest and genetically primitive category of human perception: the face" (McCarthy and Warrington, 1986).

There are three subtypes of prosopagnosia with three resulting deficits: visual analysis, perception and recognition of single faces. Deficits in visual analysis and perception implicate patient's inability to obtain adequate information from the visual stimuli, while in the last variant of deficit (recognition) the possibility of recognizing the face of a relative or of a particular person (a famous person) is compromised and a clear picture can't be recreated in mind. This third deficit affects, therefore, the whole imaginative area. Faces are three-dimensional extremely complex visual stimuli, and their processing may lead to distinguish between the ability to discriminate the facial identity and the type of facial emotion (Etcoff et al., 1991) and between the perceptual ability to recognize familiar faces recognition and their mental representation. Warrington and James (1967) showed that some patients couldn't recognize photographs of people well known (such as Marilyn Monroe or Winston Churchill). Also Riddoch and Humphreys (1987), by studying their prosopagnosic patient HJA, described his preserved ability to perform tasks in which he had to imagine faces or details of faces, but his difficulty to perform tasks in which he had to detect global facial similarity between configurations (for example who, between two actors, resembled most at a third person). The authors interpreted the data as evidence of an association between imagery and perception deficits, because the patient had perceptive difficulties that prevented him from integrating several aspects of any shape in a single configuration.

5.1.4 Orthographic material domain

A posterior left brain lesion may cause a pure alexia, an isolated deficit that impairs reading ability in absence of other deficit. The ability to mentally represent letters and other orthographic material is evaluated through tasks that require describing physical characteristics of single letters or entire words. For example, a typical task is to ask subjects to imagine the word "hotel" written on a hypothetical line and asking them if it contains letters that "run over" downward or upward ("h"). Another task often used is to ask people if a given letter contains curved line segments or not. In addition to those tests there is one, in particular, that was defined interesting by Goldenberg. The task is to imagine one letter at a time, mentally rotate it many times and in different directions and adding or deleting parts of the original letter: if at the end of all operations the subject is able to say which new letters is obtained, the task was correctly done. Goldenberg (1993) argued that in this kind of tasks the subjects applies two different strategies: a mental "reading" and a mental "writing" of letters, and often is the second mechanism, that of writing, to be used. Cases of patients with parietal injury who presented mental imagery deficit for orthographic material and a corresponding agraphia, confirm this hypothesis. But once again, in literature we have cases that falsify this interpretation, as testified by a double dissociation between imagery ability and contemporary impaired perception (pure alexia). A patient studied by Perri (1996): he committed errors in identification of letters or words visually presented, but he could accurately describe shape and characteristics of such letters when he was asked to imagine them.

5.1.5 Spatial domain

Studies on spatial processing in patients with brain lesions are designed to investigate two key aspects of spatial processing: difficulty in objects localization in space and topographical disorientation. There are moreover imagery deficits for spatial relations that can be combined or not with topographical disorientation, which confirm the hypothesis of a double dissociation between perception and imagery. Farah and coll. have described cases of double dissociation belonging to this

category and showed a strong relationship between spatial imagery deficits and parietal injury. The patient "RT", for example (Farah and Hammond, 1988), had a deficit in mental rotation tasks, but could imagine shapes, colours and sizes of objects. He didn't show, in addition, deficits in objects recognition and numbers or letters rotation; this was interpreted by the authors as an evidence that mechanisms underlying visual recognition of rotated objects are not the same as those underlying mental rotation operations.

Patient HJA, studied in 1995 by Riddoch, had a double dissociation opposite to the patient RT. In fact he obtained average performances in tasks that required estimation of rotation angles of imagined stimuli. However, he gave high deficitary results in perception, where the task, for example, was to estimate the distance between two cities shown on a map or describe spatial relationships relating to the arrangement of the furniture in his house. Again, data confirm a double dissociation between impaired perception skills and preserved imagery.

5.2 Functional localization and cognitive processing streams

In Kosslyn's and coll. (1990, 1994) model, imagery components are not localizable with precision, although neuropsychological research has shown that some processes can be related to certain anatomical-physiological structures. The analysis of visual system (Ungerleider and Mishkin, 1982) revealed that visual areas refer to two large cortical systems: the ventral stream (from occipital lobe to inferior temporal lobe) and the dorsal stream (from occipital lobe to superior parietal lobe). These two visual streams are characterized by distinct functional and complementary roles: the ventral stream deals with the codification and manipulation of the visual appearance of things (surface properties of objects like shape and colour); the dorsal stream instead, encodes and represents the spatial properties of objects (localization, orientation etc.) (Fig.5.1). The neuropsychological dimension of these two systems is demonstrated by visual deficits due to brain damage in the two described main paths. Damage to one of the two brain streams produces selective disorders: subjects with dorsal stream damage are able to recognize an object but are not able to indicate or report

its location in space. Subjects with damage to the ventral stream disorders, conversely, present “visual agnosia”: they know where something is located but they don't know what that is. Clinical cases support a modal behaviour beside one amodal of visual perception. According to Farah, about mental imagery we can conclude that imagery representations, as perceptual representation, are not an undifferentiated faculty, but consists rather in two kinds of representational abilities, visual and spatial.

Once the image is generated, image inspection use processes equal to those of visual perception (analysis of shapes with the ventral system, localization with the dorsal system). Farah's studies with electrical event-related potential provided evidence activation of posterior occipital area during visual imagery and posterior temporal area of left hemisphere (involvement would seem so prevalent in left temporo-parieto-occipital areas): so in imagery “the same neuronal structures used in the visual representation” are involved at least in part (De Pascalis, 1995).

Also studies with SPECT, a technique that assesses the cerebral blood flow, conducted by Goldenberg, Podreka and Steiner (1989) showed the involvement of the inferior left occipital region in mental imagery, but with considerable individual differences between subjects and differences relating to the type of task: the left hemisphere or the right hemisphere are differently activated according to the nature of tasks and stimuli used” (De Pascalis, 1995). The temporal and parietal lobes are also functionally connected with the frontal lobe (posterior-inferior); the frontal lobe involvement would have an inhibitory function due to the negative relationship between its activation and imagery. While acknowledging the prevalence of inferior occipital lobe, especially on the left, the authors conclude: «it seems visual imagery activate a total functional system, whose exact “borders” change from test to test. No single region, in fact, is consistently activated in all imagery conditions» (Goldenberg et al., 1989). This conclusion is explainable remembering that generation and transformation of a mental image involves a series of different components: understanding the instructions; access to information in the long-term memory; enabling appropriate memories about the object to imagine; correspondence between semantic information and the object's appearance; image generation; oral

summary about the result of image inspection. At the same time it must take account of the difficulty in isolating too clearly the different phases and components and of relating them point to point with cerebral areas: the brain is organized as a serial computer, but it jointly and in parallel activates areas and hemispheres involved in different components of the process (Sergent, 1990). Finally, attention, memory, categorization and inhibition of contrasting responses interact in imagery processes (all involving different brain areas): the whole brain is involved in imagery activity.

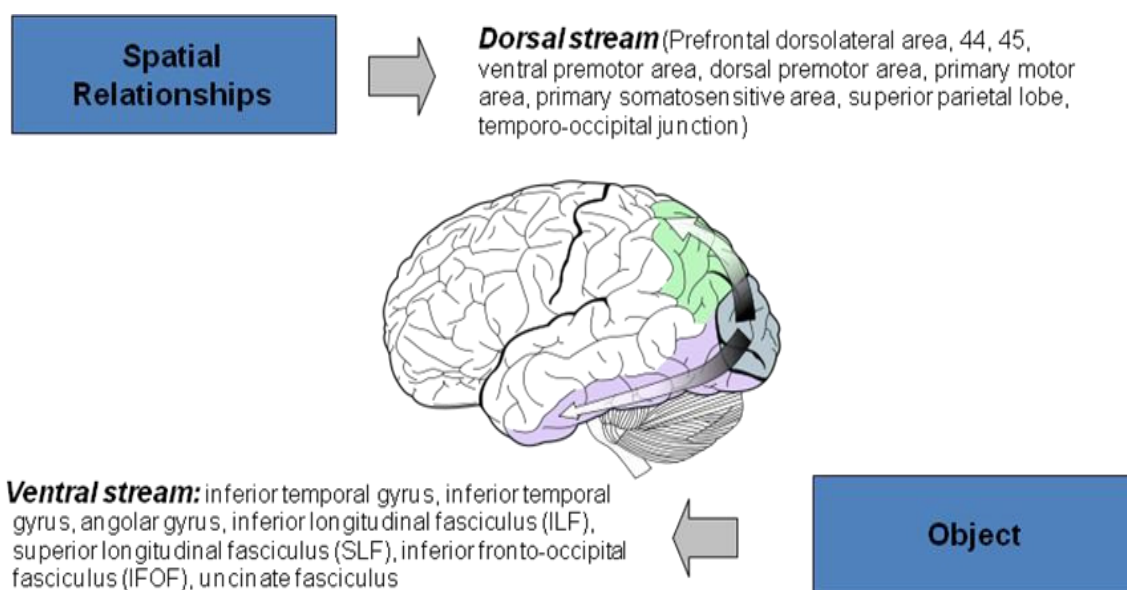


Fig. 5.1 Dorsal and ventral cortical systems.

5.2.1 Neural correlates of imagery and perception domains

What happens in the brain when you create a mental image in your mind's eye? Does the particular regions activate during mental imagery depend on the content of the image? Different studies showed that different imagery domains activate specific brain areas. So there's a possible modularity of imagery that suggests domain specific imagery for at least five types of visual entities (shapes, colours of objects, faces letters and spatial relationships). How we have seen previously the object pathway runs from the occipital lobe to the inferior temporal lobe, processing the

visual appearances of objects (shape and colors). It involves the inferior temporal gyrus, angular gyrus, inferior longitudinal fasciculus (ILF), superior longitudinal fasciculus (SLF), inferior fronto-occipital fasciculus (IFOF), uncinata fasciculus. The dorsal pathway determines the ability to visualize locations (space) and it involves prefrontal dorsolateral areas 44 and 45, ventral premotor area, dorsal premotor area, primary motor area, primary somatosensitive area, superior parietal lobe, temporo-occipital junction.

O'Craven and Kanwisher (2000), using functional magnetic resonance imaging (fMRI), demonstrated selective activation, during mental imagery of faces, in a cortical region specialized for face perception and selective activation during imagery of places, in a place-selective cortical region. Their findings reinforced evidence that imagery and perception share common processing mechanisms and specific brain regions. Different studies exploited the perceptual selectivity of two recently described extrastriate areas, a region of ventral occipito-temporal cortex called the fusiform face area (FFA) (Kanwisher, McDermott and Chun, 1997), which activates when subjects view photographs of faces, but not when they view other classes of stimuli such as familiar objects or complex scenes (McCarthy et al. 1997; Puce et al. 1996; Haxby et al., 1991). Conversely, a ventromedial cortical region called parahippocampal place area (PPA) activates with images of indoor and outdoor scenes depicting the layout of local space but not to faces (Epstein & Kanwisher, 1998). These regions provide an ideal arena for testing the selectivity of cortical activations during mental imagery, because they exhibit opposite response properties: the best stimulus for the FFA is the worst stimulus for the PPA and vice versa. Thus, researchers were able to look for a double dissociation of brain activity in response to imagery of two different classes of stimuli, instead of comparing imagery to non imagery tasks as most previous studies did. Other studies also demonstrated a more striking correspondence between imagery and perception, showing that many of the same regions that were selectively activated during perception of a particular class of stimuli were also activated during imagery.

Ishai, Haxby and Ungerleider (2002) demonstrated that the visual perception of famous faces activates the inferior occipital gyrus, lateral fusiform gyri, the superior

temporal sulcus, and the amygdala. Small subsets of these face-selective regions are activated during imagery. Visual imagery of famous faces activates a network of regions composed of bilateral calcarine, hippocampus, precuneus, intraparietal sulcus (IPS), and inferior frontal gyrus (IFG). Imagined faces result in increased activation in the right IPS and right IFG.

About imagery of letters, Raji (1999) carried out a study in which subjects were instructed to visually imagine the letter corresponding to the auditory stimulus and to examine its visuo-spatial properties. The associated brain activity was compared with activity evoked by the same stimuli when the subjects just detected the intervening tones. All subjects produced broad imagery-related responses over multiple cortical regions. After initial activation of the auditory cortices, the earliest imagery-related responses originated in the left prerolandic area, followed by signals originating in the posterior parietal lobe close to midline (precuneus) and in the posterior superior temporal areas, predominantly in the left hemisphere. The activations were sustained and partially overlapping in time. Task-induced visuospatial processing of these stimuli further increased activity in some of these regions and activated additional areas; certain brain areas involved in high-level visual perception were activated during visual imagery and the extent of imagery-related activity is due to the requirements of the stimuli and the task.

More recently Amici, Brambati et al (2007), using voxel based morphometry showed that overall sentence comprehension scores, regardless of grammatical structure, correlate with gray matter volumes in the left temporo parietal region and that comprehension of multicausal relative sentences significantly correlate with voxels in the dorsal portion of the left inferior and middle frontal gyri.

About the orthographic domain of mental imagery, in their study Gruber, Indefrey, Steinmetz and Kleinschmidt (2001) mapped brain activity in healthy subjects performing arithmetical tasks and tasks involving the representation of numbers as well as control tasks, evoking a comparable load on visuo-constructive, linguistic, attentional and mnemonic functions. They found significant differences between calculation and non-mathematical tasks in parietal sub-regions, where non-arithmetic number or letter substitution tasks preferentially activated the superior parietal

lobules, whereas calculation predominantly elicited activation of the left dorsal angular gyrus and the medial parietal cortices. They interpreted the latter activations related to sub-processes of mental calculation, numerical representations and to arithmetical fact retrieval. They found also that more complex calculation tasks, involving the application of calculation, rules increased activity in left inferior frontal areas that are known to sub serve linguistic and working memory functions.

5.2.2 Studies on brain damaged subjects

As reported previously, brain-damaged patients may demonstrate either impaired imagery and preserved perception or preserved imagery and impaired perception. Dissociation between impaired perception and preserved imagery has been described in object agnosia (Behrmann M, Moscovitch M. and Winocur G. 1994; Behrmann M, Winocur G. and Moscovitch M, 1992; Humphreys G.W and Riddoch M.J., 1987; Servos P. and Goodale M.A. 1995), pure alexia (Perri R, Bartolomeo P. and Silveri M.C. 1996), achomatopsia (Shuren J.E., Brott T. G., Schefft B.K. and Houston W. 1996) prosopagnosia (Young A.W., Humphreys G.W., Riddoch M. J., Hallowell D.J., de Haan E.H.F. 1994) and neglect (Bartolomeo P., D'Erme P. and Gainotti G., 1994).

Bartolomeo (2008) reported some historical cases of double dissociation. In 1883, Bernard described the case of Mr M.X., “a case of sudden and isolated suppression of the mental vision of signs and objects (form and colour)”. He was a well-learned polyglot, used to experience particularly vivid visual mental images for object forms and colours, which he described as being precise and glowing as reality itself. One day, M. X found himself to be completely unable to recall forms and colours from memory. Each time he went back to his hometown, he stared in amazement at streets and monuments, which looked unfamiliar to him, but was eventually able to find his way home. Asked to describe the principal place of his hometown, he answered: “I know it exists, but cannot imagine it or say anything about”. He could not draw anymore from memory in his former, detailed fashion. He perfectly remembered that his wife had black hair, but repeatedly complained of being unable to visualize it. Ophthalmologic examination only revealed myopia and a slight decrease in colour

perception. M. X's only perceptual problems appeared to consist in a minor reading impairment for some orthographic material; he was unable to recognize some Greek letters on visual presentation, unless he traced them with his finger. Charcot comments that "he has to compensate with his hand his moderate impairment of the visual memory of words". No other neurological deficit was observed. Charcot and Bernard concluded that memory is not a unitary faculty, but has modality-specific components, which can be selectively impaired, as it was the case for M. X's "visual memory". No evidence was available about the locus of lesion in this patient, but his reading problems in the absence of more elementary visual impairment might suggest left temporal damage with sparing of the occipital cortex.

Another patient, VSB, with extensive damage to the left temporal and parietal lobes and no occipital involvement (Bartolomeo et al., 2002), showed both pure alexia and an inability to retrieve the visual features of letters and words, unless he was allowed to trace them with his finger, and was thus similar in this respect to M. X. Extensive damage to the left temporal lobe seems to be the rule in these cases. On the other hand, literature indicates that damage to the occipital lobes may well produce perceptual deficits, but seems neither necessary nor sufficient to impair visual mental imagery.

Moro's et al. (2008) detailed report of two patients, with traumatic brain injury, makes a further, compelling case for this lesion correlation. Both patients had impaired visual mental imagery with reasonably preserved perception and in both cases there was an involvement of the left temporal lobe in the absence of visible damage to the occipital cortex. The reported evidence complemented the opposite dissociation (impaired perception with preserved imagery) found in patients with more posterior lesions involving the occipital lobe (Bartolomeo et al., 1998; Chatterjee and Southwood, 1995).

Another famous case of double dissociation was that of Madame D. reported in Bartolomeo et al. (1998). This brain damaged patient was severely agnostic, alexic, achromatopsic and prosopagnosic following a bilateral brain lesions in the temporo occipital sulcus, middle and inferior occipital gyri and the inferior temporal gyrus (Brodmann areas 18, 19 and 37), but her mental imagery for the same visual entities

that she could not perceive was perfectly preserved. This provides evidence that visual perception and visual mental imagery are subserved by independent functional mechanisms that do not share the same cortical areas. The location of patient's lesions at the border between the occipital and the temporal lobes would suggest that visual mental imagery is mediated by neural structures located outside the occipital section of the occipito-temporal processing stream, showing the activation of parietal and temporal association areas during visual imagery tasks.

Anterior lesions to the occipito temporal sulcus, with extensive temporal involvement, are invariably present in patients with impaired visualization of faces, colours and objects. Mental images of letters might have a different status, as they rely more heavily on subtle spatial constraints and might be used for the motor act of writing. An impairment of letter imagery might thus be expected, more than in pure alexic patients in agraphic patients with parietal lesions.

The double dissociation between perceptual and imagery abilities, with highly consistent lesion correlates, provides strong evidence against the claim that visual mental images are, as it were, "displayed" on a visual buffer consisting of topographically organized areas in the occipital lobe (see Kosslyn et al., 2006). Neuroimaging results suggest that visual mental imagery requires large networks of brain areas, including top-down influence from frontal and parietal regions to the temporal lobe (Mechelli et al., 2004). Traumatic brain injuries, like those suffered by Moro et al.'s patients, typically provoke diffuse axonal injury, which is likely to disrupt large-scale brain networks. Detailed anatomical study of future cases of imagery deficits, together with advancing knowledge of brain connectivity (Mesulam, 2005), are likely to identify more precisely the neural correlates of "the mind's eye".

5.2.3 White matter networks

Physiological studies in monkeys show that parietal and frontal areas are directly and extensively interconnected (Morecraft et al., 1993; Selemon and Goldman-Rakic, 1988) and demonstrate interdependent neural activity (Chafee and Goldman-Rakic, 2000). In humans, fMRI studies demonstrated co-activation of parietal and frontal

areas during a broad range of visual spatial tasks (Husain and Nachev, 2007). Frontoparietal white matter pathways include the superior longitudinal fasciculus (SLF), the arcuate fasciculus (AF) and shorter U-shaped cortico-cortical connections. Diffusion tensor imaging (DTI), a new technique to map the course of white matter tracts in the living human brain (Pierpaoli et al., 1996), demonstrated a similar organization of fronto-parietal pathways in humans (Catani et al., 2002; Rushworth et al., 2006; Thiebaut de Schotten et al., 2005; Thiebaut de Schotten et al., 2008).

Left unilateral neglect, a dramatic condition which impairs the awareness of left-sided events, has been classically reported after right hemisphere cortical lesions involving the inferior parietal region. More recently, the involvement of long-range white matter tracts has been highlighted, consistently with the idea that awareness of events occurring in space depends on the coordinated activity of anatomically distributed brain regions. Damages to the superior longitudinal fasciculus (SLF), linking parietal to frontal cortical regions, or to the inferior longitudinal fasciculus (ILF), connecting occipital and temporal lobes, and the inferior fronto occipital fasciculus (IFOF) a pathway running in the depth of the temporal lobe, have been described in neglect patients. In humans, the ILF originates from extrastriate occipital visual areas, fusiform and lingual gyri and cuneus. It projects to the superior, middle and inferior temporal gyri, to the uncus and parahippocampal gyrus (Catani et al., 2003). The IFOF was originally described by Curran in 1909 and subsequently demonstrated by several authors in postmortem dissections (Ludwig and Klingler, 1956; Crosby et al., 1962; Gluhbegovic and Williams, 1980) and in virtual in vivo DTI-tractography reconstructions (Catani et al., 2002; Jellison et al., 2004; Wakana et al., 2004; Kier et al., 2004). The IFOF connects the lateral and medial orbitofrontal cortex to the occipital lobe, and, at least in humans, it represents the only direct connections between occipital and frontal lobes (Catani et al., 2002, 2003). The function of the IFOF is at present unknown, however, its disconnection in the right hemisphere has been recently documented in two patients with left neglect (Urbanski et al., 2008).

Urbanski et al. (2008) recently employed DTI tractography to explore the integrity of three major caudo-rostral pathways (ILF, SLF and IFOF) in four patients with

strokes in the right hemisphere, two of whom showed signs of left neglect. The pathways were present in both hemispheres in patients without neglect; in neglect patients, however, it was not possible to track the IFOF in the right hemisphere. These results, which are the first obtained with DTI tractography in vascular patients with neglect, need to be confirmed in larger series of patients. They, however, suggest that in some cases a lesion to the direct connections between ventral occipital and frontal regions may contribute to the manifestation of neglect. This impairs the top-down modulation of visual areas from frontal cortex or the transmission of visual inputs to frontal areas, important for general arousal.

Strokes in the area of the right posterior cerebral artery can also involve signs of left neglect (Mort et al., 2003; Park et al., 2006). Interestingly, also in these patients the maximum lesion overlap seems to be situated in the white matter, in a location compatible with a white matter tract connecting the parahippocampal gyrus with the angular gyrus of the parietal lobe, possibly the ILF (Bird et al., 2006).

Finally, the uncinate fasciculus is a major white matter tract connecting the anterior temporal lobe with the medial and lateral orbitofrontal cortex (Catani et al., 2002). It is larger in the right hemisphere, indicating greater right-sided fronto-temporal connectivity (Highley et al., 2002). Although its function is not completely understood (Catani and Thiebaut de Schotten, 2008), the uncinate fasciculus is considered to belong to the limbic system, being a critical structure in emotion and memory (Gaffan and Wilson 2008), with a possible role in the formation and retrieval of episodic memories (Squire and Zola-Morgan, 1991; Levine et al., 2004; Nestor et al., 2004) and damaged in Alzheimer's disease (Yasmin et al., 2008); and to be part of a ventral language pathway (Parker et al., 2005). With regard to language, in a recent study using direct electrical stimulation in low-grade gliomas (Duffau et al., 2003), only transient language deficits were reported after uncinate fasciculus (and temporal pole) removal.

In a very recent study Papagno et al. (2010) examined 44 patients submitted to surgery for removal of a left frontal or temporal glioma. In 18 patients, the removal included the uncinate fasciculus. Authors compared patients with or without removal

on a series of neuropsychological tasks, performed at different time intervals: pre-surgery, in the first week after surgery and 3 months after surgery.

At the last examination, patients with uncinete removal were significantly impaired in naming of famous faces and objects as compared with patients without removal. In addition, on the same task, the group with a frontal glioma that underwent resection of the frontal part of the uncinete performed significantly worse than the group with a frontal glioma but without uncinete removal. In conclusion, the resection of the uncinete fasciculus, in its frontal or temporal part, has long-lasting consequences for famous face naming. Authors suggest that this fibre tract is part of a circuitry involved in the retrieval of word form for proper names. Retrieval of conceptual knowledge was intact.

5.2.4 Conclusions

Summarizing evidences show that visual perception and visual mental imagery do not share the same cortical areas, and that different imagery domains are linked to different areas in cortical regions and white matter streams.

Object imagery and recognition involve the inferior temporal gyrus, angular gyrus, inferior longitudinal fasciculus (ILF).

We have, instead, involvement of parietal and frontal areas in visual spatial domain, frontoparietal white matter pathways that include the superior longitudinal fasciculus (SLF), the arcuate fasciculus (AF), the inferior longitudinal fasciculus (ILF), and the inferior fronto occipital fasciculus (IFOF).

The region of ventral occipito-temporal cortex called the fusiform face area (FFA), the uncinete fasciculus and a network including the intraparietal sulcus (IPS) and the inferior frontal gyrus (IFG) are correlated to faces imagery.

Dorsal portion of the left inferior and middle frontal gyri, left temporo parietal region and dorsal angular gyrus are related to imagery of orthographic material.