

# Hybrid treatment of large extracranial carotid artery aneurysm

Francesca Montanari, MD,<sup>a</sup> Luigi Venturini, MD, PhD,<sup>a</sup> Iacopo Valente, MD,<sup>b</sup> Marta Minucci, MD,<sup>a</sup> Tommaso Donati, MD,<sup>a</sup> and Yamume Tshomba, MD,<sup>a</sup> Rome, Italy

## ABSTRACT

An extracranial carotid artery aneurysm (ECAA) is a rare condition. The major complications are rupture and thromboembolism. Therefore, treatment is generally recommended. We report the case of a young woman affected by an ECAA, with a cervical pulsatile mass. A multidisciplinary evaluation was performed to ensure the best treatment in terms of safety and efficacy, and the patient underwent hybrid treatment. The 6-month computed tomography angiogram revealed patency of the carotid artery stents and the venous graft, in the absence of any relevant complications. An ECAA is a serious clinical condition. The treatment is challenging, and a multidisciplinary evaluation and precise planning are recommended. (*J Vasc Surg Cases Innov Tech* 2023;9:101117.)

**Keywords:** Aneurysm; Carotid aneurysm; Carotid artery; Endovascular treatment

Extracranial carotid artery (ECA) aneurysms (ECAAs) are rare, accounting for <1% of all peripheral artery aneurysms.<sup>1</sup> They are generally silent, although a minority of patients will refer to a sensation of a pulsatile mass or neck swelling. Like most peripheral aneurysms, rupture and thromboembolism are the two major complications<sup>2</sup>; therefore, when an ECAA is diagnosed, operative treatment will generally be recommended.<sup>3-5</sup> We report a challenging case of an ECAA and its hybrid treatment. The patient provided written informed consent for the report of her case details and imaging studies.

## CASE REPORT

A 34-year-old woman was referred to our institution for the presence of an ECAA diagnosed by duplex ultrasound. The patient complained of the presence of a pulsatile mass and neck swelling in the absence of neurologic symptoms. No previous neck trauma or surgery was reported. Computed tomography angiography confirmed the diagnosis of a 29-mm ECAA originating from the proximal internal carotid artery (ICA), with an 8.5-cm extension from the carotid bifurcation (Fig 1).

Both endovascular and surgical treatment were considered as options, and, given the cranial extension of the aneurysm, a multidisciplinary discussion of the case was performed with neuroradiologists and head and neck surgeons. The first possible open strategy was excision of the aneurysm associated with a carotid artery graft through a standard cervical approach. However, the cranial extension of the aneurysm would not allow for safe control of the artery. An extracranial to intracranial carotid artery bypass and a transmandibular approach were also considered. However, these strategies were very invasive and complex and not completely acceptable to the patient. A total endovascular strategy using a covered stent was also considered, but it would have sacrificed the ECA. Moreover, few data are available about the long-term follow-up for this therapy. Consequently, a hybrid technique was chosen. This choice derived from the possibility of preserving the ECA with its collateral network, with a fair balance of the risks, invasiveness, and efficacy of the treatment.

A preoperative endovascular balloon occlusion test of the ICA was performed with negative results for an ischemic neurologic deficit.<sup>6</sup> A compensation test was performed by temporary (15-minute) inflation of the balloon microcatheter in the right ICA and injection of the left ICA. The test demonstrated poor and ineffective compensation through the anterior communicating artery, modest compensation from the posterior cerebral circulation through the posterior communicating artery, and good compensation through the branches of the ECA, mainly by flow reversal of the ophthalmic artery (Fig 2). Because of the young age of our patient and the lack of reported long-term follow-up data for total endovascular therapy, we opted for a hybrid procedure.

After mandibular subluxation, the patient underwent exposure of the carotid bifurcation and dissection of the ICA aneurysm (Fig 3). Systemic heparinization was administered. Distal clamping of the ICA was believed unfeasible owing to cranial extension of the disease and frailty of the arterial wall. Therefore,

---

From the Unit of Vascular Surgery<sup>a</sup> and Unit of Radiology and Neuroradiology,<sup>b</sup> Fondazione Policlinico Universitario A. Gemelli IRCCS, Università Cattolica del Sacro Cuore.

Author conflict of interest: none.

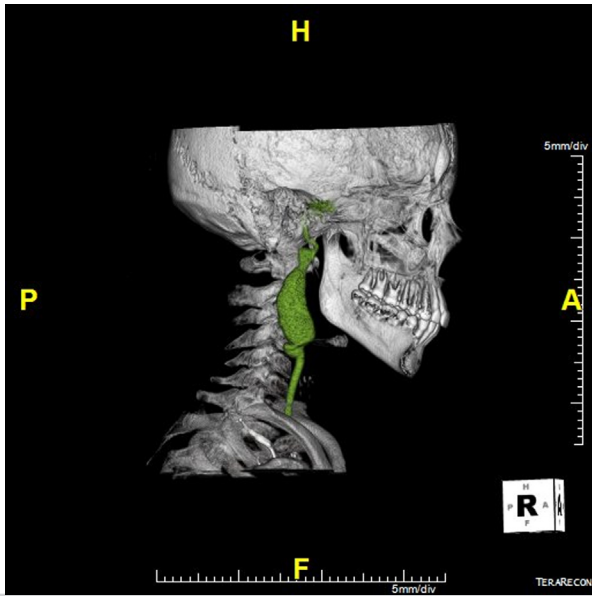
Correspondence: Francesca Montanari, MD, Unit of Vascular Surgery, Fondazione Policlinico Universitario Agostino Gemelli IRCCS, Largo A. Gemelli 8, Rome 00168, Italy (e-mail: [francesc03.montanari@gmail.com](mailto:francesc03.montanari@gmail.com)).

The editors and reviewers of this article have no relevant financial relationships to disclose per the Journal policy that requires reviewers to decline review of any manuscript for which they may have a conflict of interest.

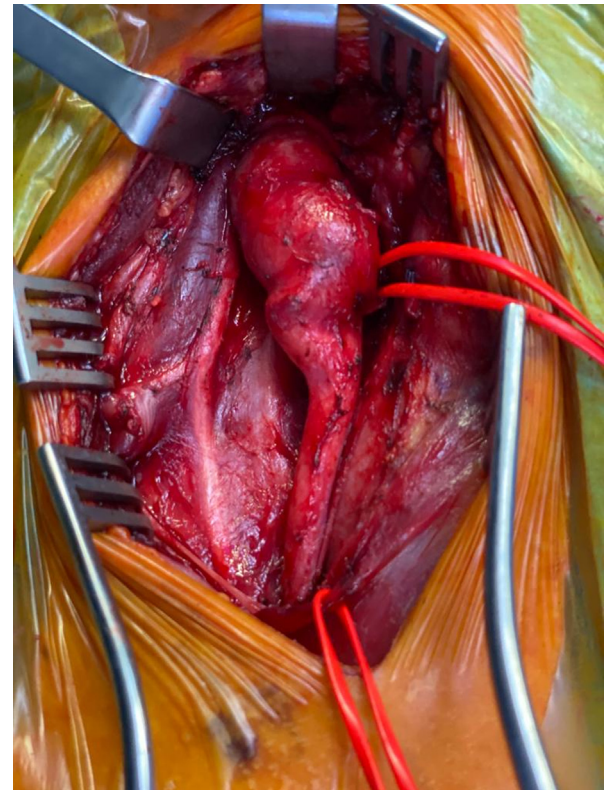
2468-4287

© 2023 The Author(s). Published by Elsevier Inc. on behalf of Society for Vascular Surgery. This is an open access article under the CC BY-NC-ND license (<http://creativecommons.org/licenses/by-nc-nd/4.0/>).

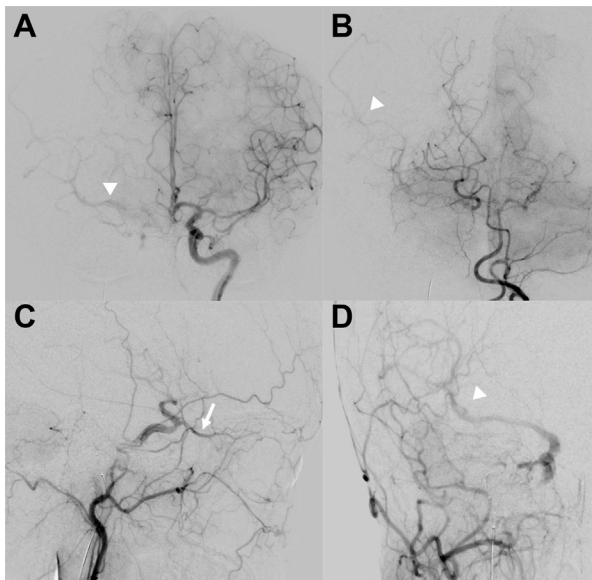
<https://doi.org/10.1016/j.jvscit.2023.101117>



**Fig 1.** Preoperative computed tomography angiogram showing an extracranial carotid artery (ECA) aneurysm (ECAA) originating from the proximal internal carotid artery (ICA) and extending from C5 to C1.



**Fig 3.** Dissection of the internal carotid artery (ICA) aneurysm after mandibular subluxation.



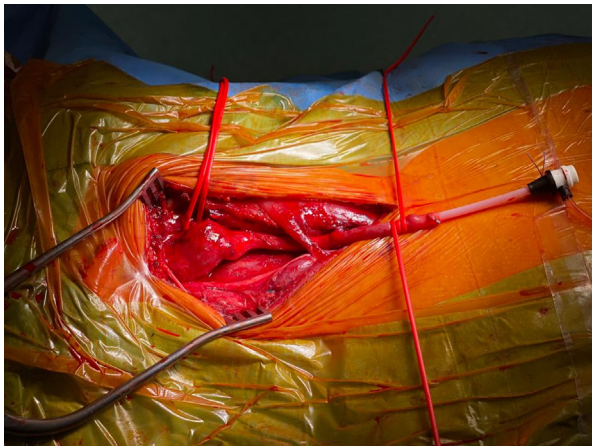**Fig 2.** A compensation test was performed by temporary (15-minute) inflation of the balloon microcatheter in the right internal carotid artery (ICA) and injection of the left ICA. The test results demonstrated poor and ineffective compensation through the anterior communicating artery (A), modest compensation from the posterior cerebral circulation through the posterior communicating artery (B), and good compensation through branches of the external carotid artery (ECA), mainly by flow reversal of the ophthalmic artery (C), and branches of the right middle cerebral artery (arrowhead) via reverse flow through the ophthalmic artery (D; arrow).

we decided to deploy a proximal stent in the common carotid artery to achieve a durable seal, with a second stent in the ICA to achieve safe exclusion of the aneurysm. For angiographic access, a 10-cm segment of the great saphenous vein was anastomosed to the common carotid artery and used as a conduit (Fig 4) to deploy two Viabahn covered stents (7 × 10 and 6 × 50, proximally and distally, respectively; W.L. Gore & Associates, Inc, Flagstaff, AZ) to exclude the aneurysm. After complete aneurysm sealing was confirmed by the completion angiogram (Video 1), the distal anastomosis of the vein graft was performed on the ECA to restore the carotid bifurcation (Fig 5) and preserve the collateral compensation documented in the preoperative tests. Finally, the aneurysm wall was sutured from the outside, with the suture reinforced with Teflon (Fig 6).

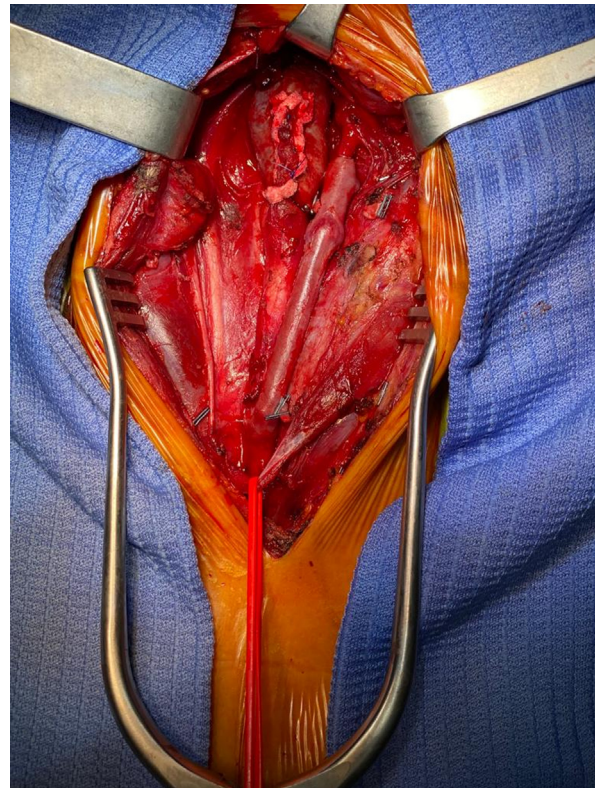
Her postoperative course was uneventful. The patient was discharged with a prescription for dual antiplatelet therapy. The findings from the 3-month duplex ultrasound scan were normal. Computed tomography angiography was performed at 6 months after the procedure, which confirmed the correct exclusion of the aneurysm and patency of both endovascular and surgical grafts (Figs 7 and 8).

## DISCUSSION

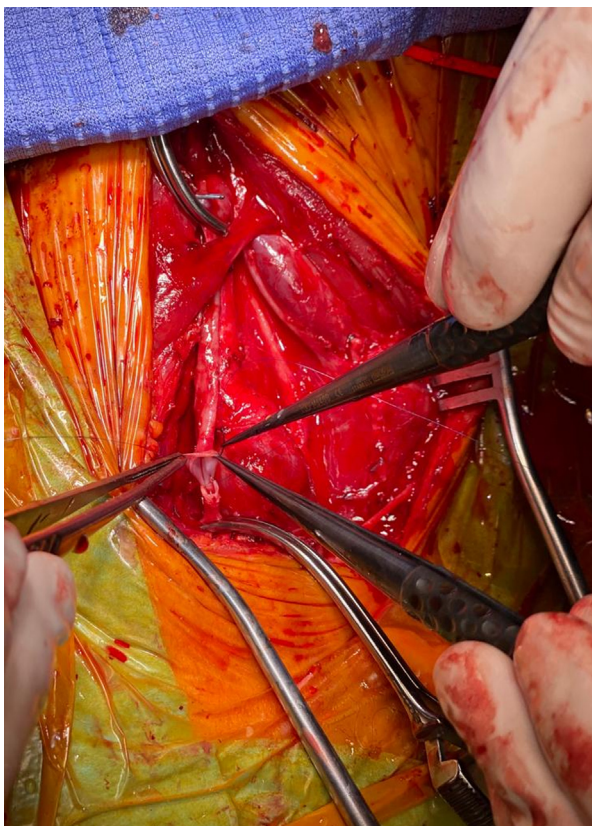An ECAA is a rare condition, accounting for just 0.6% of all arterial aneurysm procedures.<sup>7</sup> Surgical, endovascular,



**Fig 4.** The great saphenous vein was anastomosed to the common carotid artery and used as a conduit for deployment of two Viabahn covered stents (W.L. Gore & Associates, Inc, Flagstaff, AZ) to exclude the aneurysm.



**Fig 6.** Suturing of the aneurysm wall with Teflon reinforcement.



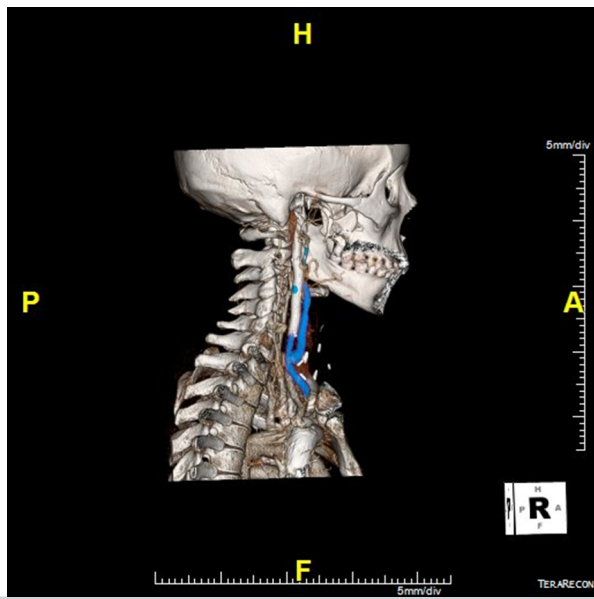
**Fig 5.** Distal anastomosis of the vein graft performed on the external carotid artery (ECA) to restore the carotid bifurcation.

and medical therapy have been proposed for asymptomatic patients; however, the optimal treatment modality has remained controversial because targeted guidelines are lacking.<sup>8</sup> Surgery is generally advocated

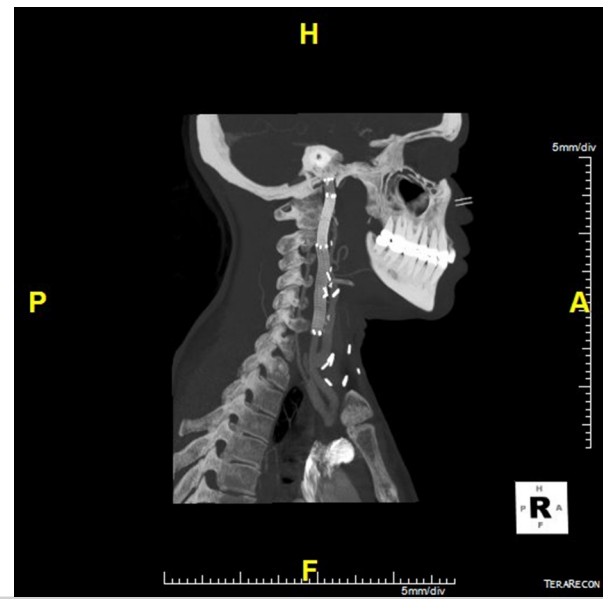
as the gold standard treatment for symptomatic patients and is considered the treatment of choice when feasible.<sup>9,10</sup> Endovascular treatment has emerged as an alternative for selected patients, with good results reported in series and case reports.<sup>11,12</sup> In particular, endovascular surgery is indicated when a very high exposure of the ICA is needed to reduce procedural difficulties and the risk of nerve injury.<sup>13</sup> A disadvantage of endovascular treatment is the risk of cerebral embolization caused by the coiling material and thrombus in the aneurysm sac.<sup>14</sup> Medical treatment consists of antiplatelet therapy, cardiovascular risk factor reduction, and duplex ultrasound follow-up. Medical therapy has been proposed for small and stable aneurysms and very frail patients.<sup>15</sup>

In our case, we decided to offer the patient hybrid treatment. We did not choose a total open procedure because of the cranial extension of the aneurysm. Also, we did not opt for a total endovascular approach, because it would have sacrificed the ECA, which could be relevant in the case of stent thrombosis.

There are many anastomoses between the ECA and ICA. They might not be evident by noninvasive imaging studies or even digital subtraction angiography in the normal condition. However, they can enlarge and become visible after ICA occlusion (especially in the case of chronic occlusion) or in high-flow states



**Fig 7.** Six-month computed tomography angiogram confirming correct exclusion of the aneurysm and patency of both endovascular and surgical grafts.



**Fig 8.** Six-month computed tomography angiogram confirming correct exclusion of the aneurysm and patency of both endovascular and surgical grafts.

(eg, arteriovenous fistulas). According to a previous classification,<sup>16</sup> two regions serve as the major extracranial–intracranial anastomotic pathways of the anterior circulation: the orbital region via the ophthalmic artery and the petrous–cavernous region via the inferolateral trunk and meningohypophyseal trunk of the ICA. The main ECA branches involved in these connections are the internal maxillary artery, superficial temporal artery, facial artery, and ascending pharyngeal artery.

We also considered an alternative approach, consisting of a temporal artery–median cerebral artery bypass with craniotomy associated with ligation of the cervical carotid artery and a bypass directed to the ECA. Given the young age of our patient, we did not choose this strategy because of its high invasiveness.

We performed a standard longitudinal cervicotomy associated with mandibular subluxation for greater exposure of the ICA. Capoccia et al<sup>17</sup> compared standard carotid endarterectomy with endarterectomy performed with mandibular subluxation and did not report significant differences in terms of the incidence of peripheral nerve injuries, despite the more extensive distal dissection in the latter group.

The open surgical approach was essential to restore the flow to the ECA with a venous bypass and remove the aneurysmal sac and, therefore, the neck mass. Completion via endovascular stenting of the common carotid artery and ICA were essential to exclude the aneurysm.

Postoperative medical therapy consisted of dual antiplatelet therapy for 6 months. After which, the patient continued with single antiplatelet therapy. Periodic post-

operative follow-up was planned, with imaging studies at 3, 6, and 12 months, followed by annually.

## CONCLUSIONS

The optimal treatment of ECAAs is controversial. A hybrid setting, if available, should be considered for all complex cases of ECAA. This will allow for a balance of the advantages of surgical and endovascular treatment in terms of invasiveness, safety, and preservation of the collateral network.

## REFERENCES

1. El-Sabroun R, Cooley DA. Extracranial carotid artery aneurysms: Texas Heart Institute experience. *J Vasc Surg* 2000;31:702-12.
2. Garg K, Rockman CB, Lee V, Maldonado TS, Jacobowitz GR, Adelman MA, et al. Presentation and management of carotid artery aneurysms and pseudoaneurysms. *J Vasc Surg* 2012;55:1618-22.
3. Attigah N, Kùlkens S, Zausig N, Hansmann J, Ringleb P, Hakimi M, et al. Surgical therapy of extracranial carotid artery aneurysms: long-term results over a 24-year Period. *Eur J Vasc Endovascular Surg* 2009;37:127-33.
4. Sharma R, Asiri A, Yamada Y, Kawase T, Kato Y. Extracranial internal carotid artery aneurysm – challenges in the management: a case report and review literature. *Asian J Neurosurg* 2019;14:970.
5. Srivastava SD, Eagleton MJ, O'Hara P, Kashyap VS, Sarac T, Clair D. Surgical Repair of carotid artery aneurysms: a 10-year, single-center experience. *Ann Vasc Surg* 2010;24:100-5.
6. Abud DG, Spelle L, Plotin M, Mounayer C, Vanzin JR, Moret J. Venous phase timing during balloon test occlusion as a criterion for permanent internal carotid artery Sacrifice. *AJNR Am J Neuroradiol* 2005;26:2602-9.
7. Zhou W, Lin PH, Bush RL, Peden E, Guerrero MA, Terramani T, et al. Carotid artery aneurysm: evolution of management over two decades. *J Vasc Surg* 2006;43:493-6.
8. Naylor AR, Ricco JB, de Borst GJ, Debus S, de Haro J, Halliday A, et al. Editor's choice – management of atherosclerotic carotid and vertebral artery disease: 2017 clinical Practice guidelines of the

- European Society for Vascular surgery (ESVS). *Eur J Vasc Endovascular Surg* 2018;55:3-81.
9. Malikov S, Thomassin JM, Magnan PE, Keshelava G, Bartoli M, Branchereau A. Open surgical reconstruction of the internal carotid artery aneurysm at the base of the skull. *J Vasc Surg* 2010;51:323-9.
  10. Venturini L, Grande R, Sapienza P, Di Marzo L. A case of saccular internal carotid artery aneurysm: is open surgery still a valid solution? *Chirurgia* 2017;30:104-6.
  11. Li Z, Chang G, Yao C, Guo L, Liu Y, Wang M, et al. Endovascular stenting of extracranial carotid artery aneurysm: a systematic review. *Eur J Vasc Endovascular Surg* 2011;42:419-26.
  12. Grandi A, Bertoglio L. EndoVascular Carotid Aneurysm Repair (EVCAR) of a type 1 carotid artery aneurysms. *Eur J Vasc Endovasc Surg* 2020;60:924.
  13. Xue S, Tang X, Zhao G, Tang H, Shen Y, Yang EY, et al. Contemporary outcomes of open and endovascular intervention for extracranial carotid artery aneurysms: a single centre experience. *Eur J Vasc Endovascular Surg* 2020;60:347-54.
  14. Martin D, Rodesch G, Alvarez H, Lasjaunias P. Preliminary results of embolization of nonsurgical intracranial aneurysms with GD coils: the 1<sup>st</sup> year of their use. *Neuroradiology* 1996;38:S142-50.
  15. Fankhauser GT, Stone WM, Fowl RJ, O'Donnell ME, Bower TC, Meyer FB, et al. Surgical and medical management of extracranial carotid artery aneurysms. *J Vasc Surg* 2015;61:389-93.
  16. Geibprasert S, Pongpech S, Armstrong D, Krings T. Dangerous extracranial-intracranial anastomoses and supply to the cranial nerves: vessels the neurointerventionalists needs to know. *AJNR Am J Neuroradiol* 2009;30:1459-68.
  17. Capoccia L, Montelione N, Menna D, Cassoni A, Valentini V, Iannetti G, et al. Mandibular subluxation as an adjunct in very distal carotid arterial reconstruction: incidence of peripheral and cerebral neurologic sequelae in a single-center experience. *Ann Vasc Surg* 2014;28:358-65.

Submitted Sep 27, 2022; accepted Jan 16, 2023.