

Long-term follow-up of adventitial cyst surgical excision in external iliac vein

Giovanni Tinelli, MD, PhD, Francesca Montanari, MD, Fabrizio Minelli, MD, Francesca De Nigris, MD, Simona Sica, MD, and Yamume Tshomba, MD, Rome, Italy

ABSTRACT

Adventitial cystic disease of the venous system is an extremely rare condition. Forty-five cases have been described in the literature during the last 70 years, but they may not be representative of the real incidence of this pathologic process. We report a case of an adventitial cyst compressing the right external iliac vein and presenting with edema of the ipsilateral leg. Ultrasound imaging and computed tomography angiography showed the typical features of cystic disease and venous stenosis. Cyst excision was performed with a double surgical access. No perioperative complications were reported. There was no recurrence at 4-year follow-up. (*J Vasc Surg Cases and Innovative Techniques* 2020;6:320-3.)

Keywords: Adventitial cystic disease; Venous cyst; External iliac vein

Venous adventitial cystic disease (ACD) is a rare condition consisting of a mucinous cyst within the venous media and adventitia. Although venous ACDs are believed to occur uncommonly, the true incidence is probably underestimated because they can be asymptomatic or misdiagnosed as deep venous thrombosis (DVT).¹ A literature review described a 45-case collection of venous ACDs reported from 1947 to 2016.²

We describe a patient with venous ACD of the external iliac vein (EIV) who underwent surgical treatment. Written informed consent was obtained from the patient for publication of this case report and accompanying images.

CASE REPORT

We report the case of a 42-year-old man presenting with non-painful edema of the right leg. There was no evidence of any other sign of thrombosis. He did not have history of trauma, malignant disease, or hypercoagulability.

On physical examination, the leg was edematous but neither tense nor flushed; no lymphadenopathy or palpable masses were appreciated. Doppler ultrasound (DUS) examination identified a relevant stenosis of the EIV (Fig 1). Further evaluation with computed tomography angiography showed a 3-cm oval mass on the medial side of the right EIV, between the inguinal

ligament and the pubic bone, causing significant focal reduction of the vessel lumen (Fig 2).

An open surgical approach was adopted, with a double access according to the cyst's location: a retroperitoneal access on the lower right quadrant to achieve distal control of the EIV and another incision below the inguinal ligament to control the common femoral vein (Fig 3). The cyst was located in the space between the inguinal ligament and the pubic bone, with evident compression of the EIV by the cyst and the adjoining iliac artery.

After cyst incision, a clear jelly fluid was evacuated, and the extravascular portion of the wall cyst was resected. Immediately after this procedure, the vein regained most of its original lumen in the absence of any wall injury. The vein was not replaced because of the particular location and the good quality of the remaining wall (Fig 4).

In the postoperative period, no complications occurred and limb edema resolved. The postoperative DUS examination showed a significant reduction of stenosis of the vein lumen. The patient was discharged on the third postoperative day. Because he had not experienced DVT, he was given only prophylactic anticoagulation (enoxaparin) for 14 days after surgical treatment.

Histologic examination of the specimen revealed a collapsed cyst in continuity with the vein wall, enveloped by a fibrous wall without endothelial lining or elastic fibers.

Postoperative follow-up consisted of a computed tomography scan at 1 month from surgery and periodic medical examination and DUS scan of the venous system of the inferior limb (before discharge; at 1 month, 3 months, 6 months, and 12 months from the intervention; and then annually). After 6 months from surgery, the patient did not describe any sign or symptom of recurrence; DUS examination confirmed the absence of recurrence, with reacquisition of most of the vein lumen. Afterward, the patient underwent periodic follow-up; the last DUS examination was carried out 4 years after treatment and did not reveal any recurrence of venous ACD (Fig 5).

DISCUSSION

Atkins and Key³ reported the first case of ACD in the external iliac artery in 1947. One of the latest reviews

From the Unit of Vascular Surgery, Fondazione Policlinico Universitario Gemelli IRCCS-Università Cattolica del Sacro Cuore.

Author conflict of interest: none.

Correspondence: Giovanni Tinelli, MD, PhD, Chirurgia Vascolare, Polo Cardio-Vascolare e Toracico, Fondazione Policlinico Universitario Gemelli IRCCS-Università Cattolica del Sacro Cuore, Largo Agostino Gemelli, 8, 00168 Rome, Italy (e-mail: giovanni.tinelli@policlinicogemelli.it).

The editors and reviewers of this article have no relevant financial relationships to disclose per the Journal policy that requires reviewers to decline review of any manuscript for which they may have a conflict of interest.

2468-4287

© 2020 The Author(s). Published by Elsevier Inc. on behalf of Society for Vascular Surgery. This is an open access article under the CC BY-NC-ND license (<http://creativecommons.org/licenses/by-nc-nd/4.0/>).

<https://doi.org/10.1016/j.jvscit.2020.04.008>

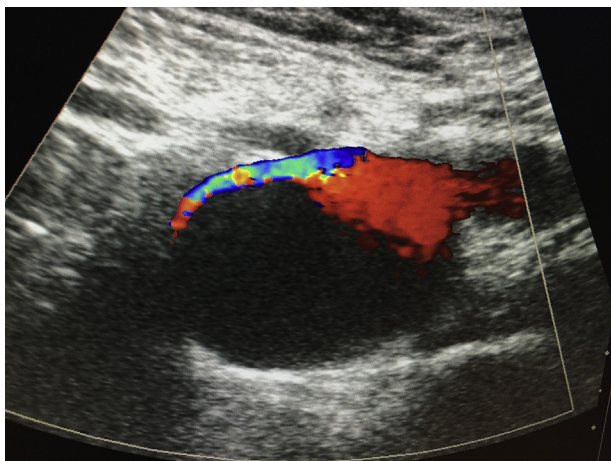


Fig 1. Preoperative ultrasound examination showing considerable stenosis of the external iliac vein (EIV), determined by the anechoic mass.

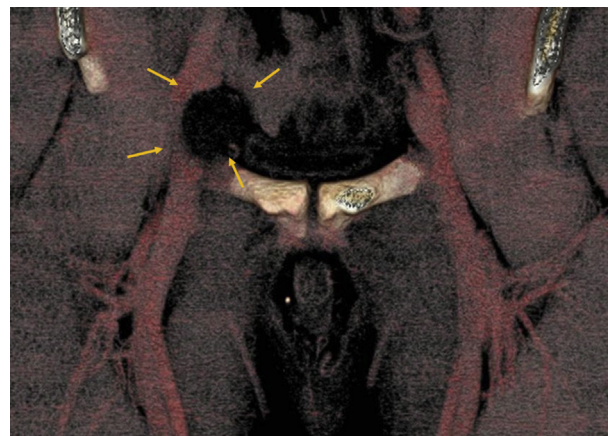


Fig 2. Computed tomography angiography scan showing the presence of an oval mass with definite borders containing homogeneous fluid and determining a relevant stenosis of the external iliac vein (EIV).

published by Chen et al⁴ in 2015 affirmed that the major involved site is the popliteal artery, whereas venous ACD is extremely uncommon and generally occurs in the common femoral vein. Venous ACD generally develops late and has a male predominance; only one case of venous ACD in children is reported.⁵

The etiology and pathogenesis of ACD are still controversial. The theories reported mainly refer to arterial ACD.⁶ The cause of venous ACD is unclear and may be different from that of arterial ACD.

According to the cyst's location, clinical presentation may differ from limb swelling or groin mass. The differential diagnosis includes DVT, femoral aneurysm or pseudoaneurysm, ganglion cyst, lipoma, malignant neoplasm, and lymphadenopathy.⁷ In our case, the cyst was located among nonsqueezable structures and leg edema was present, so the first diagnostic hypothesis was DVT.

As reported in a review by Bascone et al,² the diagnostic process begins with an accurate history and physical examination, followed by different imaging modalities. Computed tomography angiography represents the best diagnostic tool, showing the site and extent of the obstruction and allowing direct observation of the cyst with a typical scalloped aspect or hourglass narrowing caused by the extrinsic compression of the vessel lumen.

Adjunctive information derives from DUS and magnetic resonance imaging. DUS may show a hypoechoic fluid-filled cyst, accompanied by a posterior acoustic window. On magnetic resonance imaging, the cyst appears as a region of homogeneous low signal intensity on T1-weighted images and as a region of multiloculated high signal intensity adjacent to vessels on T2-weighted images.² In this case, the DUS examination clearly identified a cystic mass on the EIV, which was stenotic but still patent with anterograde accelerated flow.

The indication for treatment depends on the patient's symptoms and can rely on different options. Cysts typically tend to recur. Desy and Spinner⁶ reported that venous recurrence is less common than arterial, and as described by Paravastu et al,⁸ recurrence is more frequent after less invasive procedures, such as angioplasty and percutaneous aspiration. For this reason, the most important objective of treatment is excision of the cyst wall, preceded by transluminal or transadventitial evacuation of the cyst; a complete wall excision prevents mesenchymal cells of the mucoid cyst from remaining in the adventitia and secreting enough mucin to recur.² After resection, the vein can be replaced with either a prosthetic graft or an autologous vein. Wall excision is not feasible with percutaneous surgery, explaining the higher recurrence or persistence of the cyst.

Other reported techniques are stenting and ethanol sclerotherapy. Stenting can reduce vessel stenosis but does not treat the real cause of compression; only one case of unsuccessful venous stenting is reported in a patient with an advanced gynecologic malignant neoplasm.⁹ Ethanol sclerotherapy after percutaneous drainage is reported in a few patients with recurrent venous ACD, with good postoperative outcomes.^{10,11} This method seems a promising complementary strategy to eliminate remnant mucin-secreting mesenchymal cells after surgery.

In our case, we adopted a surgical strategy and removed about three-quarters of the cyst wall, coinciding with the extravascular part of the wall; the vein immediately reacquired most of its original lumen and did not show any wall damage. According to the particular anatomic position of the cyst, the good quality of the remaining vein wall, and the eventual need for a large-caliber graft, any replacement with a prosthetic or vein graft was performed.

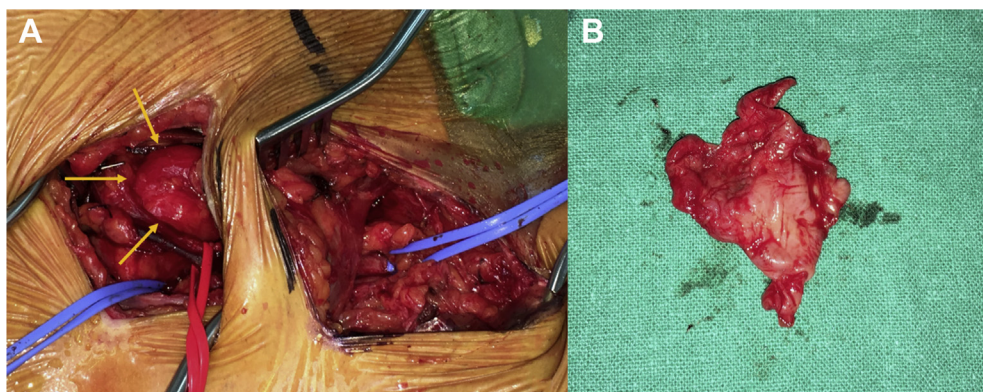


Fig 3. A, Retroperitoneal access on the right lower quadrant to achieve proximal control of the distal external iliac vein (EIV); second incision below the inguinal ligament to control the common femoral vein. **B,** Intraoperative picture of the excised venous adventitial cyst.

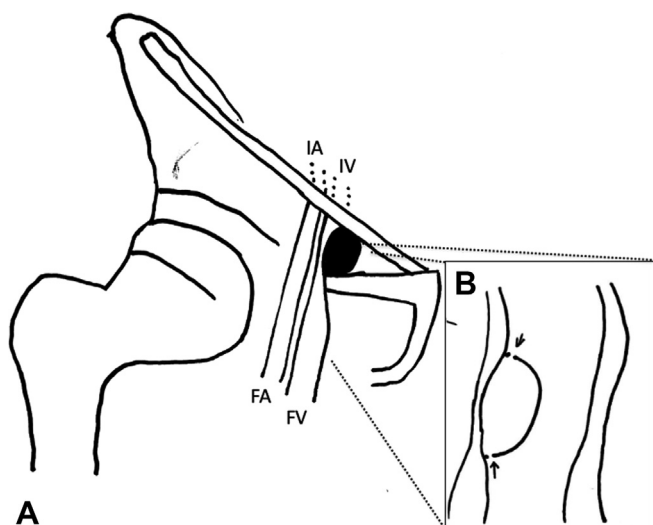


Fig 4. A, The cyst on the medial side of the right femoral vein (FV) and iliac vein (IV), between the inguinal ligament and the pubic bone. FA, Femoral artery; IA, iliac artery. **B,** Detail of the venous adventitial cyst excision.

Despite the scarce follow-up data reported, follow-up is essential to verify the absence of recurrence of the cyst. It can be performed with DUS and, eventually, with a second-level imaging tool in case of suspected recurrence. Similar to Lim et al,¹² our follow-up protocol consists of analyzing the patient at 1 month, at 6 months, and then annually. After 4 years from the procedure, our patient did not show any recurrence, and the vein maintained the lumen achieved after cyst excision.

CONCLUSIONS

Venous ACD is a rare disease and should always be considered in case of symptoms mimicking DVT. Open surgical management is the most proper option. When it is technically feasible, the complete excision of the

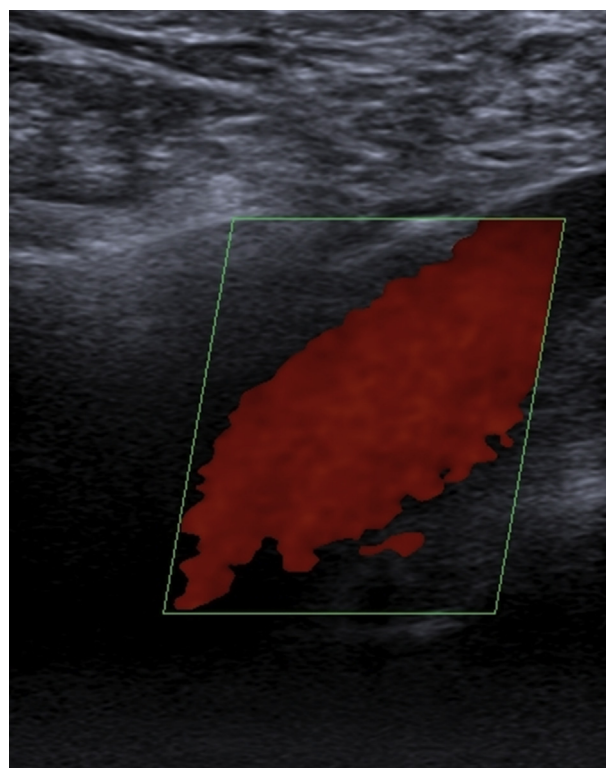


Fig 5. Doppler ultrasound (DUS) scan at 4 years of follow-up showing patency of the external iliac vein (EIV) in the absence of recurrence.

cyst's wall is safe and effective, with an acceptable recurrence rate. Periodic follow-up is crucial and can rely on noninvasive imaging, such as DUS.

REFERENCES

1. Dix FP, McDonald M, Obomighie J, Chalmers N, Thompson D, Benbow EW, et al. Cystic adventitial disease of the femoral vein presenting as deep vein thrombosis: a case report and review of the literature. *J Vasc Surg* 2006;44:871-4.

2. Bascone C, Iqbal M, Narh-Martey P, Szuchmacher M, Cicchillo M, Krishnasastry KV. Venous adventitial cystic disease: a review of 45 cases treated since 1963. *Int J Vasc Med* 2016;2016:5287697.
3. Atkins HJ, Key JA. A case of myxomatous tumour arising in the adventitia of the left external iliac artery; case report. *Br J Surg* 1947;34:426.
4. Chen Y, Sun R, Shao J, Li Y, Liu C. A contemporary review of venous adventitial cystic disease and three case reports. *Phlebology* 2015;30:11-6.
5. Jones DW, Rezayat C, Winchester P, Karwowski JK. Adventitial cystic disease of the femoral vein in a 5-year-old boy mimicking deep venous thrombosis. *J Vasc Surg* 2012;55:522-4.
6. Desy NM, Spinner RJ. The etiology and management of cystic adventitial disease. *J Vasc Surg* 2014;60:235-45.
7. Harris RW, Andros C, Dulawa LB, Oblath RW, Horowitz R. Iliofemoral venous obstruction without thrombosis. *J Vasc Surg* 1987;6:594-9.
8. Paravastu SC, Regi JM, Turner DR, Gaines PA. A contemporary review of cystic adventitial disease. *Vasc Endovascular Surg* 2012;46:5-14.
9. Priya S, Steigner M. Cystic adventitial disease involving external iliac vein: a rare cause of unilateral limb swelling. *Vasc Med* 2018;23:86-7.
10. Johnson JM, Kiankhooy A, Bertges DJ, Morris CS. Percutaneous image-guided aspiration and sclerosis of adventitial cystic disease of the femoral vein. *Cardiovasc Intervent Radiol* 2009;32:812-6.
11. Ann JH, Kim JH, Byun SS, Kang JM, Kim HS, Choi HY. Percutaneous ethanol sclerotherapy for recurrent adventitial cystic disease of external iliac vein after surgical treatment: a case report. *J Korean Surg Soc* 2015;73:384-8.
12. Lim JH, Chung BH, Kang JH, Heo SH, Kim DI, Kim YK, et al. Surgical strategy to reduce the recurrence of adventitial cystic disease after treatment. *Vasc Specialist Int* 2019;35:217-24.

Submitted Mar 25, 2020; accepted Apr 24, 2020.