

# OCT-A in the Management of Vitreoretinal Diseases and Surgery

Daniela Bacherini, MD\*†, Rodolfo Mastropasqua, MD†‡, Enrico Borrelli, MD†§, Vittorio Capuano, MD†¶, Claudio Iovino, MD†||, Francesco Dragotto, MD\*, Tomaso Caporossi, MD\*, Stanislao Rizzo, MD\*\*, and Fabrizio Giansanti, MD\*

**Abstract:** Optical coherence tomography angiography is a relatively new noninvasive technique that is changing our approach in the management of several retinal diseases such as neovascular age-related macular degeneration, occlusive retinal diseases, or diabetic retinopathy, but it could also be useful in nonprimary vascular retinal pathologies such as vitreoretinal interface surgical disorders.

In idiopathic vitreoretinal interface disorders and surgical retinal diseases, the study of vascular involvement, not commonly assessed by invasive methods, could be useful to reveal specific vascular abnormalities. Such information may be useful for a more detailed phenotyping of each clinical picture before and after surgical treatment, providing potential new prognostic biomarkers.

The review discusses the current and potential utility of optical coherence tomography angiography to study vitreoretinal pathologies of surgical interest.

**Key Words:** epiretinal macular membrane, macular hole, OCT angiography, retinal detachment, vitreoretinal interface disorders

(*Asia Pac J Ophthalmol (Phila)* 2021;10:12–19)

## INTRODUCTION

Optical coherence tomography angiography (OCT-A) represents one of the latest revolutions in retinal imaging.

In one single, fast, and noninvasive capture, not only is the information from both dynamic [dye-based angiography (fluorescein angiography and indocyanine green angiography)] and structural [optical coherence tomography (OCT)] imaging combined, but new, so-far unreported details about retinal structure are obtained.

Submitted November 26, 2020; accepted December 13, 2020.

From the \*Department of Neurosciences, Psychology, Drug Research and Child Health Eye Clinic, University of Florence, AOU Careggi, Florence, Italy; †YORIS, Young Ophthalmologists Retinal Imaging Society; ‡Institute of Ophthalmology, University of Modena and Reggio Emilia, Modena, Italy; §Division of Head and Neck, Ophthalmology Unit, IRCCS San Raffaele Scientific Institute, Vita-Salute San Raffaele University, Milan, Italy; ¶Department of Ophthalmology, Centre Hospitalier Intercommunal de Créteil, Créteil, France; ||Eye Clinic, Multidisciplinary Department of Medical, Surgical and Dental Sciences, University of Campania Luigi Vanvitelli, Naples, Italy; and \*\*UOC Oculistica, Fondazione Policlinico Universitario A. Gemelli IRCCS, Rome, Italy; Università Cattolica del Sacro Cuore, Rome, Italy; Consiglio Nazionale delle Ricerche, Istituto di Neuroscienze, Pisa, Italy.

The authors have no conflicts of interest to disclose.

Address correspondence and reprint requests to: Daniela Bacherini, Department of Neurosciences, Psychology, Drug Research and Child Health Eye Clinic, University of Florence, AOU Careggi, 50139 Florence, Italy. E-mail: daniela.bacherini@gmail.com.

Copyright © 2021 Asia-Pacific Academy of Ophthalmology. Published by Wolters Kluwer Health, Inc. on behalf of the Asia-Pacific Academy of Ophthalmology. This is an open access article distributed under the terms of the Creative Commons Attribution-Non Commercial-No Derivatives License 4.0 (CCBY-NC-ND), where it is permissible to download and share the work provided it is properly cited. The work cannot be changed in any way or used commercially without permission from the journal.

ISSN: 2162-0989

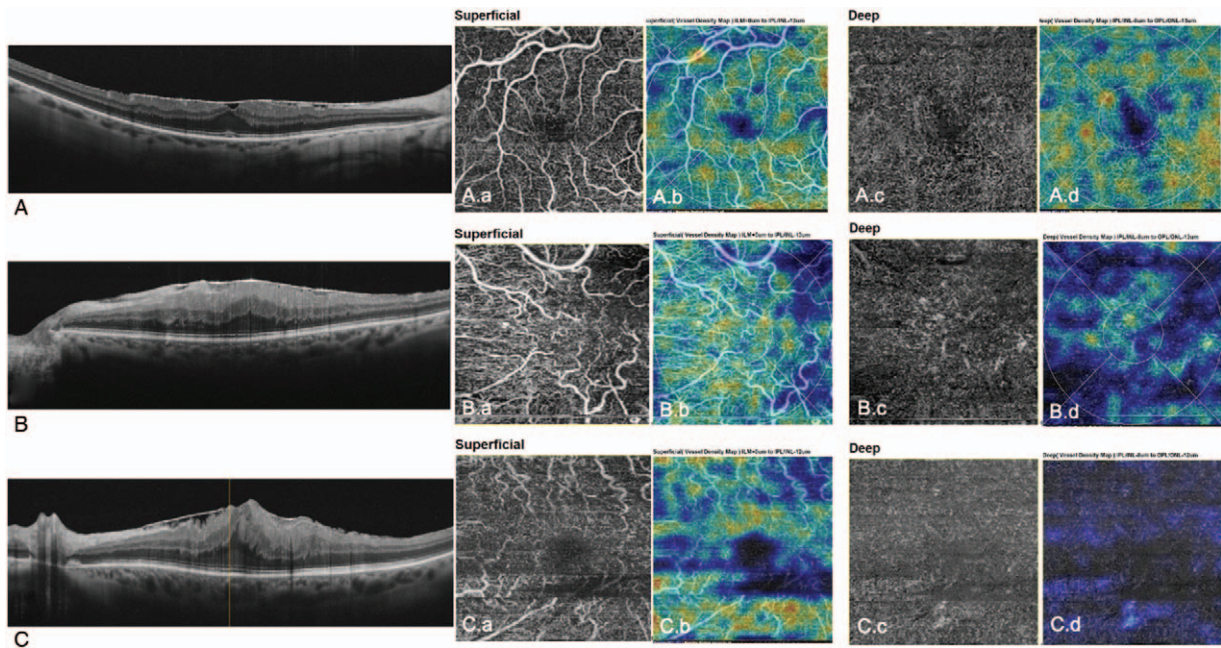
DOI: 10.1097/APO.0000000000000373

In 1961, Novotony et al<sup>1</sup> first described the technique of photography fluorescence in blood circulation in the human retina. Briefly, retinal angiography was dynamically using intravenous fluorescein dye injection. A camera equipped with an excitatory filter, a matched barrier filter in the film plane, and an electronic flash was used to sequentially document retinal blood flow. The authors described several phases of the angiogram: the arteriolar, arteriovenous, and venous phases of filling the retinal vessels. The classification of retinal diseases by Donald Gass, in particular age-related macular degeneration, was carried out using this method.<sup>2</sup> In 1971, Hochheimer<sup>3</sup> reported the first experiment using the “new” dye called indocyanine. Indocyanine dye is almost completely protein-bound (more than 95%) after intravitreal injection. Thanks to this property, diffusion through the small holes of the choriocapillaris is limited, making the indocyanine green angiography ideal to image choroidal circulation. In 1993, a new tool called OCT was developed by Fujimoto J, Huang D, Izett J, Swanson E, and Linn CP.<sup>4</sup> This noninvasive examination makes the structures and cavities of the vitreoretinal interface at the choriocapillaris junction layers visible. OCT is based on reflectance signal backscattering from chorioretinal structures. The reflectance signal provides information on variations in intrinsic tissue reflectivity. OCT-A is a functional extension of OCT. Images display flow signal rather than reflectance signal.<sup>5</sup>

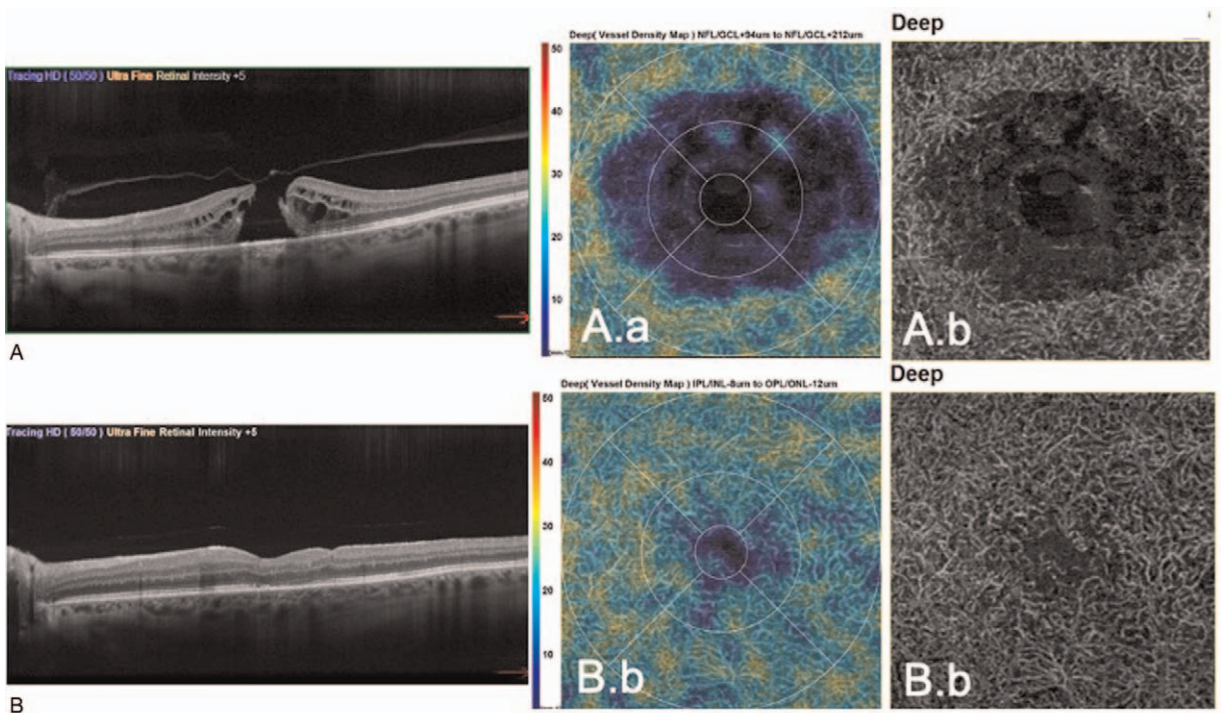
The “flow” signal is computed according to the variation of the speckle pattern between a series of consecutive OCT scans. Then the OCT-A reconstruction data become 3-dimensional, containing both the flow signal (generally seen using dye-based angiography) and the reflective signal (usually from structural OCT). Manufacturers have developed several algorithms to reconstitute this information (split-spectrum amplitude-decorrelation angiography, OCT-based microangiography) (Figs. 1 and 2).

OCT-A provides both qualitative and quantitative analysis of retinal and choroidal layers. Two main parameters are important in the interpretation of OCT-A imaging: the quantification of nonperfusion and quantification of neovascularization. The quantification of nonperfusion involves an avascular area that should normally be vascularized. The quantification of neovascularization measures the area occupied by new vessels in zones that should not normally be vascularized. Consequently, new terminology has been coined.

OCT-A can visualize retinal and choroidal vascular plexuses through a layer-by-layer analysis, allowing a separated evaluation of each plexus, which cannot be separately visualized by other imaging techniques. In fact, compared with standard fluorescein angiography, OCT-A allows a detailed evaluation of each retinal plexus including the superficial vascular plexus and the deep vascular plexus,<sup>6</sup> and makes it possible to see the choriocapillaris layer, not visible using conventional means (dye angiography or structural OCT). Therefore,



**FIGURE 1.** A, Structural B-scan OCT showing a stage 2 ERM. OCT-A of SCP (A.a) and DCP (A.c) revealing a reduction of the FAZ area. A normal vessel density of SCP (A.b) and DCP (A.d) is evident. B, B-scan OCT showing a stage 3 ERM with ectopic inner foveal layers. OCT-A of SCP (B.a) and DCP (B.c) shows a nearly absent FAZ area and a severe deformation and displacement of the vessels. A significant reduction of vessel density is detectable in the the SCP (B.b), more marked in the DCP (B.d). C, B-scan OCT of a stage 4 ERM revealing absence of the foveal pit and presence of disrupted retinal layers and ectopic inner foveal layers. OCT-A of SCP (C.a) and DCP (C.c) detects a severe deformation and displacement of the retinal vessels, with an evident vessel density reduction (C.b, C.d). A decreased vessel density perfusion in the SCP and DCP along with an increase in severity of the contraction of the ERM, as vascular density maps show. DCP indicates deep capillary plexus; ERM, epiretinal macular membrane; FAZ, foveal avascular zone; OCT, optical coherence tomography; OCT-A, optical coherence tomography angiography; SCP, superficial capillary plexus.



**FIGURE 2.** A, Structural OCT showing a full-thickness macular hole, with the corresponding vascular density map of DCP (A.a) and OCT-A of DCP (A.b). B, Structural OCT showing the closure of macular hole after surgery. Vascular density map of DCP (B.a) reveals an increase of DCP vascular density after surgery and a partial recovery of vascular texture of DCP (B.b). DCP indicates deep capillary plexus; OCT, optical coherence tomography; OCT-A, optical coherence tomography angiography.



new information can be obtained, improving our understanding of the pathogenesis of retinal diseases.

## THE ROLE OF OCT-A IN VITREORETINAL SURGICAL DISORDERS

OCT-A is changing our approach in the management of retinal diseases such as neovascular age-related macular degeneration (nAMD), permitting the detection of most of the macular neovascularization.

OCT-A is most used to evaluate neovascular diseases, occlusive retinal diseases, or diabetic retinopathy, but it could also be useful in nonprimary vascular retinal conditions such as surgical vitreoretinal interface (VRI) disorders. In these pathologies the study of vascular involvement has not commonly been assessed until now due to a lack of noninvasive methods, and because idiopathic VRI disorders are not considered vascular disorders. Nevertheless, it could be useful to reveal specific vascular abnormalities associated with or induced by the alteration of VRI. Such information may be useful for a more detailed phenotyping of each patient and a potential new classification.

Vitreomacular interface disorders are a heterogeneous group of retinal diseases with various grades of severity, capable of causing mild to severe central vision reduction. They include different disorders, such as full-thickness macular hole (FTMH), lamellar macular hole (LMH), epiretinal macular membrane (ERM), macular pseudo-hole, and vitreomacular traction.

In the early stages these disorders may be asymptomatic but their progression may lead to gradual and not completely reversible vision loss and metamorphopsia, so early detection and screening are important.

The introduction of OCT in clinical practice has dramatically increased the ability to diagnose vitreomacular abnormalities, providing subclinical information and allowing physicians to visualize, classify, and monitor the vitreomacular interface with better accuracy.<sup>7,8</sup>

Vitreomacular pathologies are a common cause of impaired vision, especially in older patients. In the United States the prevalence of vitreomacular interface pathologies has been estimated at up to 34% for ERMs and 4% for macular holes (MHs) in a cohort of elderly to very elderly people (63–102 years).<sup>9</sup> In recent years, many studies have explored the prognostic factors of their visual outcome after surgery because the functional result may be limited and not fully predictable, despite surgical success.

OCT-A can be used for these vitreomacular diseases to evaluate in a noninvasive way the vascular impairment associated with or due to the disease, and the effect of macular surgery on retinal vasculature.

The comparison of findings obtained by different and new imaging modalities like OCT-A may offer important new details to obtain prognostic information and new findings to better understand the pathogenesis of this disease.

In this review, we will evaluate the role of the new OCT-A technology to study vitreoretinal pathologies of surgical interest.

## OCT-A IN MACULAR HOLE

### OCT-A in Full-Thickness Macular Hole

A full-thickness macular hole (FTMH) is a foveal defect involving all the neuroretinal layers, from the internal limiting

membrane (ILM) to the photoreceptor layer, affecting the visual quality of patients with central visual loss and metamorphopsia. Pars plana vitrectomy (PPV) with ILM peeling provides anatomical closure in 90% to 95% of cases.

Many studies have explored preoperative factors that are predictive of visual outcomes after vitrectomy for FTMH. These factors include the stage and size of a MH,<sup>10</sup> duration of symptoms,<sup>11</sup> preoperative visual acuity,<sup>12</sup> retinal sensitivity, and status of fixation.<sup>13</sup> OCT findings may also be predictive factors for MH resolution, including the minimum diameter of the MH, the basal hole diameter, the hole form factor, the MH index, and inner segment/outer segment junction defect length.<sup>14</sup> However, these factors cannot accurately predict postoperative visual outcomes. The symptom duration and the hole size are widely considered helpful for predicting visual outcomes after MH surgery, but the results vary across studies and the visual outcomes are often worse than expected despite successful anatomical MH surgery.

Several studies have reported vascular changes and the quantitative characteristics of OCT-A images in eyes with MH, considering this new technique to be a useful tool for the assessment of MHs before and after surgical treatment.<sup>15</sup>

Segmentation is one of the main issues in OCT-A interpretation, and in the case of FTMH, the automatic segmentation using the software may not be correct, due to the presence of cysts.

Michalewska et al<sup>16</sup> described image artifacts that may occur in swept-source OCT-A imaging of FTMH; a “jellyfish-like” appearance is visible in some patients where there are cystoid spaces at the margins of the MH, they are represented as the “jellyfish digestive canals” and no flow can be detected in them. Thus, OCT-A results must be evaluated very carefully.

In FTMH presurgical evaluation, OCT-A reveals that the most significant retinal vascular alterations correspond mainly to the deep capillary plexus (DCP). In this plexus, small, circular, hyporeflexive cystoid cavities are present surrounding the MH in the inner nuclear layer, whereas elongated radial hyporeflexive cavities forming a stellar pattern are observed in the outer plexiform/Henle fiber layer complex. The retina surrounding the cystoid spaces preserves circulation, as shown by OCT-A, and the retinal vascular structure surrounding the cystoid spaces is involved in a “vascular sliding” at the border of the cavities.<sup>17</sup> The same study observed on the choroidal layers a circular area of a peak signal corresponding to a window defect, due to the absence of neuroretinal tissue that made the choriocapillaris visible.

Pierro et al<sup>18</sup> compared the various types of MHs and observed that FTMHs have the highest DCP vascular density (VD) hypothesizing a vascular engorgement, probably due to the tangential tractional forces and the steepening of the MH edges.

A prospective study reported a combined evaluation of structural findings (OCT, en-face OCT) and functional parameters obtained by the integration of OCT-A and microperimetry in patients with FTMH. Absolute scotomas were observed corresponding to the FTMH. Additionally, rings of relative scotoma in the perilesional area were detected and correlated to the cystic spaces on en-face OCT and OCT-A. There was a significant correlation between reduced retinal sensitivity at 2° and 4° diameters around the FTMH and the extension of cystic areas, and there was a significant correlation between the extension of cystic cavities and best-corrected visual acuity (BCVA). This integrated evaluation of FTMH may be useful to determine the function–structure correlation before and after vitreoretinal

surgery, to gain a better understanding of the functional consequences induced by the morphological alterations, assessing outcomes in a more objective way and potentially adding new surgical prognostic factors.<sup>19</sup>

Several studies show that deep vascular plexus is the layer more influenced by the effect of vitrectomy and ILM peeling for FTMH surgery. Michalewska et al<sup>20</sup> observed that ILM peeling alters deep retinal vasculature below the area of the peeling.

A recent article<sup>21</sup> reported that assessment of macular capillary plexuses after MH surgery using OCT-A may be helpful for monitoring retinal structural and functional changes in MH.

Patients after MH surgery had a smaller foveal avascular zone (FAZ) area in both superficial capillary plexus (SCP) and DCP compared with fellow eyes, and the FAZ area was positively correlated with postoperative foveal thickness. In the parafoveal region, eyes after MH surgery had a tendency to have lower parafoveal VD, particularly in the DCP, and the parafoveal VD in the DCP was positively correlated with retinal thickness of the whole, inner, and outer layers. Correlations between BCVA and FAZ area in both SCP and DCP were significant 6 months after MH surgery<sup>20</sup>.

A vascular remodeling of retinal network pattern has been hypothesized as related to morphologic changes in the inner retinal layer and it has been found in surgically closed MH eyes. Asymmetric changes in the inner retinal anatomy and hemodynamics may involve the postoperative healing process.<sup>22</sup>

Baba et al<sup>23</sup> noted that retinal cells were no longer in their original position after surgery; they found an increase in the SCP and DCP vessel density in the nasal macular area and a reduction in the temporal area 12 months postoperatively, and postulated a nasal shift of the retina.

After MH closure, Baba et al showed that the FAZ area was significantly smaller than the unaffected fellow eye. Its decrease occurred especially in the superficial FAZ and may indicate that there is a centripetal movement of the foveal tissue postoperatively.

Recently, Tsuboi et al<sup>24</sup> noted that after an early postoperative reduction of the FAZ area with MH closure, it thereafter increased toward the normal value over time. In addition, postoperative FAZ area enlargement was positively correlated with the photoreceptor recovery and visual acuity change. Therefore, FAZ enlargement may be a potential biomarker indicating foveal reconstruction after MH closure.

Moreover, the choriocapillaris could be affected by FTMH. A recent study<sup>25</sup> showed that the macular choriocapillary flow area and parafoveal vessel density in idiopathic MH eyes were lower than those of normal controls, with an increase of these values 1 month after vitrectomy. Choriocapillary circulation measurements were negatively correlated with MH diameters in MH eyes.

Caporossi et al evaluated a new technique using a human amniotic membrane (hAM) plug to promote failed MH closure. In non-high-myopic hAM-treated patients, OCT-A showed no statistical difference in deep vascular density between treated eyes and fellow eyes, whereas the superficial vascular density showed a statistically different lower density compared with fellow non-treated eyes, suggesting a trophic-like effect of hAM on DCP.<sup>26</sup> No differences in the FAZ of hAM-treated eyes, compared with that of fellow eyes, were detected: the authors hypothesized that the hAM plug does not induce a centripetal movement of the

tissues, which can lead to a reduction in the foveal area, as has been instead supposed for ILM peeling.<sup>20</sup> The increase in visual acuity was moderately related to increased vascularization of the parafoveal segments in the group of nonmyopic eyes.

### OCT-A in Lamellar Macular Hole

A lamellar macular hole (LMH) is a partial interruption of the retinal tissue; it has been shown that this VRI disorder can be categorized into 2 subgroups: tractional and degenerative with different etiologies and prognosis.

Yeo et al<sup>27</sup> compared LMH eyes with their fellow eyes; those with tractional LMH had a smaller FAZ area, higher foveal VD, and lower parafoveal VD in both the SCP and the DCP. Degenerative LMH had lower parafoveal VD in both plexuses. Foveal and parafoveal VDs in the SCP of eyes with tractional LMH increased significantly at 6 months postoperatively, whereas eyes with degenerative LMH did not show such changes. To explain these findings, they put forward the hypothesis that removing the ERM over tractional LMHs permits the restoration of the microvascular network. However, the absence of an increase of VD suggests that the traction forces exerted by the ERM in degenerative LMH may be different from those in tractional LMH, and that the ERM may not play a leading role in the pathophysiology of degenerative LMH.

Moreover, foveal VDs in both plexuses and parafoveal VD in the SCP were significantly correlated with BCVA in eyes with degenerative LMH, suggesting that a relative hypoperfusion in the DCP may decrease the integrity of photoreceptors, resulting in worse BCVA. Yeo et al presumed that OCT-A can provide new insights and biomarkers of visual prognosis in patients with degenerative LMH.

To summarize, OCT-A in MH provides better insights into its physiopathology and its natural history, assessing that macular vascularization can be an important clue to understand the differences between different types of MHs or between MHs of the same group but with a different functional recovery. Correlations among OCT-A parameters and visual recovery are increasing; with further studies, OCT-A could become an important tool in the routine assessment of patients affected by MH, and to help establish the correct timing in this kind of elective surgery.

### OCT-A in Epiretinal Macular Membrane

An epiretinal macular membrane (ERM) is a retinal disorder characterized by the development of abnormal tissue on the macular surface.<sup>28</sup> Although ERM may be idiopathic, ocular disorders such as diabetic retinopathy and retinal vein occlusion may also be complicated by the development of ERM.<sup>29–31</sup> Regarding the idiopathic form of ERM, the etiology is still debated, although evidence suggests that retinal glial cells may proliferate and migrate over the macular surface after an anomalous posterior vitreous detachment.<sup>32,33</sup> Idiopathic ERM represents a frequent cause of visual damage as adhesions on the retinal surface may cause the development of retinal folds and retinal thickening.<sup>34,35</sup>

The introduction of OCT-A has significantly improved knowledge of ERM, as this imaging modality gives a detailed evaluation of the retinal vasculature in eyes with ERM. Using OCT-A, Baba et al investigated the size of the FAZ in eyes with idiopathic ERM.<sup>34</sup> They enrolled 17 patients (17 eyes) undergoing PPV with ILM peeling. The authors showed that the FAZ was

smaller in eyes with ERM and this reduction in size was still present 12 months after surgery. Kim et al<sup>21</sup> enrolled 43 patients with unilateral ERM. In this study the authors showed that eyes with ERM had a lower vascular perfusion and a smaller FAZ after surgery. More importantly, greater interocular differences in the FAZ area and parafoveal VD were significantly associated with worse postoperative outcomes. Mastropasqua et al<sup>36</sup> also described in detail microvascular changes occurring in eyes with ERM after vitrectomy and ILM peeling. Notably, the latter study provided a topographical characterization of these microvascular changes. After surgery, a reduction in vascular perfusion was noted in these eyes and this contraction was recorded in regions colocalizing with the arcuate nerve fiber layer. The authors speculated that vascular modifications may be secondary to the direct surgical trauma to the inner retina during the ILM grasping. In a following article, Mastropasqua et al<sup>37</sup> performed a detailed imaging analysis of patients with idiopathic ERM undergoing vitrectomy with ILM peeling, who were followed up for 6 months after surgery. Importantly, the authors found an increase in vessel length density after surgery, which was speculated to be secondary to a reopening of little vessels that were suboccluded before surgery due to ERM traction.

### OCT-A in Retinal Detachment

Pars plana vitrectomy and scleral buckle are well-established and effective procedures for the treatment of primary rhegmatogenous retinal detachment (RRD), achieving a primary anatomical success rate of 84% to 96%.<sup>38–41</sup> Despite this, incomplete postoperative visual acuity recovery and subjective symptoms such as persistent metamorphopsia and color vision defects are often reported, mainly in macula-off RRD. The retinal morphology usually appears relatively normal after retinal reattachment, suggesting microstructural changes in the macula. Conventional OCT permits the detection of microscopic abnormalities that can affect the functional outcome of surgery; these comprise cystoid macular edema, the persistence of subretinal fluid, the presence of retinal folds, the lack of integrity of the external limiting membrane or the photoreceptor inner and outer segment junction, and the development of an ERM.<sup>42–44</sup> However, sometimes there is a suboptimal functional result despite the absence of any of the mentioned findings.

The hypothesis that vascular damage may be implied in the pathogenesis of visual impairment after RRD repair has been the subject of study. In the last decades, the use of fluorescein angiography has revealed anomalies in the retinal perfusion of patients with RRD. A study showed that the retinal circulation times were increased in the detached area compared with the adjoining attached area.<sup>45</sup> Another study showed that RRD leads to vascular dilation and hyperpermeability because of tissue hypoxia.<sup>46</sup> The introduction of OCT-A has opened a new scenario in the investigation of macular microstructural abnormalities after RRD repair. Recent publications have studied changes in the FAZ, SCP, and DCP vessel density, the choriocapillaris plexus, and their potential correlation with BCVA.

The FAZ is an area that lacks retinal vessels and has the highest concentration of cone photoreceptors, being responsible for the central vision. In a 2-month follow-up study, Woo et al found that the FAZ area measured in the DCP was larger in cases with macula-off RRD (19 eyes) than in macula-on RRD (15 eyes) and fellow healthy eyes.<sup>47</sup> The authors suggested that DCP may

be vulnerable to tissue hypoxia and the increase in the FAZ may indicate the severity of macular ischemia. They speculate that when RRD occurs, oxygen delivery from the choriocapillaris to the DCP can be markedly inhibited by subretinal fluid.

Accordingly, Agarwal et al<sup>48</sup> reported a larger FAZ area in a series of 19 macula-off cases at the 3-month follow-up. This result was associated with a reduction of capillary density and fractal dimension.

In contrast with these publications, Bonfiglio et al<sup>49</sup> reported long-term follow-up data of 93 cases (56 macula-on, 37 macula-off). Compared with the healthy fellow eyes, they did not find significant changes in terms of the FAZ. However, they found significantly lower parafoveal DCP vascular density in the macula-on group. On the other hand, they found a significantly lower parafoveal DCP VD, a lower parafoveal SCP VD and lower foveal and parafoveal DCP VD in the macula on group. In a prospective series of 28 macula-off RRD, Tsen et al described the reduction of both SCP vascular density and DCP vascular density in RRD eyes compared with the fellow eye at the 3-month follow-up. Interestingly, they found a significant association between the presence of preoperative intraretinal separation and postoperative enlargement of the FAZ area.<sup>50</sup>

The pathogenesis of vessel density decreases after retinal detachment is uncertain. A mechanism based on hypoxia and inflammation seems to be the trigger: the accumulation of subretinal fluid in the detached retina is associated with an increase of inflammatory and vascular mediators, which could lead to retinal vascular damage.<sup>51</sup> Another hypothesis is an inflammation-related activation of Muller cells. The latter were shown to be related to blood flow alterations in the inner retina; therefore, a reduction in vessel density may be a direct consequence.<sup>52</sup>

Data regarding a potential correlation between the FAZ area and BCVA are controversial. Woo et al<sup>47</sup> showed that the FAZ measured on both the SCP and the DCP is correlated negatively with BCVA in macula-off patients, whereas Yui et al<sup>53</sup> reported this correlation only for the FAZ on SCP (27 macula-off eyes, 3-month follow-up). Bonfiglio et al<sup>49</sup> found a correlation between the BCVA, FAZ, and parafoveal deep vascular density in the macula-on group and between the BCVA, FAZ, foveal superficial vascular density, and parafoveal deep vascular density in the macula-off group. On the contrary, in a retrospective study of 22 macula-off RRD, Sato et al reported that the superficial and deep FAZ were not correlated with postoperative BCVA at the 1-, 3-, and 6-month follow-ups.<sup>54</sup> Similarly, in a series of 31 patients (11 macula-on, 20 macula-off), Hong et al<sup>55</sup> did not find any correlation between the FAZ area and BCVA at the 6-month follow-up. Of note, the same study found that the choriocapillaris plexus vessel density was significantly reduced in those eyes which showed defects in the outer layer at the swept-source OCT, and this was significantly correlated with visual outcomes in macula-off RRD.<sup>56</sup>

To conclude, in macula-on retinal detachment, the vascular damage seems to be limited to the superficial plexus, whereas both superficial and deep plexuses are affected in macula-off retinal detachment. The FAZ area often results enlarged after successful surgery, but the importance of this on visual recovery is uncertain. The discrepancy between the studies is probably caused by different factors: different numbers of patients included in the studies, follow-up periods, characteristics of study participants, and different OCT-A machines and parameters.



Current literature does not show evidence of significant differences in terms of OCT-A findings between PPV and scleral buckle.<sup>45,47</sup> All the studies published on PPV refer to cases treated exclusively with gas tamponade. In 2020, Lee et al provided evidence that the use of silicone oil for the treatment of RRD causes alteration in the macular microvascular structure. In a 3-month follow-up retrospective study (38 eyes, 11 macula-on and 27 macula-off), they found an enlargement of the FAZ and reduction of DCP vascular density compared with the contralateral eye. Interestingly, these results were correlated with the duration of silicone oil tamponade.<sup>56</sup> Prospective comparative studies are required to investigate whether the use of silicone oil implicates a higher vascular alteration than gas tamponade.

### OCT-A in Other Vitreoretinal Disorders

OCT-A has been successfully employed to investigate the reperfusion of translocated retinal pigment epithelium–choroid graft in the treatment of 18 patients with nAMD.<sup>57</sup> Perfusion of the graft tissue after surgery was confirmed in all patients associated with a mean gain of visual acuity of 30 letters. The authors found the OCT-A flow analysis of the graft to be much more reproducible if compared with conventional angiography due to its ability to reveal the laminar structure of the blood supply of the retina and choroid.<sup>54</sup>

Similarly, Rizzo et al analyzed the retinal vascularization after subretinal amniotic membrane implantation in patients with atrophic AMD and nAMD, reporting an increase of VD in the DCP that correlated to the BCVA.<sup>58</sup> The authors postulated that the DCP is the plexus that is primarily affected in vascular macular diseases, perhaps because it is directly connected to arterioles and may have higher perfusion pressure than the SCP.

Swept-source OCT-A patterns predicting outcome in patients with optic disc pit–associated maculopathy have also been investigated.<sup>59</sup> Authors showed how stuffing of the optic disc pit with the ILM results in improvement of anatomic and functional results. Additionally, postoperative increase in size of the FAZ in the SCP and more pronounced in eyes with intraretinal fluid at baseline were associated with a prolonged postoperative anatomic recovery.

### CONCLUSIONS

OCT-A could be useful to evaluate retinal and choroidal vasculature in a rapid and noninvasive way and can be performed at the same time as structural OCT. Thanks to its easy handling and safety, it can also be used to study retinal pathologies without vascular etiology such as idiopathic VRI syndromes, to better define their etiology, understand further pathogenic aspects, and provide new vascular findings associated with these surgical pathologies.

Since vitreoretinal surgery is an elective procedure, it becomes increasingly important to provide preoperative prognostic biomarkers and adequate patient information. Vascular retinohoroidal layers may influence a postoperative outcome and OCT-A potentially helps establish a correct surgical timing.

Further studies are necessary to define the exact role and the clinical usefulness of OCT-A in the routine assessment of patients affected by VRI disorders.

Moreover, a morphofunctional analysis of vitreoretinal surgical diseases and the correlation between vascular abnormalities

and impaired retinal sensitivity may provide useful, new information. The integration of structural and functional techniques, in fact, may provide novel data, which may be important to evaluate preoperative and postoperative function.

It could also be useful to evaluate morphofunctional restoration using functional analysis such as microperimetry and OCT-A after surgery. This integrated evaluation of VRI surgical disorders and the noninvasive assessment of vascular involvement would be a useful tool to identify changes in microcirculation before and after vitreoretinal surgery, correlating them to functional changes to study useful potential prognostic factors.

### REFERENCES

- Novotony HR, Alvid DL. A method of photographing fluorescence in circulating blood in the human retina. *Circulation*. 1961;24:82–86.
- Gass JD. Pathogenesis of disciform detachment of the neuroepithelium. *Am J Ophthalmol*. 1967;63(3 suppl):1–139.
- Hochheimer BF. Angiography of the retina with indocyanine green. *Arch Ophthalmol*. 1971;86:564–565.
- Kim DY, Fingler J, Zawadzki RJ, et al. Optical imaging of the chorioretinal vasculature in the living human eye. *Proc Natl Acad Sci U S A*. 2013;110:14354–14359.
- Savastano MC, Lumbroso B, Rispoli M. In vivo characterization of retinal vascularization morphology using optical coherence tomography angiography. *Retina*. 2015;35:2196–2203.
- Duker JS, Kaiser PK, Binder S, et al. The international vitreomacular traction study group classification of vitreomacular adhesion, traction, and macular hole. *Ophthalmology*. 2013;120:2611–2619.
- Stevenson W, Prospero Ponce CM, Agarwal DR, et al. Epiretinal membrane: optical coherence tomography–based diagnosis and classification. *Clin Ophthalmol*. 2016;10:527–534.
- Meuer SM, Myers CE, Klein BEK, et al. The epidemiology of vitreoretinal interface abnormalities as detected by spectral domain optical coherence tomography: The Beaver Dam Eye study. *Ophthalmology*. 2015;122:787–795.
- Ulrich S, Haritoglou C, Gass C, et al. Macular hole size as a prognostic factor in macular hole surgery. *Br J Ophthalmol*. 2002;86:390–393.
- Stec LA, Ross RD, Williams GA, et al. Vitrectomy for chronic macular holes. *Retina*. 2004;24:341–347.
- Kusuhara S, Negi A. Predicting visual outcome following surgery for idiopathic macular holes. *Ophthalmologica*. 2013;231:125–132.
- Sun Z, Gan D, Jiang C, et al. Effect of preoperative retinal sensitivity and fixation on long-term prognosis for idiopathic macular holes. *Graefes Arch Clin Exp Ophthalmol*. 2012;50:1587–1596.
- Ruiz-Moreno JM, Staicu C, Piñero DP, et al. Optical coherence tomography predictive factors for macular hole surgery outcome. *Br J Ophthalmol*. 2008;92:640–644.
- Wilczyński T, Heinke A, Niedzielska-Krycia A, et al. Optical coherence tomography angiography features in patients with idiopathic full-thickness macular hole, before and after surgical treatment. *Clin Interv Aging*. 2019;14:505–514.
- Bacherini D, De Luca M, Rizzo S. Optical coherence tomography angiography in vitreoretinal interface disorders. *Minerva Ophthalmol*. 2018;60. doi:10.23736/s0026-4903.18.01807-x.
- Michalewska Z, Nawrocki J. Swept-source OCT angiography of full-thickness macular holes: appearance and artifacts. *Ophthalmic Surg Lasers Imaging Retin*. 2018;49:111–121.

17. Rizzo S, Savastano A, Bacherini D, et al. Vascular features of full-thickness macular hole by OCT angiography. *Ophthalmic Surg Lasers Imaging Retina*. 2017;48:62–68.
18. Pierro L, Rabiolo A, Iuliano L, et al. Vascular density of retinal capillary plexuses in different subtypes of macular hole. *Ophthalmic Surg Lasers Imaging Retin*. 2017;48:648–654.
19. Bacherini D, Savastano MC, Dragotto F, et al. Morphofunctional evaluation of full-thickness macular holes by OCT angiography. *Ophthalmic Surg Lasers Imaging Retina*. 2017;48:62–68.
20. Michalewska Z, Nawrocki J. Swept-source optical coherence tomography angiography reveals internal limiting membrane peeling alters deep retinal vasculature. *Retina*. 2018;38(suppl 1):S154–S160.
21. Kim YJ, Jo J, Lee JY, et al. Macular capillary plexuses after macular hole surgery: an optical coherence tomography angiography study. *Br J Ophthalmol*. 2018;102:966–970.
22. Hashimoto Y, Saito W, Fujiya A, et al. Changes in inner and outer retinal layer thicknesses after vitrectomy for idiopathic macular hole: implications for visual prognosis. *PLoS One*. 2015;10:1–12.
23. Baba T, Kakisu M, Nizawa T, et al. Regional densities of retinal capillaries and retinal sensitivities after macular hole surgery with internal limiting membrane peeling. *Retina*. 2020;40:1585–1591.
24. Tsuboi K, Fukutomi A, Sasajima H, et al. Visual acuity recovery after macular hole closure associated with foveal avascular zone change. *Trans Vis Sci Tech*. 2020;9:20. doi:10.1167/tvst.9.8.20.
25. Ahn J, Yoo G, Kim JT, et al. Choriocapillaris layer imaging with swept-source optical coherence tomography angiography in lamellar and full-thickness macular hole. *Graefes Arch Clin Exp Ophthalmol*. 2018;256:11–21.
26. Caporossi T, Pacini B, Bacherini D, et al. Human amniotic membrane plug to promote failed macular hole closure. *Sci Rep*. 2020;10:18264.
27. Yeo JH, Oh R, Lee JY, et al. Optical coherence tomography angiographic findings of lamellar macular hole: comparisons between tractional and degenerative subtypes. *Sci Rep*. 2020;10:1–9.
28. Inoue M, Kadonosono K. Macular diseases: epiretinal membrane. *Dev Ophthalmol*. 2014;54:159–163.
29. McCarty DJ, Mukesh BN, Chikani V. Prevalence and associations of epiretinal membranes in the visual impairment project. *Am J Ophthalmol*. 2005;140:288–294.
30. Carpineto P, Ciciarelli V, Borrelli E, et al. Epiretinal membrane in eyes with vitreomacular traction. *Retina*. 2019;39:1061–1065.
31. Smiddy WE, Maguire AM, Green WR, et al. Epiretinal membranes: ultrastructural characteristics and clinicopathologic correlation. *Ophthalmology*. 1989;96:811–820.
32. Miyazaki M, Nakamura H, Kubo M, et al. Prevalence and risk factors for epiretinal membranes in a Japanese population: the Hisayama study. *Graefes Arch Clin Exp Ophthalmol*. 2003;241:642–646.
33. Guber J, Pereni I, Scholl HPN, et al. Outcomes after epiretinal membrane surgery with or without internal limiting membrane peeling. *Ophthalmol Ther*. 2019;8:297–303.
34. Baba T, Kakisu M, Nizawa T, et al. Study of foveal avascular zone by OCT-A before and after idiopathic epiretinal membrane removal. *Spektrum der Augenheilkd*. 2018. doi:10.1007/s00717-017-0375-4.
35. Kim YJ, Kim S, Lee JY, et al. Macular capillary plexuses after epiretinal membrane surgery: an optical coherence tomography angiography study. *Br J Ophthalmol*. 2018;102:1086–1091.
36. Mastropasqua L, Borrelli E, Carpineto P, et al. Microvascular changes after vitrectomy with internal limiting membrane peeling: an optical coherence tomography angiography study. *Int Ophthalmol*. 2017;38:1465–1472.
37. Mastropasqua R, D'Aloisio R, Viggiano P, et al. Early retinal flow changes after vitreoretinal surgery in idiopathic epiretinal membrane using swept-source optical coherence tomography angiography. *J Clin Med*. 2019;8:2067.
38. Heimann H, Hellmich M, Bornfeld N, et al. Scleral buckling versus primary vitrectomy in rhegmatogenous retinal detachment (SPR Study): design issues and implications. *SPR Study report no 1 Graefes Arch Clin Exp Ophthalmol*. 2001;239:567–574.
39. Jackson TL, Donachie PH, Sallam A, et al. United Kingdom National Ophthalmology Database study of vitreoretinal surgery: report 3, retinal detachment. *Ophthalmology*. 2014;121:643–648.
40. Kobashi H, Takano M, Yanagita T, et al. Scleral buckling and pars plana vitrectomy for rhegmatogenous retinal detachment: an analysis of 542 eyes. *Curr Eye Res*. 2014;39:204–211.
41. Begaj T, Marmalidou A, Papakostas TD, et al. Outcomes of primary rhegmatogenous retinal detachment repair with extensive scleral-depressed vitreous removal and dynamic examination. *PLoS One*. 2020;15:e0239138.
42. Lecleire-Collet A, Muraine M, Ménard JF, et al. Evaluation of macular changes before and after successful retinal detachment surgery using Stratus optical coherence tomography. *Am J Ophthalmol*. 2006;142:176–179.
43. Smith AJ, Telander DG, Zawadzki RJ, et al. High-resolution Fourier-domain optical coherence tomography and microperimetric findings after macula-off retinal detachment repair. *Ophthalmology*. 2008;115:1923–1929.
44. Wakabayashi T, Oshima Y, Fujimoto H, et al. Foveal microstructure and visual acuity after retinal detachment repair: imaging analysis by Fourier-domain optical coherence tomography. *Ophthalmology*. 2009;116:519–528.
45. Satoh Y. [Retinal circulation in rhegmatogenous retinal detachment demonstrated by videofluorescence angiography and image analysis. I. The condition of retinal circulation before retinal detachment surgery]. *Nippon Ganka Gakkai Zasshi*. 1989;93:1002–1008.
46. Cardillo Piccolino F. Vascular changes in rhegmatogenous retinal detachment. *Ophthalmologica*. 1983;186:17–24.
47. Woo JM, Yoon YS, Woo JE, et al. Foveal avascular zone area changes analyzed using OCT angiography after successful rhegmatogenous retinal detachment repair. *Curr Eye Res*. 2018;43:674–678.
48. Agarwal A, Aggarwal K, Akella M, et al. Fractal dimension and optical coherence tomography angiography features of the central macula after repair of rhegmatogenous retinal detachments. *Retina*. 2019;39:2167–2177.
49. Bonfiglio V, Ortisi E, Scollo D, et al. Vascular changes after vitrectomy for rhegmatogenous retinal detachment: optical coherence tomography angiography study [published online ahead of print November 26, 2019]. *Acta Ophthalmol*. 2019. doi:10.1111/aos.14315.
50. Tsen CL, Sheu SJ, Chen SC, et al. Imaging analysis with optical coherence tomography angiography after primary repair of macula-off rhegmatogenous retinal detachment. *Graefes Arch Clin Exp Ophthalmol*. 2019;257:1847–1855.
51. Roldán-Pallarés M, Musa AS, Hernández-Montero J, et al. Retinal detachment and proliferative vitreoretinopathy: central retinal artery blood velocities, intraocular pressure, and endothelin 1. *Retina*. 2013;33:1528–1539.

52. Gaucher D, Chiappore JA, Pâques M, et al. Microglial changes occur without neural cell death in diabetic retinopathy. *Vision Res.* 2007;47:612–623.
53. Yui N, Kunikata H, Aizawa N, et al. Optical coherence tomography angiography assessment of the macular capillary plexus after surgery for macula-off rhegmatogenous retinal detachment. *Graefes Arch Clin Exp Ophthalmol.* 2019;257:245–248.
54. Sato T, Kanai M, Busch C, et al. Foveal avascular zone area after macula-off rhegmatogenous retinal detachment repair: an optical coherence tomography angiography study. *Graefes Arch Clin Exp Ophthalmol.* 2017;255:2071–2072.
55. Hong EH, Cho H, Kim DR, et al. Changes in retinal vessel and retinal layer thickness after vitrectomy in retinal detachment via swept-source OCT angiography. *Invest Ophthalmol Vis Sci.* 2020;61:35.
56. Lee JY, Kim JY, Lee SY, et al. Foveal microvascular structures in eyes with silicone oil tamponade for rhegmatogenous retinal detachment: a swept-source optical coherence tomography angiography study. *Sci Rep.* 2020;10:2555.
57. Veckeneer M, Augustinus C, Feron E, et al. OCT angiography documented reperfusion of translocated autologous full-thickness RPE-choroid graft for complicated neovascular age-related macular degeneration. *Eye.* 2017;31:1274–1283.
58. Rizzo S, Caporossi T, Tartaro R, et al. Human amniotic membrane plug to restore age-related macular degeneration photoreceptor damage. *Ophthalmol Retin.* 2020;4:996–1007.
59. Michalewska Z, Nawrocka Z, Nawrocki J. Swept-source OCT and swept-source OCT angiography before and after vitrectomy with stuffing of the optic pit. *Ophthalmol Retin.* 2020;4:927–937.