


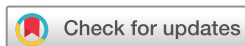# openheart Intravascular imaging for percutaneous coronary intervention on bifurcation and unprotected left main lesions: a systematic review and meta-analysis

Andrea Zito,<sup>1</sup> Francesco Burzotta <sup>1,2</sup>, Cristina Aurigemma,<sup>3</sup> Enrico Romagnoli,<sup>4</sup> Lazzaro Paraggio,<sup>3</sup> Francesco Fracassi,<sup>3,5</sup> Mattia Lunardi,<sup>3</sup> Luigi Cappannoli,<sup>4</sup> Francesco Bianchini,<sup>6</sup> Carlo Trani<sup>7</sup>

► Additional supplemental material is published online only. To view, please visit the journal online (<https://doi.org/10.1136/openhrt-2024-003026>).

**To cite:** Zito A, Burzotta F, Aurigemma C, *et al*. Intravascular imaging for percutaneous coronary intervention on bifurcation and unprotected left main lesions: a systematic review and meta-analysis. *Open Heart* 2025;**12**:e003026. doi:10.1136/openhrt-2024-003026

Received 19 October 2024  
Accepted 7 May 2025



© Author(s) (or their employer(s)) 2025. Re-use permitted under CC BY-NC. No commercial re-use. See rights and permissions. Published by BMJ Group.

For numbered affiliations see end of article.

**Correspondence to**  
Dr Francesco Burzotta;  
[francescoburzotta@gmail.com](mailto:francescoburzotta@gmail.com)

## ABSTRACT

**Background** The efficacy of intravascular imaging (IVI) guidance for percutaneous coronary intervention (PCI) represents a contemporary hot topic. PCI in patients with bifurcation coronary lesions and unprotected left main lesions offers specific challenges that, theoretically, may particularly benefit from IVI.

**Objective** To compare the clinical outcomes between IVI and angiography guidance for PCI in bifurcation and unprotected left main lesions.

**Methods** Randomised clinical trials (RCTs) comparing IVI (with either intravascular ultrasound or optical coherence tomography) with angiography to guide PCI in patients with bifurcation and unprotected left main lesions were searched in PubMed and Cochrane Central Register of Controlled Trials. Two investigators independently extracted study data. Risk ratios (RRs) were calculated using the random-effects model with inverse variance weighting and the 95% CIs with the modified Knapp-Hartung-Sidik-Jonkman method. The primary outcome was target vessel failure (TVF).

**Results** A total of seven RCTs were included, collecting data on 2494 patients in the analysis for bifurcation lesions and 1107 patients in the analysis for unprotected left main lesions. The mean follow-up duration ranged from 12 to 36 months. Compared with angiography guidance, IVI guidance significantly reduced TVF both in bifurcation lesions (RR 0.70, 95% CI 0.53 to 0.92) and unprotected left main lesions (RR 0.55, 95% CI 0.36 to 0.84). The number needed to treat to prevent one TVF with IVI was 27 in bifurcation lesions PCI and 11 in unprotected left main PCI.

**Conclusion** In patients undergoing PCI on bifurcation and unprotected left main lesions, IVI guidance significantly reduces the risk of TVF compared with angiography guidance.

**PROSPERO registration number** CRD42024580321.

## INTRODUCTION

Percutaneous coronary intervention (PCI) has historically been guided by angiography, which lacks information about lesion characterisation and stent expansion/apposition.

### WHAT IS ALREADY KNOWN ON THIS TOPIC

⇒ The benefit of intravascular imaging (IVI) guidance for percutaneous coronary intervention (PCI) in bifurcation and unprotected left main lesions remains unclear.

### WHAT THIS STUDY ADDS

⇒ Compared with angiography guidance, IVI guidance for PCI in bifurcation and unprotected left main lesions provides a large reduction in the risk of target vessel failure.

### HOW THIS STUDY MIGHT AFFECT RESEARCH, PRACTICE OR POLICY

⇒ For PCI in bifurcation and unprotected left main lesions, IVI guidance should be adopted as the standard of care.

Intravascular imaging (IVI) devices such as intravascular ultrasonography (IVUS) and optical coherence tomography (OCT) offer a detailed assessment of coronary anatomy and stent results, which could be incorporated into the PCI planning and optimisation process.<sup>1</sup> A recent randomised controlled trial (RCT) demonstrated comparable efficacy of OCT and IVUS guidance, thus supporting their comparable clinical efficacy.<sup>2</sup> To date, IVI guidance has been implemented in clinical practice in many centres, proving its technical feasibility.<sup>3</sup> However, the true clinical impact of IVI is still uncertain since large-scale RCTs provided conflicting results on the benefit of IVI-guided PCI compared with angiography-guided PCI. Of note, the heterogeneous benefit of IVI guidance might depend on the specific technical challenges offered by PCI in different patient/lesion subsets. In this regard, PCIs on bifurcation or unprotected left main lesions present specific anatomical features, offer multiple

procedural technical options and are associated with a recognised risk of procedural complications and adverse clinical outcomes.<sup>4,5</sup> On this background, we performed a meta-analysis of RCTs comparing IVI and angiography guidance for PCI in bifurcation and unprotected left main lesions.

## METHODS

This systematic review and meta-analysis was carried out in accordance with guidelines from the Cochrane Collaboration and Preferred Reporting Items for Systematic reviews and Meta-Analyses (online supplemental table 1).<sup>6</sup> The protocol was registered in PROSPERO (CRD42024580321).

### Search strategy

We searched PubMed and CENTRAL for keywords related to PCI, IVI, IVUS and OCT from inception to 3 September 2024. The full search strategy is available in online supplemental table 2.

### Study Selection

We included RCTs comparing IVI and angiography guidance for PCI in patients with bifurcation and unprotected left main lesions. Non-randomised studies and studies that did not report clinical outcomes were excluded. We applied no restrictions on study language, follow-up duration or publication date. Two investigators (A.Z. and L.C.) independently screened all records retrieved and examined titles and abstracts for eligibility. They assessed potentially suitable articles for inclusion by inspecting full text and supplementary material. Discrepancies were resolved by collegial discussion.

### Data extraction and quality assessment

Two investigators (A.Z. and L.C.) extracted data on study design and features, patients' baseline characteristics and outcomes. When different follow-up durations were reported for the same trial, the longest was included in the analysis.

The same two investigators independently assessed risk of bias using the Cochrane Risk of Bias Tool, composed of the following 5 domains: randomisation process, deviations from intended interventions, missing outcome data, measurement of the outcome and selection of the reported result. The outcome was trial-defined target vessel failure (TVF), which commonly included the combination of cardiac death, non-fatal myocardial infarction and target vessel revascularisation as defined by the individual study protocols.

### Statistical analysis

Risk ratios (RRs) were calculated using the random-effects model with inverse variance weighting and the 95% CIs with the modified Knapp-Hartung-Sidik-Jonkman method with ad hoc variance correction suggested by the Institute for Quality and Efficiency in Health Care.<sup>7</sup> Heterogeneity between studies was assessed by the Cochran Q test and

consistency by Higgins-Thompson I<sup>2</sup>. The potential presence of publication bias was assessed by visual inspection of funnel plots and using Egger's test. A sensitivity analysis for the bifurcation subgroup including only trials assessing true (ie, bifurcation with lesion in both main and side branches) and double-stenting bifurcations was performed. Statistical analysis was performed using R (R Foundation).

### Role of the funding source

None.

## RESULTS

After screening the 2694 citations retrieved (online supplemental table 3), we identified seven trials for inclusion (ILUMIEN IV,<sup>8</sup> Liu *et al.*,<sup>9</sup> OCCUPI,<sup>10</sup> OCTOBER,<sup>11</sup> RENOVATE-COMPLEX-PCI,<sup>12</sup> Tan *et al.*,<sup>13</sup> ULTIMATE).<sup>14</sup> A total of 2494 patients from five trials were included in the analysis for bifurcation lesions, and a total of 1107 patients from five trials were included in the analysis for unprotected left main lesions. The mean patient age ranged from 63 to 76 years and the rate of diabetic patients from 17% to 42%. The mean follow-up duration ranged from 12 to 36 months. The IVI device used was IVUS in three trials, OCT in three trials, and IVUS or OCT at the operators' discretion in one trial. Bifurcation lesion definition was heterogeneous among studies, but the complex subset ('true bifurcations' or bifurcations deserving 2-stent techniques) was mainly targeted. TVF definition was similar across studies and mainly included a composite of cardiac death, myocardial infarction and target vessel/lesion revascularisation (table 1 and online supplemental table 4).

The risk-of-bias assessment is reported in online supplemental figure 1 showing an overall high quality of the studies collected (five out of seven studies being at low risk of bias, 1 study with some concerns, and 1 study only at high risk of bias).

The pooled results are shown in figure 1 and demonstrated that, compared with angiography-guided PCI, IVI-guided PCI significantly reduced the risk of TVF in bifurcation lesions (RR 0.70, 95% CI 0.53 to 0.92) and unprotected left main lesions (RR 0.55, 95% CI 0.36 to 0.84). This corresponds to a number needed to treat of 11 (95% CI 8 to 32) patients to prevent one TVF in unprotected left main PCI and of 27 (95% CI 17 to 104) patients in bifurcation lesions PCI. Funnel plots and Egger's tests suggested no evidence of publication bias or small study effect (online supplemental figure 2).

The sensitivity analysis including only trials assessing true and double-stenting bifurcation yielded similar results to the main analysis (online supplemental figure 3).

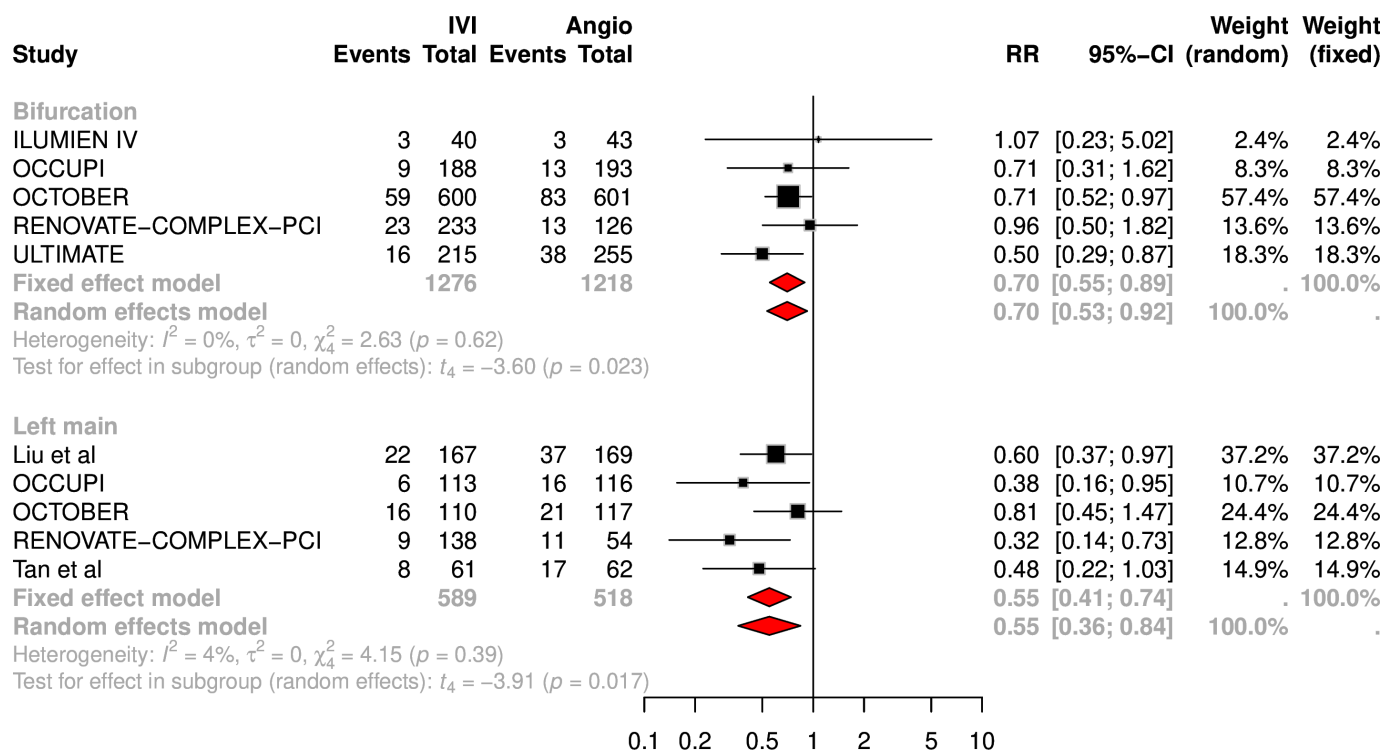
## DISCUSSION

Coronary lesions located in bifurcated or unprotected left main arteries represent two subsets of complex lesions for which improved PCI efficacy is being sought. Bifurcation

**Table 1** Key features of included RCTs

Trial (ref)	Year	Sample size	Intravascular imaging	Clinical presentation (%)		TVF definition	Follow-up (months)
				ACS	CCS		
ILUMIEN IV <sup>8</sup>	2023	2487 (83 double-stent bifurcation)	OCT pre- and post-PCI	51.8	48.2	Composite of cardiac death, MI, and ischaemia-driven TLR	24
Liu <i>et al</i> <sup>9</sup>	2019	336 (ULMCA)	IVUS pre- and post-PCI	86.6	13.4	Composite of cardiac death, MI and TVR	12
OCCUPI <sup>10</sup>	2024	1604 (381 bifurcation, 229 ULMCA)	OCT pre- and post-PCI	49.3	50.7	Composite of cardiac death, MI, stent thrombosis or ischaemia-driven TVR	12
OCTOBER <sup>11</sup>	2023	1201 (true bifurcation)	OCT pre- and post-PCI	45.8	54.2	Composite of death from a cardiac cause, target-lesion MI or ischaemia-driven TLR	24
RENOVATE-COMPLEX-PCI <sup>12</sup>	2023	1639 (359 true bifurcation, 192 ULMCA)	IVUS/OCT post-PCI	50.8	49.2	Composite of cardiac death, target-vessel MI and clinically driven TVR	25
Tan <i>et al</i> <sup>13</sup>	2015	123 (ULMCA)	IVUS pre- and post-PCI	68	32	Composite of death from any cause, non-fatal MI or TLR	24
ULTIMATE <sup>14</sup>	2021	1448 (470 bifurcation)	IVUS pre- and post-PCI	79	21	Composite of cardiac death, target-vessel MI and clinically driven TVR	36

ACS, acute coronary syndrome; CCS, chronic coronary syndrome; IVUS, intravascular ultrasound; MI, myocardial infarction; OCT, optical coherence tomography; PCI, percutaneous coronary intervention; RCT, randomised controlled trial; TLR, target lesion revascularisation; TVR, target vessel revascularisation; ULMCA, unprotected left main coronary artery.



**Figure 1** Forest plot for the outcome of target vessel failure. Angio, angiography; IVI, intravascular imaging; RR, risk ratio; TVF, target vessel failure.

lesions are characterised by a wide variation in anatomical presentations and atherosclerotic plaque distribution, which often translate into higher risk of achieving suboptimal PCI results.<sup>15</sup> Unprotected left main lesions, due to the peculiar anatomy of left main stem (short vessel with major bifurcation branches often involved by atherosclerosis) and the large amount of myocardium supplied, represent a specific environment in which PCI techniques must be tailored to provide the greatest likelihood of successful treatment.<sup>16</sup> In particular, IVI guidance during bifurcation and unprotected left main PCI may help to select the most appropriate lesion preparation techniques and stent implantation strategy, thus limiting stent complications that are often angiographically invisible. Accordingly, these results support current experts' recommendations in the field, prioritise the adoption of IVI guidance for PCI in bifurcation and unprotected left main lesions, and call for appropriate recommendations in international clinical guidance.

The main limitation of this study is the lack of individual-patient data, which prevented us from assessing the potential differential impact of IVI guidance on various PCI techniques and lesion characteristics. Furthermore, individual outcomes were not available and our analysis relied on the composite outcome of TVF, which, however, was similarly defined across trials.

#### Author affiliations

<sup>1</sup>Department of Cardiovascular and Thoracic Sciences, Catholic University of the Sacred Heart, Rome, Italy

<sup>2</sup>Fondazione Policlinico Universitario Agostino Gemelli IRCCS, Roma, Italy

<sup>3</sup>Department of Cardiovascular Sciences, Fondazione Policlinico Universitario A Gemelli IRCCS, Rome, Italy

<sup>4</sup>Department of Cardiovascular Sciences, Fondazione Policlinico Universitario Agostino Gemelli IRCCS, Roma, Italy

<sup>5</sup>Università Cattolica Sacro Cuore, Rome, Italy

<sup>6</sup>Fondazione Policlinico Universitario A. Gemelli IRCCS, Rome, Italy

<sup>7</sup>Department of Cardiovascular Medicine, Policlinico Universitario Agostino Gemelli, Rome, Italy

X Francesco Burzotta @BURZOTTA\_F

**Acknowledgements** The authors acknowledge the Italian Ministry of Health 'Ricerca Corrente 2023' for the support.

**Contributors** AZ: conception and design, data analysis, drafting of the article. FB: conception and design, data analysis, drafting of the article, corresponding author (guarantor). CA: critical revision of the article. ER: critical revision of the article. LP: critical revision of the article. FF: critical revision of the article. ML: critical revision of the article. LG: critical revision of the article. FB: data analysis, critical revision of the article. CT: critical revision of the manuscript.

**Funding** The authors have not declared a specific grant for this research from any funding agency in the public, commercial or not-for-profit sectors.

**Competing interests** CT has been involved in advisory board meetings or received speaker's fees from Abbott, Abiomed and Biotronic. FB has been involved in advisory board meetings or received speaker's fees from Medtronic, Abbott, Terumo, Daiichi-Sankyo and Abiomed. All other authors declare no competing interests.

**Patient consent for publication** Not applicable.

**Ethics approval** Not applicable.

**Provenance and peer review** Not commissioned; externally peer-reviewed.

**Data availability statement** All data relevant to the study are included in the article or uploaded as supplementary information. All analysed data are reported in the manuscript.

**Supplemental material** This content has been supplied by the author(s). It has not been vetted by BMJ Publishing Group Limited (BMJ) and may not have been peer-reviewed. Any opinions or recommendations discussed are solely those of the author(s) and are not endorsed by BMJ. BMJ disclaims all liability and responsibility arising from any reliance placed on the content. Where the content includes any translated material, BMJ does not warrant the accuracy and reliability of the translations (including but not limited to local regulations, clinical guidelines, terminology, drug names and drug dosages), and is not responsible for any error and/or omissions arising from translation and adaptation or otherwise.

**Open access** This is an open access article distributed in accordance with the Creative Commons Attribution Non Commercial (CC BY-NC 4.0) license, which permits others to distribute, remix, adapt, build upon this work non-commercially, and license their derivative works on different terms, provided the original work is properly cited, appropriate credit is given, any changes made indicated, and the use is non-commercial. See: <http://creativecommons.org/licenses/by-nc/4.0/>.

#### ORCID iD

Francesco Burzotta <http://orcid.org/0000-0002-6569-9401>

#### REFERENCES

- Truesdell AG, Alasnag MA, Kaul P, *et al*. Intravascular Imaging During Percutaneous Coronary Intervention: JACC State-of-the-Art Review. *J Am Coll Cardiol* 2023;81:590–605.
- Kang D-Y, Ahn J-M, Yun S-C, *et al*. Optical Coherence Tomography-Guided or Intravascular Ultrasound-Guided Percutaneous Coronary Intervention: The OCTIVUS Randomized Clinical Trial. *Circulation* 2023;148:1195–206.
- Burzotta F, Zito A, Aurigemma C, *et al*. Fractional flow reserve or optical coherence tomography for angiographically intermediate coronary stenoses: 5-year outcomes in the FORZA trial. *Eur Heart J* 2024;45:2785–8.
- Werner N, Nickenig G, Sinning J-M. Complex PCI procedures: challenges for the interventional cardiologist. *Clin Res Cardiol* 2018;107:64–73.
- Zito A, Burzotta F, Aurigemma C, *et al*. Fractional flow reserve or OCT to guide management of complex and noncomplex angiographically intermediate coronary stenosis. *Rev Esp Cardiol (Engl Ed)* 2025.
- Page MJ, McKenzie JE, Bossuyt PM, *et al*. The PRISMA 2020 statement: an updated guideline for reporting systematic reviews. *BMJ* 2021;372:n71.
- Care H. General methods - version 7.0. 2023.
- Ali ZA, Landmesser U, Maehara A, *et al*. Optical Coherence Tomography-Guided versus Angiography-Guided PCI. *N Engl J Med* 2023;389:1466–76.
- Liu XM, Yang ZM, Liu XK, *et al*. Intravascular ultrasound-guided drug-eluting stent implantation for patients with unprotected left main coronary artery lesions: A single-center randomized trial. *Anatol J Cardiol* 2019;21:83–90.
- Hong S-J, Lee S-J, Lee S-H, *et al*. Optical coherence tomography-guided versus angiography-guided percutaneous coronary intervention for patients with complex lesions (OCCUPI): an investigator-initiated, multicentre, randomised, open-label, superiority trial in South Korea. *Lancet* 2024;404:1029–39.
- Holm NR, Andreasen LN, Neghabat O, *et al*. OCT or Angiography Guidance for PCI in Complex Bifurcation Lesions. *N Engl J Med* 2023;389:1477–87.
- Lee JM, Choi KH, Song YB, *et al*. Intravascular Imaging-Guided or Angiography-Guided Complex PCI. *N Engl J Med* 2023;388:1668–79.
- Tan Q, Wang Q, Liu D, *et al*. Intravascular ultrasound-guided unprotected left main coronary artery stenting in the elderly. *Saudi Med J* 2015;36:549–53.
- Gao X-F, Ge Z, Kong X-Q, *et al*. 3-Year Outcomes of the ULTIMATE Trial Comparing Intravascular Ultrasound Versus Angiography-Guided Drug-Eluting Stent Implantation. *JACC Cardiovasc Interv* 2021;14:247–57.
- Lunardi M, Louvard Y, Lefèvre T, *et al*. Definitions and Standardized Endpoints for Treatment of Coronary Bifurcations. *J Am Coll Cardiol* 2022;80:63–88.
- Burzotta F, Lassen JF, Banning AP, *et al*. Percutaneous coronary intervention in left main coronary artery disease: the 13th consensus document from the European Bifurcation Club. *EuroIntervention* 2018;14:112–20.