

Through-and-through femorofemoral wire retrograde technique for the E-nside precannulated inner branch thoracoabdominal stent graft

Giovanni Tinelli, MD, PhD, Fabrizio Minelli, MD, Federica Donato, MD, Simona Sica, MD, Francesca De Nigris, MD, and Yamume Tshomba, MD, Rome, Italy

ABSTRACT

The E-nside multibranched stent graft (Jotec GmbH, Hechingen, Germany) is the first and only off-the-shelf thoracoabdominal prosthesis with precannulated inner branches. Usually, after the device deployment, target vessel stenting will be facilitated by antegrade inner branch cannulation to retrieve the precannulated guide. In the literature, the use of antegrade access has been associated with the potential risk of cerebral and systemic embolization. Therefore, other retrograde techniques have been described. We have reported a new retrograde approach using a precannulated through-and-through femorofemoral wire technique for target vessel catheterization. (*J Vasc Surg Cases Innov Tech* 2022;8:335-7.)

Keywords: E-nside; Multibranched stent graft; Personalized medicine; Target vessel; Through-and-through technique

Endovascular technology, in particular, the fenestrated and branched endografts used in endovascular aneurysm repair, has provided a less invasive treatment option for complex aortic aneurysms.¹ The E-nside multibranch stent graft system (Jotec GmbH, Hechingen, Germany) is the first and only off-the-shelf thoracoabdominal stent graft with four precannulated inner branches. Device implantation requires a cranial approach using a subclavian, axillary, or brachial artery to catheterize the branch and target vessels, with the disadvantage of cranial access and, in particular, the potential for cerebral and systemic embolization from the aortic arch.

The standard technique of stent graft implantation and vessel cannulation has been previously described.² We have reported a new approach using a double femoral access approach and a through-and-through femorofemoral retrograde wire technique to perform target vessel cannulation. The patient provided written informed consent for the report of his case details and imaging studies.

THROUGH-AND-THROUGH FEMOROFEMORAL WIRE TECHNIQUE

The procedure was performed with the patient under general anesthesia and required bilateral percutaneous femoral access. We introduced the E-nside endograft (Jotec GmbH) over a Lunderquist extra-stiff guidewire (Cook Medical, Inc, Bloomington, IN) from the right femoral artery. From the left femoral access, a 6F sheath was placed first to perform angiography using a pigtail catheter.

The E-nside (Jotec GmbH) was placed with the inner branches for the target vessels just above each of them. The graft was fully deployed after tip capture release. Next, the cannulation procedure for the single inner branches and stenting of the target vessels was begun. From the left femoral axis, a 12F DrySeal Flex Sheath (W. L. Gore & Associates, Flagstaff, AZ) was introduced into the E-nside graft. Inside the 12F DrySeal Flex Sheath, we inserted the Indy OTW vascular retriever (Cook Medical, Inc) which had been led proximally above the opened prosthesis. A 0.018-in., 400-cm, nonhydrophilic wire was then advanced through the precannulation tube for the target vessel and snared by the Indy retriever just above the first stent, outside the endograft, to the right femoral artery. With the through-and-through wire established, from the left femoral access and inside the 12Fr DrySeal Introducer (W. L. Gore & Associates), an 8.5F Tour Guide Steerable Sheath (Medtronic, Inc, Santa Rosa, CA) was advanced into the target vessel inner branch after curving the shaft. The sheath was stabilized under continuous, controlled tension exerted on the 0.018-in. wire. A shaft and a 0.035-in. J-curved Radifocus wire (Terumo, Somerset, NJ) was then used to cannulate the target vessel and replaced with a Rosen wire (Cook Medical, Inc). The through-and-through wire was then

From the Unit of Vascular Surgery, Fondazione Policlinico Universitario A. Gemelli IRCCS - Università Cattolica del Sacro Cuore.

Author conflict of interest: none.

Correspondence: Giovanni Tinelli, MD, PhD, Unit of Vascular Surgery, Fondazione Policlinico Universitario Agostino Gemelli IRCCS, Roma, Università Cattolica del Sacro Cuore, Largo Agostino Gemelli, 8, Rome 00168, Italy (e-mail: giovanni.tinelli@policlinicogemelli.it).

The editors and reviewers of this article have no relevant financial relationships to disclose per the Journal policy that requires reviewers to decline review of any manuscript for which they may have a conflict of interest.

2468-4287

© 2022 The Authors. Published by Elsevier Inc. on behalf of Society for Vascular Surgery. This is an open access article under the CC BY-NC-ND license (<http://creativecommons.org/licenses/by-nc-nd/4.0/>).

<https://doi.org/10.1016/j.jvscit.2022.04.010>

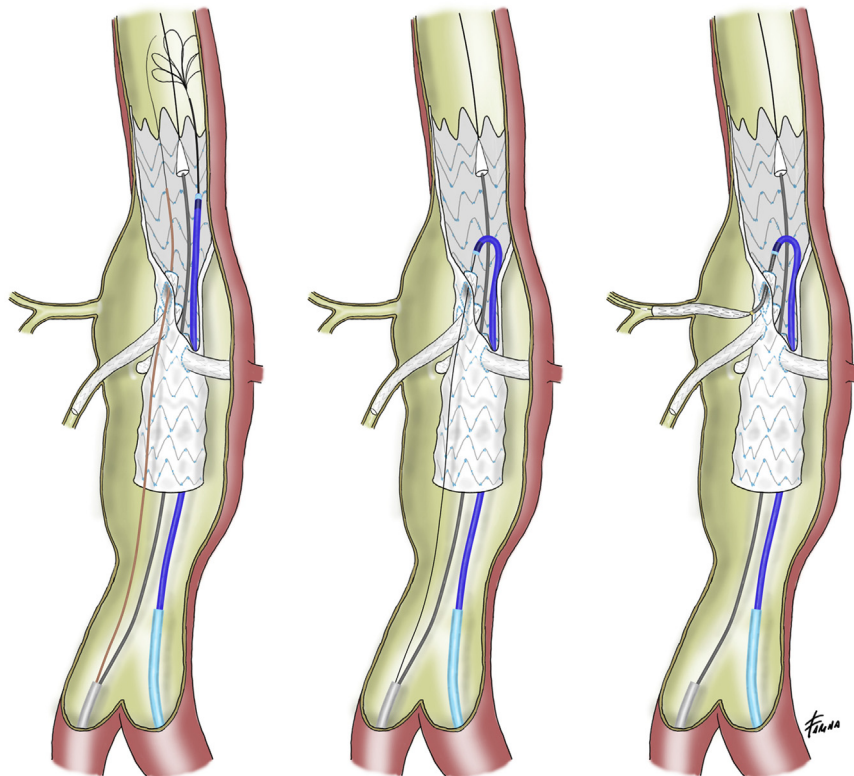


Fig. Through-and-through femorofemoral wire retrograde technique for target vessel cannulation.

removed for implantation of the balloon-expandable stent graft in the target vessel. The step-by-step procedure is shown in the [Fig](#) and [Supplementary Video](#). The same implantation procedure was used for the other renovisceral vessels.

DISCUSSION

Off-the-shelf multibranched endografts have been developed to circumvent the limitations of the customization process required for fenestrated and branched stent grafts.³ However, some anatomic factors can reduce the overall feasibility of the use of these endografts and have been associated with a high rate of complications. In particular, the use of upper access or the presence of shaggy aortas and calcifications has been associated with an increased risk of embolization complications.⁴ A possible solution to avoid the use of an upper extremity access in high-risk cases is the through-and-through femorofemoral wire technique, which was described in the present case. This technique excludes the need for axillary or brachial artery access and has often been used during complex aneurysms endovascular repair with branched endografts for the implantation of balloon-expandable stent grafts in the target vessels.⁵⁻⁷ An important advantage of this approach is the absence

of an aortic arch crossing with endovascular devices, reducing the risk of aortic atheroma mobilization and potential cerebral and systemic embolization.⁸ Femoral-only access excludes the potential complications related to cranial surgical access and reduces the duration of the procedure. Additionally, a key point of our approach is the use of the steerable sheath (Tour Guide Steerable Sheath; Medtronic, Inc) for target vessel cannulation inside the 12F DrySeal Sheath (W. L. Gore & Associates), which allows for better stability of the whole system. The use of a low-profile device, such as the Tour Guide Steerable Sheath (Medtronic, Inc), has allowed for a reduction in the risk of intestinal and spinal ischemia after temporary occlusion of the hypogastric arteries. To reduce these risks, it is important to reduce the profile of the introducer positioned in the contralateral iliac axis. During cannulation of the inner branches and the relative target vessels, the whole shaft of the E-nside graft will remain inside the ipsilateral iliac axis and could obstruct the ostium of the hypogastric artery. This will ensure visceral perfusion via the contralateral hypogastric artery and reduce the risk of spinal cord hypoperfusion during the procedure. The potential anatomic limitations to this technique include high tortuosity in the iliac arteries or infrarenal aorta and a hostile orientation of

the visceral vessels (eg, horizontal or a downward or upward renal orientation).⁹

CONCLUSIONS

Jotec E-nside (Jotec GmbH) thoracoabdominal endograft implantation with the new through-and-through femorofemoral wire deployment technique has important advantages, especially for cases with thrombotic formation in the aortic arch. In addition, the steerable sheath could be an effective adjunctive tool and can be used primarily as a planned technique or in the case of failure of standard cannulation in challenging anatomies.

REFERENCES

1. Anderson JL, Adam DJ, Berce M, Hartley DE. Repair of thoracoabdominal aortic aneurysms with fenestrated and branched endovascular stent grafts. *J Vasc Surg* 2005;42:600-7.
2. Zimmermann A, Menges AL, Rancic Z, Meuli L, Dueppers P, Reutersberg B. E-nside off-the-shelf inner branch stent graft: technical aspects of planning and implantation. *J Endovasc Ther* 2022;29:167-74.
3. Bilman V, Cambiaghi T, Grandi A, Carta N, Melissano G, Chiesa R, et al. Anatomical feasibility of a new off-the-shelf inner branch stent graft (E-nside) for endovascular treatment of thoraco-abdominal aneurysms. *Eur J Cardiothorac Surg* 2020;58:1296-303.
4. Maeda K, Ohki T, Kanaoka Y, Shukuzawa K, Baba T, Momose M. A novel shaggy aorta scoring system to predict embolic complications following thoracic endovascular aneurysm repair. *Eur J Vasc Endovasc Surg* 2020;60:57-66.
5. Tsilimparis N, Fiorucci B, Debus ES, Rohlfes F, Kölbl T. Technical aspects of implanting the t-Branch off-the-shelf multibranched stent-graft for thoracoabdominal aneurysms. *J Endovasc Ther* 2017;24:397-404.
6. Bertoglio L, Mascia D, Cambiaghi T, Kahlberg A, Melissano G, Chiesa R. Percutaneous axillary artery access for fenestrated and branched thoracoabdominal endovascular repair. *J Vasc Surg* 2018;68:12-23.
7. Watkins AC, Avramenko A, Soler R, Fabre D, Haulon S. A novel all-retrograde approach for t-Branch implantation in ruptured thoracoabdominal aneurysm. *J Vasc Surg Cases Innov Tech* 2018;4:301-4.
8. Plotkin A, Ding L, Han SM, Oderich GS, Starnes BW, Lee JT, et al. Association of upper extremity and neck access with stroke in endovascular aortic repair. *J Vasc Surg* 2020;72:1602-9.
9. Gallitto E, Faggioli G, Pini R, Mascoli C, Ancetti S, Abualhin M, et al. Renal artery orientation influences the renal outcome in endovascular thoraco-abdominal aortic aneurysm repair. *Eur J Vasc Endovasc Surg* 2018;56:382-90.

Submitted Jan 23, 2022; accepted Apr 11, 2022.