

Reticulation is a Risk Factor of Progressive Subpleural non-Fibrotic Interstitial Lung

Abnormalities

Yuchen Zhang^{1,2,3*}, Huajing Wan Ph.D.^{1,2,3*}, Luca Richeldi M.D, Ph.D.^{4*}, Min Zhu^{1,2,3*}, Yan Huang^{5*}, Xiaofeng Xiong^{1,2,3}, Junzhe Liao^{1,2,3}, Wenjun Zhu^{1,2,3,6}, Lingli Mao^{1,2,3}, Linrui Xu^{1,2,3}, Dongfan Ye^{1,2,3}, Ling Chen^{1,2,3}, Jia Liu^{1,2,3}, Linxi Fu^{1,2,3}, Liangyuan Li^{1,2,3}, Lan Lan^{1,2,3}, Ping Li^{1,2,3}, Lixia Wang^{1,2,3}, Xiaoju Tang^{1,2,3}, Fengming Luo M.D, Ph.D.^{1,2,3†}

¹ Department of Pulmonary and Critical Care Medicine, West China Hospital, Sichuan University, Chengdu, Sichuan, P.R. China;

² Laboratory of Pulmonary Immunology and Inflammation, Frontiers Science Center for Disease-related Molecular Network, West China Hospital, Sichuan University, Chengdu, Sichuan, P.R. China;

³ Clinical Research Center for Respiratory Disease, West China Hospital, Sichuan University, Chengdu, Sichuan, P.R. China;

⁴ Division of Pulmonary Medicine, Fondazione Policlinico Universitario A. Gemelli IRCCS, Università Cattolica del Sacro Cuore, Rome, Italy;

⁵ Department of Health Management Center, West China Hospital, Sichuan University, Chengdu, Sichuan, P.R. China;

⁶ Department of Respiratory Diseases, The Second Affiliated Hospital of Nanchang University, Nanchang, Jiangxi, P.R. China.

*Equally contributed.

†Corresponding author:

Fengming Luo M.D, Ph.D.

Department of Pulmonary and Critical Care Medicine

West China Hospital, Sichuan University

Chengdu 610041, Sichuan, China

Tel: +86-28-61526696; Fax: +86-28-61526696; e-mail: fengmingluo@outlook.com

Author contribution:

Conception and design: FL, LR, HW, YZ, MZ. Acquisition, analysis, and interpretation of data: YH, XX, WZ, LM, LX, DY, LC, JL, JL, LF, LL, LL, PL, LW. Critical revision of the manuscript for important intellectual content: LR, FL, HW, MZ, YZ. Statistical analysis: YZ, MZ. Obtain funding: FL, HW, MZ, XT.

Sources of support:

This work was supported by National Natural Science Foundation of China grant (NSFC No.32070764; No.81800087); 1.3.5 project for disciplines of excellence, West China Hospital, Sichuan University (ZYJC18021, ZYJC21023); Sichuan Science and Technology Program (No. 2021YFQ0030; No. 2020YFH0073).

Running title: Progressive subpleural non-fibrotic ILAs.

Total word count: 2,773

Title: 100 characters (including spaces).

Descriptor number: 9.23 interstitial lung disease.

Key words: health check-up population; interstitial lung abnormalities; reticulation; radiological progression.

Online data supplement: This article has an online data supplement, which is accessible from this issue's table of contents at www.atsjournals.org.

At A Glance

What is the current scientific knowledge on this subject?

The only available classification document on interstitial lung abnormalities (ILAs) based on chest computed tomography (CT) patterns, a Position Paper from the Fleischner Society, include reticulation among the features of subpleural non-fibrotic ILAs, as such implying a low risk of progression. However, it is currently unknown if and how reticulation can contribute to the risk of subpleural non-fibrotic ILAs progression.

What does this study add to the field?

In a large Chinese health checkup population with a broad age range undergoing periodic chest CT, the prevalence of ILAs was 2.1% and subpleural non-fibrotic ILAs did progress over a period of 4 years in nearly half of individuals, not only in older patients but as an age continuum. These data lend support to the concept that subpleural non-fibrotic ILAs with extensive reticulation have a risk of radiological progression similar to subpleural fibrotic ILAs and support the role of extensive reticulation as a key component of ILAs prognostication.

ABSTRACT

Rationale: Interstitial lung abnormalities (ILAs) are being increasingly identified in clinical practice. In particular for subpleural non-fibrotic ILAs, the risk of progression over time and the risk factors for progressive behavior are still largely unknown.

Objectives: To determine the age band prevalence of ILAs and the risk of radiological progression of subpleural non-fibrotic ILAs over time in a large health check-up population, and to identify how reticulation contributes to the risk of radiological progression.

Methods: Based on ILAs definition by the Fleischner Society, low-dose chest CT images from community-dwelling population undergone health check-up were evaluated for ILAs. Multivariable logistic regression was used to assess the risk of radiological progression.

Measurements and Main Results: Among 155,539 individuals, 3,300 (2.1%) were confirmed to have ILAs: the vast majority (81.7%) were defined as subpleural non-fibrotic ILAs. The prevalence of ILAs increased linearly with age (P for trend<0.0001). Of 454 individuals with subpleural non-fibrotic ILAs, 198 (43.6%) had radiological progression over 4 years. The presence of reticulation on initial imaging was an independent predictor of radiological progression (OR 1.9; 95%CI 1.2-3.0, P=0.0040). No difference in radiological progression was identified between subpleural non-fibrotic ILAs with extensive reticulation and subpleural fibrotic ILAs (73.0% vs. 68.8%, P=0.7626).

Conclusions: The prevalence of ILAs increases linearly with age. Nearly half of subpleural non-fibrotic ILAs progress radiologically over 4 years. The presence of reticulation is a risk factor for radiological progression. Subpleural non-fibrotic ILAs with extensive reticulation are likely to be a feature of subpleural fibrotic ILAs.

Word count abstract: 247

Key words: health check-up population; interstitial lung abnormalities; reticulation; radiological progression.

INTRODUCTION

Interstitial lung abnormalities (ILAs) are defined as incidental findings of lung parenchymal abnormalities by chest computed tomography (CT): they probably represent the early morphologic changes of interstitial lung diseases (ILD) (1-4). Following the widespread use of low-dose CT screening for lung cancer and other health purposes (5, 6), an increasing number of individuals with ILAs are identified in clinical practice (1, 7). The existing data on the prevalence of ILAs were derived from heart disease cohorts (8), age-based cohorts (9, 10), cigarette smokers cohorts (11), and lung cancer cohorts (12). The prevalence of ILAs in health check-up population, especially for non-Europeans, or for broad age band population, has not been reported.

Multiple CT imaging features define ILAs, including ground-glass opacities (GGO), reticulation, non-emphysematous cysts, traction bronchiectasis, and honeycombing (1). Previous studies have shown that some imaging patterns, described as imaging features and their distributions, are associated with risk of ILAs progression. For example, lower lobe predominance, subpleural location of some imaging features, and the presence of specific imaging features (eg. traction bronchiectasis and honeycombing) have been associated with significantly increased risk of ILAs progression and mortality (10, 13, 14). Based on this evidence, architectural distortion with traction bronchiectasis or honeycombing (or both) is currently defined as a distinguishing feature of lung fibrosis, and ILAs are stratified into three subcategories to support adequate management: non-subpleural, subpleural non-fibrotic and subpleural fibrotic (1).

Reticulation is usually regarded as a subtle feature of fibrotic ILD, and a risk factor of ILD progression in previously published clinical practice guideline (15-17). However, among the current classification criteria of ILAs, only traction bronchiectasis and honeycombing (or both)

are listed as imaging features of fibrosis, but reticulation isn't (1). Evidence showed that reticulation without visible traction bronchiectasis and honeycombing on CT was proven to be fibrosis in histopathology (2, 18). Whether reticulation, independent from the presence of traction bronchiectasis or honeycombing, is a risk factor associated with subpleural non-fibrotic ILAs progression, is still unclear. In the present study, we explored the age band prevalence of ILAs in a large health check-up population in China according to the ILAs classification by the Fleischner Society, and tested the hypothesis that reticulation without traction bronchiectasis and honeycombing is an independent risk factor of radiological progression in subpleural non-fibrotic ILAs. Some of the results of this study have been previously reported in the form of a meeting poster (19).

METHODS

Study design

The study was conducted at West China Hospital of Sichuan University (approval number 2019-246), and consisted of two parts. Part one had a retrospective cross-sectional design, in which the prevalence of ILAs was determined. Part two was a retrospective cohort study, in which average 4-year follow-up chest CT images (4 consecutive CTs, median time between CT scans 1.1 years) from individuals with ILAs at initial chest CT were evaluated to assess radiological progression.

Subjects

The study population included adults who chose to get low-dose chest CT scan after informed consent during their health checkups at West China Hospital between 2013 and 2019 (6). The general demography, smoking history, comorbidities, medical history, family history were extracted from electronic medical records. Individuals with interstitial lung changes were

selected by key words in their chest CT reports, including interstitial change, ground-glass opacities, reticulation, subpleural curvilinear line, honeycombing, traction bronchiectasis, nodule, emphysema, fibrosis, covering all abnormalities included in current ILAs definition. Individuals with a previous diagnosis of ILD or pre-clinical ILD (defined as abnormalities identified in individuals with high risk factors of ILD, including connective tissue disease or familial ILD) were excluded, according to the Fleischner Society position paper (1, 20-22).

Chest CT reporting

CT images were captured by a dual-slice CT scanner (Somatom Emotion Duo, Siemens, Germany) using a low-dose regimen (tube voltage 120 kVp and tube current 20~50 mA) in supine position. Images were reconstructed with contiguous 5-mm sections, and reviewed independently by two radiologists on picture archiving communication systems workstations: one junior radiologist with at least 5-year experience in thoracic radiology and one senior radiologist with at least 10-year experience. Before CT report releasing, agreement was reached.

ILAs features, subcategories, and distribution patterns

All CT images from selected individuals were validated by 8 well-trained readers with at least 4 years experience in ILD. Each CT image was independently evaluated by 2 of them, blinded to medical information and previous radiological report. Interobserver reliability was calculated. Consensus was reached for cases with discordant reports. The ILAs imaging features, subcategories, and distribution patterns were evaluated based on the Glossary of Terms for Thoracic Imaging and the position paper from the Fleischner Society (1, 23) (Table 1).

ILAs radiological progression

Individuals with 4 follow-up CT scans (average 4 years) were defined as progressors or non-progressors. Radiological progression was pre-defined as development of any new ILAs imaging feature, and/or increase of extent or density of the existing abnormalities on visual read. The detailed methodology used is provided (supplementary Methods).

Statistical methods

Statistical analysis was performed using SPSS (version 24.0, IBM SPSS, Chicago, IL). To compare the differences between groups, analysis was conducted using Chi-squared test or Fisher exact test for categorical variables, and Student's t or one-way ANOVA for continuous variables. Trend of prevalence was tested by Mantel-Haenszel χ^2 test. Odds ratio (OR) was calculated using multivariable logistic regression model. Interobserver agreement was assessed with kappa analysis. Significance of P values was set to 0.05. Bonferroni correction was used to adjust for multiple comparisons.

RESULTS

Prevalence of ILAs

The flowchart of the study is shown in Figure 1. In part one of the study, 155,539 individuals who performed low-dose chest CT scans during routine health check-up were screened: mean age was 46.1 ± 14.0 years, 60.7% were male, 32.3% had a smoking history, 27.2% had comorbidities (Table E1). 4,292 CT reports containing key terms suggesting the potential presence of ILAs were selected. Each CT image was then independently re-evaluated by 2 well-trained readers. Interobserver agreement for the presence of ILAs, the presence of fibrosis, and the presence of individual imaging features are shown in Table E2. After re-evaluation, 3,300 (76.9%) CT exams were confirmed as having ILAs features. Based on these findings,

the estimated prevalence of ILAs in this population was 2.1%. Age band analyses demonstrated that the prevalence of ILAs increased linearly with age (P for trend <0.0001, Table 2): each additional 10 years of age increased the odds of ILAs more than fourfold (OR 4.1, 95%CI 4.0-4.2, P<0.0001). Compared with individuals with normal chest CT, individuals with ILAs were significantly older (62.1±13.8 years vs. 39.4±11.0 years, P<0.0001), male predominant (72.3% vs. 55.5%, P<0.0001), and more likely to have a smoking history (41.2% vs. 26.9%, P<0.0001). Consistent with previous findings, gastroesophageal reflux disease (0.2% vs. 0.0%, P=0.0009) and diabetes (12.5% vs. 2.0%, P<0.0001) were over-represented among individuals with ILAs (Table E3).

Among the 3,300 scans with confirmed ILAs, 477 (14.5%) were defined as non-subpleural, 2,697 (81.7%) as subpleural non-fibrotic, and 126 (3.8%) as subpleural fibrotic. Age banded analyses demonstrated that prevalence increased linearly with age in all ILAs subgroups (P for trend <0.0001, Table 2). Individuals with subpleural fibrotic ILAs were significantly older (69.9±11.9 years), compared with individuals with subpleural non-fibrotic ILAs (61.5±13.7 years, P<0.0001) and individuals with non-subpleural ILAs (63.8±13.9 years, P<0.0001). Individuals with subpleural fibrotic ILAs (17.8%) were more often former smokers, compared with individuals with subpleural non-fibrotic ILAs (7.8%, P=0.0003) and individuals with non-subpleural ILAs (7.3%, P=0.0007) (Table 2).

Radiological characteristics of ILAs

Among the 3,300 scans with confirmed ILAs, ground-glass opacities (GGO) were the commonest imaging feature (N=3,202, 97.0%), followed by reticulation (N=1,392, 42.2%) (Table 2). GGO were equally distributed across all subgroups of ILAs (P=0.2286). The proportions of reticulation in non-subpleural ILAs (22.4%), subpleural non-fibrotic ILAs (44.1%), and subpleural fibrotic ILAs (76.2%) were significantly different (P<0.0001) and

linearly increased (P for trend <0.0001, Table 2). The average lung involvement degree in subpleural fibrotic ILAs (4.3 ± 1.6) was significantly higher than that in subpleural non-fibrotic ILAs (3.6 ± 1.5 , $P < 0.0001$) (Table 2).

Risk of radiological progression in ILAs

In part two of the study, all individuals with ILAs and 4 follow-up CT scans available (median follow-up period 4.2 years, interquartile range [IQR] 4.0-5.7 years; median time between CT scans 1.1 years, IQR 1.0-1.4 years) were included (Figure 1). These individuals were older and had more comorbidities, compared with those with fewer than 4 follow-up CT scans (Table E4). Among the 536 individuals with follow-up CT, 66 (12.3%) had non-subpleural ILAs and 25 (37.9%) progressed radiologically; 454 (84.7%) had subpleural non-fibrotic ILAs and 198 (43.6%) progressed radiologically; 16 (3.0%) had subpleural fibrotic ILAs and 11 (68.8%) progressed radiologically (Figure 1).

Among progressive subpleural non-fibrotic ILAs, 3 (1.5%) individuals had newly identified GGO, 51 (25.8%) individuals had newly identified reticulation. Two individuals progressed into fibrotic ILAs (1 had newly identified honeycombing and 1 had newly identified traction bronchiectasis), 1 progressed into typical UIP and 7 into an indeterminate UIP pattern (Table E5). The remaining 256 non-progressive subpleural non-fibrotic ILAs were either stable (N=164, 36.1%) or radiological regression (N=92, 20.3%). Individuals with progressive subpleural non-fibrotic ILAs were significantly older (67.7 ± 12.0 vs. 61.7 ± 12.7 , $P < 0.0001$), more likely to be former smokers (12.9% vs. 4.9%, $P = 0.0102$), and had a significantly higher lung involvement degree (3.9 ± 1.4 vs. 3.5 ± 1.5 , $P = 0.0016$), compared with those without progressive imaging (Table 3).

Furthermore, we evaluated radiological progression for each of the subpleural non-fibrotic ILAs features. Among the 454 individuals with subpleural non-fibrotic ILAs, 182 (40.1%) had

reticulation. The radiological progression proportion of subpleural non-fibrotic ILAs with reticulation was 35.2% within the follow-up period. After adjustment for covariates (age, gender, smoking status, ground-glass opacities, and comorbidities), the presence of reticulation significantly increased the risk of progression (OR 1.9; 95%CI 1.2-3.0, P=0.0040), suggesting that reticulation is an independent determinant of radiological progression in subpleural non-fibrotic ILAs.

Distribution patterns of reticulation on the risk of radiological progression

Subpleural non-fibrotic ILAs were further split into 3 subgroups (without reticulation, with limited reticulation, with extensive reticulation). Compared with non-subpleural ILAs, radiological progression risk increased linearly in these three groups and subpleural fibrotic ILAs (Table 4, P for trend < 0.0001). Significantly increased risk of radiological progression was identified in subpleural non-fibrotic ILAs with extensive reticulation (OR 4.4; 95% CI 2.0-9.6, P=0.0002) and subpleural fibrotic ILAs (OR 3.9; 95% CI 1.0-14.5, P=0.0460) after adjusting for covariates (age, gender, smoking status, ground-glass opacities, and comorbidities); however, no differences in radiological progression were identified between subpleural non-fibrotic ILAs with extensive reticulation (73.0%) and subpleural fibrotic (68.8%, P=0.7626).

We then subcategorized subpleural non-fibrotic ILAs into three additional subgroups: without reticulation, with reticulation in the upper-middle lung zones, with reticulation in the lower lung zones. Compared with non-subpleural ILAs, radiological progression risk increased linearly across these groups (Table 4, P for trend <0.0001). A significantly increased risk of radiological progression was identified for subpleural non-fibrotic ILAs with reticulation in lower lung zones (OR 2.3; 95% CI 1.2-4.5, P=0.0127) and subpleural fibrotic ILAs (OR 3.9; 95% CI 1.0-14.8, P=0.0428), after adjusting for covariates (age, gender, smoking status,

ground-glass opacities, and comorbidities). No differences in radiological progression were identified between subpleural non-fibrotic ILAs with reticulation in lower lung zones (59.5%) and subpleural fibrotic ILAs (68.8%, $P=0.4706$).

DISCUSSION

As a consequence of increasing air pollution, smoking, secondhand smoke exposure, and the increased incidence of lung cancer in younger individuals even in the absence of clear cancer risk factors (6), more and more community-dwelling people in China undergo low-dose chest CT scans during their health check-up: as such, a growing number of ILAs are identified. This study represents the first assessment of ILAs in a large Chinese health check-up population, based on the recent criteria identified by the Fleischner Society (1). We report age band prevalence of ILAs, and provide evidence supporting the concept that subpleural non-fibrotic ILAs with extensive reticulation are more likely to be features of lung fibrosis.

We assessed the prevalence of ILAs in a population with a very broad age range (from below 40 to above 70 years). The overall prevalence of ILAs in this study population is about 2%, with 3.8% subpleural fibrotic ILAs, substantially lower than that reported (4% to 17% for ILAs prevalence, 34% for fibrotic ILAs proportion) in previous studies (8, 10-12, 24-26). Potential explanations for these phenomena might include: 1) this study population is much younger (average age 46 years) including a large number of individuals under 50 years of age, and relatively healthier (73% individuals without comorbidities); 2) we assessed the presence of ILAs based on the recent radiological criteria by the Fleischner Society (1), in which some imaging features have been excluded (e.g., centrilobular nodularity, pleuropulmonary fibroelastosis); 3) the population included in our study represents a health checkup population, in which subpleural fibrotic ILAs might be underrepresented: individuals with high risk of lung fibrosis will be more frequently identified in pulmonary departments, and not in the context of

health check-up. In this study, the age band mapping of ILAs prevalence shows how the prevalence of ILAs increases linearly with age (from 0.2% in age band <40 years to 9.6% in age band >70 years). These findings not only provide evidence to support the known concept that age is an important risk factor for ILAs (1, 27, 28), but also provide insights on the evolution of ILAs over time.

In the position paper by the Fleischner Society, reticulation is not listed as an imaging feature of fibrosis (1). Importantly, we showed that about half of subpleural non-fibrotic ILAs progress radiologically over a period of 4 years. These findings indicated for the first time that reticulation, independently from the presence of traction bronchiectasis or honeycombing, significantly increases the risk of radiological progression of ILAs over time. In addition, we provided statistical evidence indicating that subpleural non-fibrotic ILAs with extensive reticulation or with reticulation in lower lobes, have a risk of progression similar to subpleural fibrotic ILAs. These results indicated that rigorously designed longitudinal cohort studies to study ILAs progression over time are needed.

This study has some limitations. Firstly, this is a retrospective study: as such, data have been extracted from electronic medical records. Clinical or biological potential risk factors were therefore generally not available and pathogenetic studies were not feasible. Potential inaccuracies associated with the nature of data collected through hospital records are unavoidable. Secondly, the study population is composed by Chinese individuals with a very broad age range: extrapolations of these findings to different populations need to be done very carefully. Thirdly, some potential selection biases exist. For example, most individuals involved in this study were living in a metropolitan area: as such, they might have been more concerned about their health status or more eager to undergo radiological examinations. In addition, only a minority (about 16%) of individuals with ILAs underwent the full 4 years

follow-up: these persons were older and had more comorbidities, compared with those without a complete follow-up. In order to minimize the interference of these confounders, we modified the covariates in the multiple regression model. Fourthly, given that ILAs and interstitial changes are significantly under-recognized and under-reported by radiologists on clinical CT scans (29), though all the 155,539 CT scans in our study were assessed by at least two radiologists experienced in thoracic radiology for at least 5 years, the use of a key word search of CT reports might have underestimated the real prevalence of ILAs. Fifthly, although the reliability of using low-dose CT to detect ILD features has been validated (30) and this technique has been used to evaluate ILAs in other cohorts (12, 31, 32), low-dose CT protocols might limit the ability to identify imaging features accurately (e.g., distinguishing between fine reticulation and GGO, or identify traction bronchiectasis in those ILAs with apparently isolated reticulation) (33). In addition, the individuals included in this study were undergoing low-dose CT scan with a supine position only, and gravity-dependent atelectasis couldn't be ruled out (3).

In conclusion, we tested the reproducibility of radiological criteria of ILAs as proposed by the Fleischner Society in a large Chinese population with a very broad age range. Our findings provided evidence to identify key uncertainties in understanding ILAs classification, including the prevalence in younger cohorts and the natural history of non-fibrotic ILAs. Finally, these results highlighted the need for rigorously designed longitudinal cohort studies on ILAs classification, in order to inform more accurate clinical management strategies. Recent studies showed that cell senescence plays a central role in age-related diseases, and biomolecules, functioning in cellular senescence, have been reported to be associated with pathogenesis of ILD (34, 35). Considering that aging increases the risk of ILAs/ILD progression, whether those biomolecules could be further used to assess disease progression will be also worth to be explored in the future.

ACKNOWLEDGEMENTS

The authors thank Deying Kang, Xin Sun for advising on the study design, and Jiayuan Li, Xuan Zhang for advising on the statistical analysis.

REFERENCES

1. Hatabu H, Hunninghake GM, Richeldi L, Brown KK, Wells AU, Remy-Jardin M, Verschakelen J, Nicholson AG, Beasley MB, Christiani DC, San José Estépar R, Seo JB, Johkoh T, Sverzellati N, Ryerson CJ, Graham Barr R, Goo JM, Austin JHM, Powell CA, Lee KS, Inoue Y, Lynch DA. Interstitial lung abnormalities detected incidentally on CT: a Position Paper from the Fleischner Society. *Lancet Respir Med* 2020; 8: 726-737.
2. Miller ER, Putman RK, Vivero M, Hung Y, Araki T, Nishino M, Washko GR, Rosas IO, Hatabu H, Sholl LM, Hunninghake GM. Histopathology of Interstitial Lung Abnormalities in the Context of Lung Nodule Resections. *Am J Respir Crit Care Med* 2018; 197: 955-958.
3. Antoniou KM, Tzilas V, Vasarmidi E, Symvoulakis EK, Tzouvelekis A, Bouros D. Interstitial lung abnormalities: ignotum per ignotius. *Lancet Respir Med* 2019; 7: 376-378.
4. Walsh SLF, Richeldi L. Subclinical Interstitial Lung Abnormalities: Lumping and Splitting Revisited. *Am J Respir Crit Care Med* 2019; 200: 121-123.
5. Bai C, Choi CM, Chu CM, Anantham D, Chung-Man Ho J, Khan AZ, Lee JM, Li SY, Saenghirunvattana S, Yim A. Evaluation of Pulmonary Nodules: Clinical Practice Consensus Guidelines for Asia. *Chest* 2016; 150: 877-893.

6. Ji G, Bao T, Li Z, Tang H, Liu D, Yang P, Li W, Huang Y. Current lung cancer screening guidelines may miss high-risk population: a real-world study. *BMC Cancer* 2021; 21: 50.
7. Hatabu H, Hunninghake GM, Lynch DA. Interstitial Lung Abnormality: Recognition and Perspectives. *Radiology* 2019; 291: 1-3.
8. Araki T, Putman RK, Hatabu H, Gao W, Dupuis J, Latourelle JC, Nishino M, Zazueta OE, Kurugol S, Ross JC, San José Estépar R, Schwartz DA, Rosas IO, Washko GR, O'Connor GT, Hunninghake GM. Development and Progression of Interstitial Lung Abnormalities in the Framingham Heart Study. *Am J Respir Crit Care Med* 2016; 194: 1514-1522.
9. Putman RK, Hatabu H, Araki T, Gudmundsson G, Gao W, Nishino M, Okajima Y, Dupuis J, Latourelle JC, Cho MH, El-Chemaly S, Coxson HO, Celli BR, Fernandez IE, Zazueta OE, Ross JC, Harmouche R, Estépar RS, Diaz AA, Sigurdsson S, Gudmundsson EF, Eiríksdóttir G, Aspelund T, Budoff MJ, Kinney GL, Hokanson JE, Williams MC, Murchison JT, MacNee W, Hoffmann U, O'Donnell CJ, Launer LJ, Harris TB, Gudnason V, Silverman EK, O'Connor GT, Washko GR, Rosas IO, Hunninghake GM. Association Between Interstitial Lung Abnormalities and All-Cause Mortality. *Jama* 2016; 315: 672-681.
10. Putman RK, Gudmundsson G, Axelsson GT, Hida T, Honda O, Araki T, Yanagawa M, Nishino M, Miller ER, Eiríksdóttir G, Gudmundsson EF, Tomiyama N, Honda H,

Rosas IO, Washko GR, Cho MH, Schwartz DA, Gudnason V, Hatabu H, Hunninghake GM. Imaging Patterns Are Associated with Interstitial Lung Abnormality Progression and Mortality. *Am J Respir Crit Care Med* 2019; 200: 175-183.

11. Ash SY, Harmouche R, Putman RK, Ross JC, Diaz AA, Hunninghake GM, Onieva J, Martinez FJ, Choi AM, Lynch DA, Hatabu H, Rosas IO, San Jose Estepar R, Washko GR. Clinical and Genetic Associations of Objectively Identified Interstitial Changes in Smokers. *Chest* 2017; 152: 780-791.
12. Sverzellati N, Guerci L, Randi G, Calabrò E, La Vecchia C, Marchianò A, Pesci A, Zompatori M, Pastorino U. Interstitial lung diseases in a lung cancer screening trial. *Eur Respir J* 2011; 38: 392-400.
13. Hida T, Nishino M, Hino T, Lu J, Putman RK, Gudmundsson EF, Araki T, Valtchinov VI, Honda O, Yanagawa M, Yamada Y, Hata A, Jinzaki M, Tomiyama N, Honda H, Estepar RSJ, Washko GR, Johkoh T, Christiani DC, Lynch DA, Gudnason V, Gudmundsson G, Hunninghake GM, Hatabu H. Traction Bronchiectasis/Bronchiolectasis is Associated with Interstitial Lung Abnormality Mortality. *Eur J Radiol* 2020; 129: 109073.
14. Salisbury ML, Hewlett JC, Ding G, Markin CR, Douglas K, Mason W, Guttentag A, Phillips JA, 3rd, Cogan JD, Reiss S, Mitchell DB, Wu P, Young LR, Lancaster LH, Loyd JE, Humphries SM, Lynch DA, Kropski JA, Blackwell TS. Development and

Progression of Radiologic Abnormalities in Individuals at Risk for Familial Interstitial Lung Disease. *Am J Respir Crit Care Med* 2020; 201: 1230-1239.

15. Raghu G, Remy-Jardin M, Myers JL, Richeldi L, Ryerson CJ, Lederer DJ, Behr J, Cottin V, Danoff SK, Morell F, Flaherty KR, Wells A, Martinez FJ, Azuma A, Bice TJ, Bouros D, Brown KK, Collard HR, Duggal A, Galvin L, Inoue Y, Jenkins RG, Johkoh T, Kazerooni EA, Kitaichi M, Knight SL, Mansour G, Nicholson AG, Pipavath SNJ, Buendía-Roldán I, Selman M, Travis WD, Walsh S, Wilson KC. Diagnosis of Idiopathic Pulmonary Fibrosis. An Official ATS/ERS/JRS/ALAT Clinical Practice Guideline. *Am J Respir Crit Care Med* 2018; 198: e44-e68.
16. He SH, He YJ, Guo KJ, Liang X, Li SS, Li TF. Risk factors for progression of interstitial lung disease in Sjögren's syndrome: a single-centered, retrospective study. *Clin Rheumatol* 2021.
17. Jacob J, Hansell DM. HRCT of fibrosing lung disease. *Respirology* 2015; 20: 859-872.
18. Travis WD, Costabel U, Hansell DM, King TE, Jr., Lynch DA, Nicholson AG, Ryerson CJ, Ryu JH, Selman M, Wells AU, Behr J, Bouros D, Brown KK, Colby TV, Collard HR, Cordeiro CR, Cottin V, Crestani B, Drent M, Dudden RF, Egan J, Flaherty K, Hogaboam C, Inoue Y, Johkoh T, Kim DS, Kitaichi M, Loyd J, Martinez FJ, Myers J, Protzko S, Raghu G, Richeldi L, Sverzellati N, Swigris J, Valeyre D. An official American Thoracic Society/European Respiratory Society statement: Update of the

international multidisciplinary classification of the idiopathic interstitial pneumonias.

Am J Respir Crit Care Med 2013; 188: 733-748.

19. Zhang. Y, Zhu. M, Huang. Y, Xiong. X, Liao. J, Zhu. W, Mao. L, Xu. L, Ye. D, Chen. L, Liu. J, Fu. L, Li. L, Lan. L, Li. P, Wang. L, Tang. X, Wan. H, Richeldi. L, Luo. F. Non-fibrotic Interstitial Lung Abnormalities Subtypes Increased the Odds of Fibrotic Interstitial Lung Abnormalities [poster]. Annual Congress of Chinese Thoracic Society 2021; PO-0119.
20. Buendía-Roldón I, Fernandez R, Mejía M, Juárez F, Ramirez-Martinez G, Montes E, Pruneda AKS, Martinez-Espinosa K, Alarcon-Dionet A, Herrera I, Becerril C, Chavez-Galan L, Preciado M, Pardo A, Selman M. Risk factors associated with the development of interstitial lung abnormalities. *Eur Respir J* 2021;8(2):2003005.
21. Arnett FC, Edworthy SM, Bloch DA, McShane DJ, Fries JF, Cooper NS, Healey LA, Kaplan SR, Liang MH, Luthra HS, et al. The American Rheumatism Association 1987 revised criteria for the classification of rheumatoid arthritis. *Arthritis Rheum* 1988; 31: 315-324.
22. Bradley B, Branley HM, Egan JJ, Greaves MS, Hansell DM, Harrison NK, Hirani N, Hubbard R, Lake F, Millar AB, Wallace WA, Wells AU, Whyte MK, Wilsher ML. Interstitial lung disease guideline: the British Thoracic Society in collaboration with the Thoracic Society of Australia and New Zealand and the Irish Thoracic Society. *Thorax* 2008; 63 Suppl 5: v1-58.

23. Hansell DM, Bankier AA, MacMahon H, McLoud TC, Müller NL, Remy J. Fleischner Society: glossary of terms for thoracic imaging. *Radiology* 2008; 246: 697-722.
24. Lederer DJ, Enright PL, Kawut SM, Hoffman EA, Hunninghake G, van Beek EJ, Austin JH, Jiang R, Lovasi GS, Barr RG. Cigarette smoking is associated with subclinical parenchymal lung disease: the Multi-Ethnic Study of Atherosclerosis (MESA)-lung study. *Am J Respir Crit Care Med* 2009; 180: 407-414.
25. Pompe E, de Jong PA, Lynch DA, Lessmann N, Išgum I, van Ginneken B, Lammers JJ, Mohamed Hoesein FAA. Computed tomographic findings in subjects who died from respiratory disease in the National Lung Screening Trial. *Eur Respir J* 2017; 49.
26. Tsushima K, Sone S, Yoshikawa S, Yokoyama T, Suzuki T, Kubo K. The radiological patterns of interstitial change at an early phase: over a 4-year follow-up. *Respir Med* 2010; 104: 1712-1721.
27. Sanders JL, Putman RK, Dupuis J, Xu H, Murabito JM, Araki T, Nishino M, Benjamin EJ, Levy DL, Vasan RS, Washko GR, Curtis JL, Freeman CM, Bowler R, Hatabu H, O'Connor GT, Hunninghake GM. The Association of Aging Biomarkers, Interstitial Lung Abnormalities, and Mortality. *Am J Respir Crit Care Med* 2020.
28. Copley SJ, Wells AU, Hawtin KE, Gibson DJ, Hodson JM, Jacques AE, Hansell DM. Lung morphology in the elderly: comparative CT study of subjects over 75 years old versus those under 55 years old. *Radiology* 2009; 251: 566-573.

29. Oldham JM, Adegunsoye A, Khera S, Lafond E, Noth I, Strek ME, Kadoch M, Chung JH. Underreporting of Interstitial Lung Abnormalities on Lung Cancer Screening Computed Tomography. *Ann Am Thorac Soc* 2018; 15: 764-766.
30. Ley S, Fidler L, Schenk H, Durand M, Marras T, Paul N, Shapera S, Mittoo S. Low dose computed tomography of the lung for detection and grading of interstitial lung disease: A systematic simulation study. *Pulmonology* 2021; 27: 14-25.
31. Salvatore M, Henschke CI, Yip R, Jacobi A, Eber C, Padilla M, Knoll A, Yankelevitz D. JOURNAL CLUB: Evidence of Interstitial Lung Disease on Low-Dose Chest CT Images: Prevalence, Patterns, and Progression. *AJR Am J Roentgenol* 2016; 206: 487-494.
32. Jin GY, Lynch D, Chawla A, Garg K, Tammemagi MC, Sahin H, Misumi S, Kwon KS. Interstitial lung abnormalities in a CT lung cancer screening population: prevalence and progression rate. *Radiology* 2013; 268: 563-571.
33. Christe A, Charimo-Torrente J, Roychoudhury K, Vock P, Roos JE. Accuracy of low-dose computed tomography (CT) for detecting and characterizing the most common CT-patterns of pulmonary disease. *Eur J Radiol* 2013; 82: e142-150.
34. DePianto DJ, Heiden JAV, Morshead KB, Sun KH, Modrusan Z, Teng G, Wolters PJ, Arron JR. Molecular mapping of interstitial lung disease reveals a phenotypically distinct senescent basal epithelial cell population. *JCI Insight* 2021; 6.

35. Stuart BD, Lee JS, Kozlitina J, Noth I, Devine MS, Glazer CS, Torres F, Kaza V, Girod CE, Jones KD, Elicker BM, Ma SF, Vij R, Collard HR, Wolters PJ, Garcia CK. Effect of telomere length on survival in patients with idiopathic pulmonary fibrosis: an observational cohort study with independent validation. *Lancet Respir Med* 2014; 2: 557-565.
36. Washko GR, Hunninghake GM, Fernandez IE, Nishino M, Okajima Y, Yamashiro T, Ross JC, Estépar RS, Lynch DA, Brehm JM, Andriole KP, Diaz AA, Khorasani R, D'Aco K, Sciurba FC, Silverman EK, Hatabu H, Rosas IO. Lung volumes and emphysema in smokers with interstitial lung abnormalities. *N Engl J Med* 2011; 364: 897-906.
37. Hoyer N, Wille MMW, Thomsen LH, Wilcke T, Dirksen A, Pedersen JH, Saghir Z, Ashraf H, Shaker SB. Interstitial lung abnormalities are associated with increased mortality in smokers. *Respir Med* 2018; 136: 77-82.
38. Kim JS, Podolanczuk AJ, Borker P, Kawut SM, Raghu G, Kaufman JD, Stukovsky KDH, Hoffman EA, Barr RG, Gottlieb DJ, Redline SS, Lederer DJ. Obstructive Sleep Apnea and Subclinical Interstitial Lung Disease in the Multi-Ethnic Study of Atherosclerosis (MESA). *Ann Am Thorac Soc* 2017; 14: 1786-1795.

Table 1. Definition, classification criteria and distribution pattern for features of ILAs, based on the position paper from the Fleischner Society

(1).

ILAs definition
<ul style="list-style-type: none">● Incidental identification of abnormalities, including ground-glass or reticular abnormalities, lung distortion, traction bronchiectasis, honeycombing, and non-emphysematous cysts.
<ul style="list-style-type: none">● Involving at least 5% of a lung zone (upper, middle, and lower lung zones are demarcated by the levels of the inferior aortic arch and right inferior pulmonary vein).
<ul style="list-style-type: none">● In individuals in whom interstitial lung disease is not suspected.
ILAs classification
<ul style="list-style-type: none">● Non-subpleural ILAs: ILAs without predominant subpleural localization.
<ul style="list-style-type: none">● Subpleural fibrotic ILAs: ILAs with a predominant subpleural localization and with evidence of pulmonary fibrosis (fibrosis is characterized by the presence of architectural distortion with traction bronchiectasis or honeycombing [or both]).
<ul style="list-style-type: none">● Subpleural non-fibrotic ILAs: ILAs without a predominant subpleural localization and without evidence of fibrosis.

Distribution
Lung zone: upper, middle, and lower lung zones are demarcated by the levels of the inferior aortic arch and right inferior pulmonary vein.
<ul style="list-style-type: none"> • Lower lung zone: the involvement of lower lung zone with or without middle or upper lung zone involvement.
<ul style="list-style-type: none"> • Middle-upper lung zone: the involvement of middle or upper lung zone (or both) without lower lung zone.
Involvement
<ul style="list-style-type: none"> • Involvement degree: scored based on the numbers of lung zones abnormalities presented, on a scale of 1 (one lung zone involvement) to 6 (all lung zones involvement).
<ul style="list-style-type: none"> • Limited: the involvement degree <3.
<ul style="list-style-type: none"> • Extensive: the involvement degree ≥ 3.

Table 2. Demographic and radiological characteristics of ILAs at baseline.

	Total ILAs	Non-subpleural ILAs	Subpleural non-fibrotic ILAs	Subpleural fibrotic ILAs	P value*
N (%)	3,300 (100.0)	477 (14.5)	2,697 (81.7)	126 (3.8)	
Age (years)	62.1±13.8	63.8±13.9	61.5±13.7 [†]	69.9±11.9 ^{†‡}	<0.0001
Prevalence in each age band					
<40	0.2% (0.2%-0.3%)	0.0% (0.0%-0.0%)	0.2% (0.1%-0.2%)	0.0% (0.0%-0.0%)	
40-49	1.2% (1.1%-1.3%)	0.2% (0.1%-0.2%)	1.0% (0.9%-1.1%)	0.0% (0.0%-0.0%)	
50-59	2.6% (2.4%-2.8%)	0.3% (0.2%-0.3%)	2.3% (2.1%-2.4%)	0.0% (0.0%-0.1%)	
60-69	5.5% (5.1%-5.9%)	0.9% (0.7%-1.1%)	4.3% (4.0%-4.7%)	0.2% (0.2%-0.3%)	
≥70	9.6% (9.0%-10.1%)	1.6% (1.3%-1.8%)	7.4% (6.9%-7.8%)	0.6% (0.5%-0.8%)	
P for trend	<0.0001	<0.0001	<0.0001	<0.0001	
Proportion in each age band					0.4161**

<40	113 (3.4)	13 (2.7)	97 (3.6)	3 (2.4)	
40-49	543 (16.5)	76 (15.9)	462 (17.1)	5 (4.0)	
50-59	855 (25.9)	95 (19.9)	747 (27.7)	13 (10.3)	
60-69	712 (21.6)	117 (24.6)	563 (20.9)	32 (25.4)	
≥70	1077 (32.6)	176 (36.9)	828 (30.7)	73 (57.9)	
Male gender	2,387 (72.3)	288 (60.4)	2001 (74.2) [†]	98 (77.8) [†]	<0.0001
Smoking status [§]					<0.0001
Never	1,894 (58.8)	321 (68.4)	1505 (57.2) [†]	68 (54.8) ^{†‡}	
Former	261(8.1)	34 (7.3)	205 (7.8)	22 (17.8)	
Current	1,068 (33.1)	114 (24.3)	920 (35.0)	34 (27.4)	
GGO	3,202 (97.0)	459 (96.2)	2623 (97.3)	120 (95.2)	0.2286
Reticulation	1,392 (42.2)	107 (22.4)	1189 (44.1) [†]	96 (76.2) ^{†‡}	<0.0001**
Non-emphysematous Cyst	24 (0.7)	7 (1.5)	13 (0.5)	4 (3.2) [‡]	0.0011 ^{††}

Traction bronchiectasis	120 (3.6)	42 (8.8)	0 (0.0)	78 (61.9)	N/A
Honeycombing	70 (2.1)	18 (3.8)	0 (0.0)	52 (41.3)	N/A
Lung involvement degree	3.7±1.5	4.1±1.6	3.6±1.5 [†]	4.3±1.6 [‡]	<0.0001
Comorbidities	1482 (48.5)	208 (47.8)	1206 (48.2)	68 (57.1)	0.1540
Lung cancer ^{‡‡}	3 (0.1)	1 (0.2)	1 (0.0)	1 (0.8)	0.1220
OSAS ^{‡‡}	1 (0.0)	0 (0.0)	1 (0.0)	0 (0.0)	N/A
GERD ^{‡‡}	7 (0.2)	2 (0.5)	5 (0.2)	0 (0.0)	N/A
DM ^{‡‡}	382 (12.5)	54 (12.4)	310 (12.4)	18 (15.1)	0.6758

Data presented as mean (± SD), prevalence (95% CI) for continues variables, N (%) for categorical variables.

GGO: ground-glass opacities; OSAS: obstructive sleep apnea syndrome; GERD: gastroesophageal reflux disease; DM: diabetes mellitus

*Comparison among non-subpleural ILAs, subpleural non-fibrotic ILAs, and subpleural fibrotic ILAs.

[†]Statistical significance was set to 0.0167 compared with non-subpleural ILAs after Bonferroni correction.

[‡]Statistical significance was set to 0.0167 compared with subpleural non-fibrotic ILAs after Bonferroni correction.

[§]77 individuals with missing data.

^{||}243 Individuals with missing data.

^{**}Mantel-Haenszel χ^2 test used

^{††}Fisher exact test used.

^{‡‡}Lung cancer, OSAS, GERD, and DM were shown in this table as they were reported to be associated with ILAs in previous studies (1, 20, 36-38).

Table 3. The association between demographic and radiological characteristics with radiological progression in subpleural non-fibrotic ILAs.

	Non-progressive n=256	Progressive n=198	P value	Unadjusted OR (95% CI)	P value	Adjusted OR (95% CI) [§]	P value
Age (years)	61.7±12.7	67.7±12.0	<0.0001	1.0 (1.0-1.1)	<0.0001	1.0 (1.0-1.1)	0.0002
Proportion of age			N/A				
<40	3 (1.2)	0 (0.0)					
40-49	43 (16.8)	12 (6.1)					
50-59	80 (31.2)	41 (20.7)					
60-69	54 (21.1)	49 (24.7)					
≥70	76 (29.7)	96 (48.5)					
Male	185(72.3)	149(75.3)	0.4742	1.2 (0.8-1.8)	0.4744	1.0 (0.6-1.7)	0.9479
Smoking status*			0.0102	1.0 (0.8-1.2)	0.9158	1.1 (0.9-1.5)	0.3581
Never	160 (64.8)	117 (60.3)					

Former	12 (4.9)	25 (12.9)					
Current	75 (30.3)	52 (26.8)					
GGO	251 (98.0)	193 (97.5)	0.7533‡	0.8 (0.2-2.7)	0.6812	1.7 (0.4-6.8)	0.4522
Reticulation	80 (31.3)	102 (51.5)	<0.0001	2.3 (1.6-3.4)	<0.0001	1.9 (1.2-3.0)	0.0040
Non- emphysematous Cysts	0 (0.0)	0 (0.0)	N/A	N/A	N/A	N/A	N/A
Lung involvement degree	3.5±1.5	3.9±1.4	0.0016	N/A	N/A	N/A	N/A
Comorbidities†	138 (60.5)	105 (62.9)	0.6357	1.1 (0.7-1.7)	0.6357	0.7 (0.5-1.2)	0.2107

Data presented as mean ± SD for continues variables, N (%) for categorical variables.

GGO: ground-glass opacities

*13 individuals with missing data.

†59 individuals with missing data.

‡Fisher exact test used.

§Adjusted for age, gender, smoking status, ground-glass opacities, and comorbidities.

Table 4. The association between distribution of reticulation with radiological progression in ILAs.

	Non-progression	Progression	P for trend	Unadjusted OR (95% CI)	P value[†]	Adjusted OR (95% CI)*	P value[†]
“Limited” vs. “Extensive” reticulation			<0.0001				
Non-subpleural ILAs (n=66)	41 (62.1)	25 (37.9)		1 [reference]		1 [reference]	
Subpleural non-fibrotic ILAs							
without reticulation (n=272)	176 (64.7)	96 (35.3)		0.9 (0.5-1.6)	0.6945	1.1 (0.6-2.1)	0.6706
with limited reticulation (n=108)	60 (55.6)	48 (44.4)		1.3 (0.7-2.5)	0.3949	1.3 (0.6-2.5)	0.5297
with extensive reticulation (n=74)	20 (27.0)	54 (73.0)		4.4 (2.2-9.0)	<0.0001	4.4 (2.0-9.6)	0.0002
Subpleural fibrotic ILAs (n=16)	5 (31.2)	11 (68.8)		3.6 (1.1-11.6)	0.0313	3.9 (1.0-14.5)	0.0460
“Middle-upper lung zone” vs. “Lower lung zone” reticulation			<0.0001				
Non-subpleural ILAs (n=66)	41 (62.1)	25 (37.9)		1 [reference]		1 [reference]	
Subpleural non-fibrotic ILAs							

without reticulation (n=272)	176 (64.7)	96 (35.3)	0.9 (0.5-1.6)	0.6945	1.1 (0.6-2.1)	0.7038
with middle-upper reticulation (n=29)	18 (62.1)	11 (37.9)	1.0 (0.4-2.5)	0.9961	1.1 (0.4-3.0)	0.7894
with lower reticulation (n=153)	62 (40.5)	91 (59.5)	2.4 (1.3-4.4)	0.0037	2.3 (1.2-4.5)	0.0127
Subpleural fibrotic ILAs (n=16)	5 (31.2)	11 (68.8)	3.6 (1.1-11.6)	0.0313	3.9 (1.0-14.8)	0.0428

Data presented as N (%) for categorical variables.

*Adjusted for age, gender, smoking status, ground-glass opacities, comorbidities.

†P values referred to comparisons of risk of radiological progression between each group with non-subpleural ILAs.

Figure 1. Study flowchart.

Figure legend: CT: computed tomography; ILAs: interstitial lung abnormalities; CTD: connective tissue disease; ILD: interstitial lung disease.

* Key words included interstitial change, ground-glass opacities, reticulation, subpleural curvilinear line, honeycombing, traction bronchiectasis, nodule, emphysema, fibrosis.

† Preclinical ILD is defined as abnormalities identified in individuals with high risk factors of ILD, including individuals with connective tissue disease or familial ILD, based on the Position Paper from Fleischner Society (1).

‡ CTD included rheumatoid arthritis (n=28), Sjogren's syndrome (n=7), systemic lupus erythematosus (n=5), systemic sclerosis (n=2), mCTD (n=2), unclassifiable CTD (n=1).

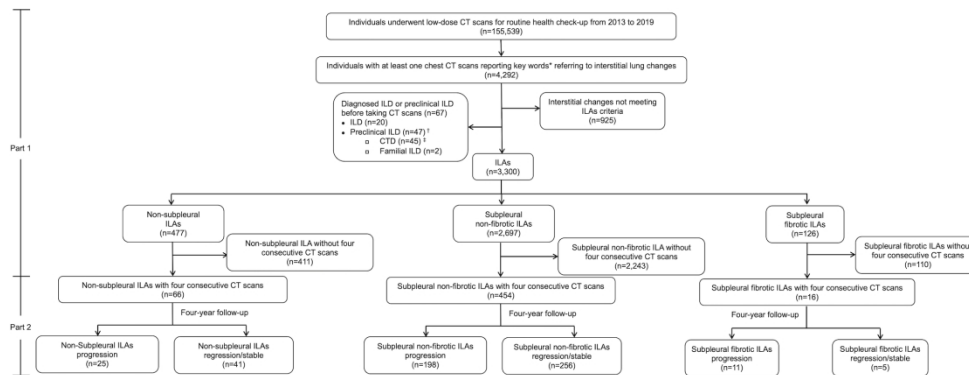


Figure legend: CT: computed tomography; ILAs: interstitial lung abnormalities; CTD: connective tissue disease; ILD: interstitial lung disease.

* Key words included interstitial change, ground-glass opacities, reticulation, subpleural curvilinear line, honeycombing, traction bronchiectasis, nodule, emphysema, fibrosis.

† Preclinical ILD is defined as abnormalities identified in individuals with high risk factors of ILD, including individuals with connective tissue disease or familial ILD, based on the Position Paper from Fleischner Society (1).

‡ CTD included rheumatoid arthritis (n=28), Sjogren's syndrome (n=7), systemic lupus erythematosus (n=5), systemic sclerosis (n=2), mCTD (n=2), unclassifiable CTD (n=1).

199x123mm (300 x 300 DPI)

Online Data Supplement

Reticulation is a Risk Factor of Progressive Subpleural non-Fibrotic Interstitial Lung

Abnormalities

Yuchen Zhang*, Huajing Wan Ph.D.*, Luca Richeldi M.D, Ph.D.*, Min Zhu*, Yan Huang*,
Xiaofeng Xiong, Junzhe Liao, Wenjun Zhu, Lingli Mao, Linrui Xu, Dongfan Ye, Ling Chen,
Jia Liu, Linxi Fu, Liangyuan Li, Lan Lan, Ping Li, Lixia Wang, Xiaoju Tang, Fengming Luo
M.D, Ph.D.†

*Equally contributed

†Corresponding author

Methods

ILAs radiological progression

We established an imaging scoring system to classify the outcome as progressive, stable and regressive, for which the three points classification was used, based on previous studies (E1-E4).

1. *Scoring*: 4 consecutive CT scans from each person were read visually and 4 follow-up comparison were performed: 1st vs baseline, 2nd vs 1st, 3rd vs 2nd, 4th vs 3rd. For each comparison, we scored the radiological progression as shown in the table below. The sum of all the numbers of the four comparisons provided a follow-up score for each individual.

	Progression or newly identified	No change	Regression
GGO	+1	0	-1
Non-emphysematous cysts	+1	0	-1
Reticulation	+2	0	-2
Traction bronchiectasis	+3	0	-3
Honeycombing	+3	0	-3

+: development of any new ILAs imaging feature, and/or increase of distribution or density of the existing abnormalities on visual read.

-: decreasing of distribution or density for the existing abnormalities on visual read.

0: No change of any of the existing features was marked as 0.

1-3: Based on previous studies (E1-E4), the severity of the imaging features was defined as “severe” (traction bronchiectasis and honeycombing), “moderate” (reticulation) and “mild” (GGO and non-emphysematous cysts), and scored as 3, 2, 1, respectively.

2. *Interpretation*: The radiological progression for each individual was interpreted based on the sum calculated in the previous step: positive score defined as progressive, zero defined as stable, and negative score defined as regressive.

3. The categories of subpleural non-fibrotic ILAs with radiological progression: progression into subpleural fibrotic ILAs and/or usual interstitial pneumonia (UIP) patterns (typical, probable, indeterminate), based on the current clinical practice guidelines for the diagnosis of idiopathic pulmonary fibrosis (IPF) (E5).

Table E1. Demographic and clinical characteristics of individuals undergoing health screening at baseline.

	Health screening population
	n=155,539
Age (years)	46.1 ± 14.0
Proportion of Age	
<40	52,478 (33.7)
40-49	45,796 (29.4)
50-59	33,027 (21.2)
60-69	12,975 (8.3)
≥70	11,263 (7.2)
Male gender	94,413 (60.7)
Smoking*	
Never	62,557 (67.7)
Former	3,803 (4.1)
Current	25,998 (28.2)
Comorbidities †	24,661 (27.2)
Lung cancer	8 (0.0)
OSAS	5 (0.0)
GERD	47 (0.1)
DM	4,035 (4.4)

OSAS: obstructive sleep apnea syndrome; GERD: gastroesophageal reflux disease; DM: diabetes mellitus.

*63,181 individuals with missing data.

†64,842 individuals with missing data.

Table E2. Kappa value of the presence of ILAs, the presence of fibrosis, and the presence of individual features.

	Kappa value
Presence of ILAs	0.95
Presence of fibrosis	0.73
Presence of Reticulation	0.89
Presence of Ground-glass opacities	0.94
Presence of Non-emphysematous cysts	0.62
Presence of Traction Bronchiectasis	0.66
Presence of Honeycombing	0.83

Kappa value is defined as “slight” ($k=0.00-0.20$), “fair” ($k=0.21-0.40$), “moderate” ($k=0.41-0.60$), “good” ($k=0.61-0.80$), or “excellent” ($k=0.81-1.00$) (E6).

Table E3. Demographic and clinical characteristics of individuals with ILAs and normal chest CT.

	ILAs n=3,300	Normal chest CT n=59,431	P value
Age (years)	62.1 ± 13.8	39.4 ± 11.0	<0.0001
Proportion of Age			<0.0001
<40	113 (3.4)	31274 (52.6)	
40-49	543 (16.5)	17156 (28.9)	
50-59	855 (25.9)	8484 (14.3)	
60-69	712 (21.6)	1895 (3.2)	
≥70	1,077 (32.6)	622 (1.0)	
Male gender	2,387 (72.3)	32,976 (55.5)	<0.0001
Smoking*			<0.0001
Never	1,894 (58.8)	19,604 (73.1)	
Former	261 (8.1)	633 (2.4)	
Current	1,068 (33.1)	6,590 (24.5)	
Comorbidities [†]	1,482 (48.5)	4,524 (17.0)	<0.0001
Lung cancer [§]	3 (0.1)	0 (0.0)	N/A
OSAS [§]	1 (0.0)	4 (0.0)	0.4195 [‡]
GERD [§]	7 (0.2)	10 (0.0)	0.0009 [‡]
DM [§]	382 (12.5)	538 (2.0)	<0.0001

OSAS: obstructive sleep apnea syndrome; GERD: gastroesophageal reflux disease; DM: diabetes mellitus.

*32,681 individuals with missing data.

†33,067 individuals with missing data.

‡Fisher exact test.

§Lung cancer, OSAS, GERD, and DM were shown in this table as they were reported to be associated with ILAs in previous studies (E1,E7,E8).

Table E4. Demographic and clinical characteristics of ILAs with and without follow-up.

	ILAs with follow-up n=536	ILAs without follow-up n=2,764	P value
Age (years)	64.6 ± 12.6	61.6 ± 13.9	<0.0001
Proportion of Age			<0.0001
<40	3 (0.5)	110 (4.0)	
40-49	62 (11.6)	481 (17.4)	
50-59	142 (26.5)	713 (25.8)	
60-69	121 (22.6)	591 (21.4)	
≥70	208 (38.8)	869 (31.4)	
Male gender	393 (73.3)	1,994 (72.1)	0.5765
Smoking*			0.0355
Never	328 (62.7)	1,566 (58.0)	
Former	47 (9.0)	214 (7.9)	
Current	148 (28.3)	920 (34.1)	
Comorbidities†	292 (62.7)	1,190 (45.9)	<0.0001
Lung cancer§	0 (0.0)	3 (0.1)	N/A
OSAS§	0 (0.0)	1 (0.0)	N/A
GERD§	2 (0.4)	5 (0.2)	0.2902‡
DM§	68 (14.6)	314 (12.1)	0.1371

OSAS: obstructive sleep apnea syndrome; GERD: gastroesophageal reflux disease; DM: diabetes mellitus

*77 individuals with missing data.

†243 individuals with missing data.

‡Fisher exact test.

§Lung cancer, OSAS, GERD, and DM were shown in this table as they were reported to be associated with ILAs in previous studies (E1,E7,E8).

Table E5. Individual radiological progression data for participants with subpleural non-fibrotic ILAs at baseline that progressed into subpleural fibrotic ILAs, typical UIP, probable UIP, or indeterminate UIP.

		Baseline CT	Consecutive follow-up chest CT scans			
		scan	1	2	3	4
Participant 1 50 y/o, female	GGO	Yes	No change	No change	No change	No change
	Reticulation	Yes	No change	No change	No change	Progression
	Non-emphysematous cysts	No	No	No	No	No
	Traction bronchiectasis	No	No	No	No	No
	Honeycombing	No	No	No	No	Newly identified
	UIP	No	No	No	No	Typical UIP
Participant 2 68 y/o, female	GGO	Yes	No change	No change	No change	No change
	Reticulation	Yes	No change	No change	No change	No change

	Non-emphysematous cysts	No	No	No	No	No
	Traction bronchiectasis	No	No	No	Newly identified	No change
	Honeycombing	No	No	No	No	No
	UIP	No	No	No	No	No
Participant 3 61 y/o, male	GGO	Yes	Progression	No change	Progression	Progression
	Reticulation	Yes	Progression	No change	Progression	Progression
	Non-emphysematous cysts	No	No	No	No	No
	Traction bronchiectasis	No	No	No	No	No
	Honeycombing	No	No	No	No	No
	UIP	No	No	Indeterminate	Indeterminate	Indeterminate
				UIP	UIP	UIP
Participant 4 55 y/o, male	GGO	Yes	Regression	No change	Progression	No change
	Reticulation	No	No	No	Newly identified	No change

	Non-emphysematous cysts	No	No	No	No	No
	Traction bronchiectasis	No	No	No	No	No
	Honeycombing	No	No	No	No	No
	UIP	No	No	No	Indeterminate	Indeterminate
					UIP	UIP
	GGO	Yes	No change	Progression	Progression	Regression
	Reticulation	Yes	No change	Progression	Progression	No change
Participant 5 62 y/o, male	Non-emphysematous cysts	No	No	No	No	No
	Traction bronchiectasis	No	No	No	No	No
	Honeycombing	No	No	No	No	No
	UIP	No	No	Indeterminate	Indeterminate	Indeterminate
					UIP	UIP
Participant 6	GGO	Yes	No change	No change	No change	Progression

78 y/o female	Reticulation	No	No	No	No	Newly identified
	Non-emphysematous cysts	No	No	No	No	No
	Traction bronchiectasis	No	No	No	No	No
	Honeycombing	No	No	No	No	No
	UIP	No	No	No	No	Indeterminate UIP
	GGO	Yes	No change	Progression	Progression	Regression
Participant 7	Reticulation	No	No	No	No	Newly identified
	62 y/o, female	Non-emphysematous cysts	No	No	No	No
	Traction bronchiectasis	No	No	No	No	No
	Honeycombing	No	No	No	No	No

	UIP	No	No	No	No	Indeterminate
						UIP
Participant 8 91 y/o, male	GGO	Yes	No change	Progression	No change	No change
	Reticulation	Yes	No change	Progression	No change	Progression
	Non-emphysematous cysts	No	No	No	No	No
	Traction bronchiectasis	No	No	No	No	No
	Honeycombing	No	No	No	No	No
	UIP	No	No	No	No	Indeterminate
						UIP
Participant 9 92 y/o, male	GGO	Yes	No change	No change	No change	No change
	Reticulation	Yes	No change	No change	No change	Progression
	Non-emphysematous cysts	No	No	No	No	No
	Traction bronchiectasis	No	No	No	No	No

Honeycombing	No	No	No	No	No
UIP	No	No	No	No	Indeterminate
					UIP

Table E6. Baseline demographic and radiological characteristics of subpleural fibrotic ILAs with and without radiological progression.

	Non-progressive	Progressive	P value
	n=5	n=11	
Age (years)	66.4±11.1	72.5±8.5	0.2465
Proportion of age			N/A
<40	0 (0.0)	0 (0.0)	
40-49	0 (0.0)	0 (0.0)	
50-59	2 (40.0)	1 (9.1)	
60-69	0 (0.0)	3 (27.3)	
≥70	3 (60.0)	7 (63.6)	
Male	4 (80.0)	7 (63.6)	1.000 [†]
Smoking status			N/A
Never	2 (40.0)	8 (72.7)	
Former	0 (0.0)	1 (9.1)	
Current	3 (60.0)	2 (18.2)	
GGO	5 (100.0)	10 (90.9)	N/A
Reticulation	3 (60.0)	9 (81.8)	0.5467 [†]
Non-emphysematous			
Cysts	0 (0.0)	0 (0.0)	N/A
Traction	4 (80.0)	8 (72.7)	1.000 [†]

Bronchiectasis			
Honeycombing	1 (20.0)	3 (27.3)	1.000†
Lung involvement degree	4.0±1.4	4.8±1.2	0.2425
Comorbidities*	4 (100.0)	7 (77.8)	N/A

Data presented as mean (\pm SD), prevalence (95%CI) for continues variables, N (%) for categorical variables.

GGO: ground-glass opacities.

*3 individuals with missing data.

†Fisher exact test used.

REFERENCES FOR SUPPLEMENTARY MATERIAL

- E1. Hatabu H, Hunninghake GM, Richeldi L, Brown KK, Wells AU, Remy-Jardin M, Verschakelen J, Nicholson AG, Beasley MB, Christiani DC, San José Estépar R, Seo JB, Johkoh T, Sverzellati N, Ryerson CJ, Graham Barr R, Goo JM, Austin JHM, Powell CA, Lee KS, Inoue Y, Lynch DA. Interstitial lung abnormalities detected incidentally on CT: a Position Paper from the Fleischner Society. *Lancet Respir Med* 2020; 8: 726-737.
- E2. Putman RK, Gudmundsson G, Axelsson GT, Hida T, Honda O, Araki T, Yanagawa M, Nishino M, Miller ER, Eiriksdottir G, Gudmundsson EF, Tomiyama N, Honda H, Rosas IO, Washko GR, Cho MH, Schwartz DA, Gudnason V, Hatabu H, Hunninghake GM. Imaging Patterns Are Associated with Interstitial Lung Abnormality Progression and Mortality. *Am J Respir Crit Care Med* 2019; 200: 175-183.
- E3. Salisbury ML, Hewlett JC, Ding G, Markin CR, Douglas K, Mason W, Guttentag A, Phillips JA, 3rd, Cogan JD, Reiss S, Mitchell DB, Wu P, Young LR, Lancaster LH, Loyd JE, Humphries SM, Lynch DA, Kropski JA, Blackwell TS. Development and Progression of Radiologic Abnormalities in Individuals at Risk for Familial Interstitial Lung Disease. *Am J Respir Crit Care Med* 2020; 201: 1230-1239.
- E4. Chae KJ, Jin GY, Goo JM, Chung MJ. Interstitial Lung Abnormalities: What Radiologists Should Know. *Korean J Radiol* 2021; 22: 454-463.
- E5. Raghu G, Remy-Jardin M, Myers JL, Richeldi L, Ryerson CJ, Lederer DJ, Behr J, Cottin V, Danoff SK, Morell F, Flaherty KR, Wells A, Martinez FJ, Azuma A, Bice TJ, Bouros D, Brown KK, Collard HR, Duggal A, Galvin L, Inoue Y, Jenkins RG, Johkoh T, Kazerooni EA, Kitaichi M, Knight SL, Mansour G, Nicholson AG, Pipavath SNJ, Buendía-Roldán I, Selman M, Travis WD, Walsh S, Wilson KC. Diagnosis of Idiopathic Pulmonary Fibrosis. An Official ATS/ERS/JRS/ALAT Clinical Practice Guideline. *Am J Respir Crit Care Med* 2018; 198: e44-e68.
- E6. Jin GY, Lynch D, Chawla A, Garg K, Tammemagi MC, Sahin H, Misumi S, Kwon KS. Interstitial lung abnormalities in a CT lung cancer screening population: prevalence and progression rate. *Radiology* 2013; 268: 563-571.

E7. Buendía-Roldán I, Fernandez R, Mejía M, Juarez F, Ramirez-Martinez G, Montes E, Pruneda AKS, Martinez-Espinosa K, Alarcon-Dionet A, Herrera I, Becerril C, Chavez-Galan L, Preciado M, Pardo A, Selman M. Risk factors associated with the development of interstitial lung abnormalities. *Eur Respir J* 2021.

E8. Kim JS, Podolanczuk AJ, Borker P, Kawut SM, Raghu G, Kaufman JD, Stukovsky KDH, Hoffman EA, Barr RG, Gottlieb DJ, Redline SS, Lederer DJ. Obstructive Sleep Apnea and Subclinical Interstitial Lung Disease in the Multi-Ethnic Study of Atherosclerosis (MESA). *Ann Am Thorac Soc* 2017; 14: 1786-1795.